

A new strategy in lung/lobe isolation in patients with a lung abscess or a previous lung resection using double lumen tubes combined with bronchial blockers

Manuel Granell Gil^{1,2}, Ruben Rubio-Haro¹, Javier Morales-Sarabia¹, Elena Biosca Perez¹, Giulia Petrini³, Ricardo Guijarro⁴, Jose De Andrés^{1,2}

Departments of ¹Anesthesia Critical Care and Pain Management and ⁴Thoracic Surgery, Valencia University General Hospital, Tres Creus Avenue, Valencia, ²Department of Surgery, Valencia University Medical School, Blasco Ibáñez Av, Valencia, Spain, ³Department of Anesthesia and Critical Care, Cardinal Massaia Hospital, Asti, Italy

ABSTRACT

The combined use of a double-lumen tube and a bronchial blocker can be very helpful in two different clinical scenarios: (1) in isolating not only the contralateral lung, but also the lobe/s of the same lung in which the infected lobe must be resected, (2) in preventing/treating hypoxemia because of the presence of a contralateral lobectomy. A cardiothoracic anesthesiologist must expertise this technique to avoid complications during surgery.

Keywords: Airway management, bronchial blocker, double-lumen tube

Address for correspondence: Dr. Ruben Rubio-Haro, Anesthesia, Critical Care and Multidisciplinary Pain Management Department, General University Hospital, Tres Creus Avenue, 2-46014, Valencia, Spain.

Submitted: 28-Jan-2021 **Revised:** 25-Jul-2021 **Accepted:** 08-Aug-2021 **Published:** 05-Jul-2022

CASE SERIES

In thoracic surgery, the requirement for one-lung ventilation (OLV) is common, which can be performed using different isolation devices, such as double-lumen tubes (DLT) or bronchial blockers (BB). OLV is a challenge for the anesthesiologist because a higher inspired pressure is required to create an equivalent tidal volume, and there is a greater potential for significant hypoxemia and barotrauma. This is even more difficult in patients with a previous contralateral lobectomy or bi-lobectomy, in which an OLV means a one-lobe ventilation (in case of left lung ventilation) or one or bi-lobe ventilation (in case of right lung ventilation). In these patients, a combined use of a DLT and a BB can avoid the almost unavoidable hypoxemia and it allows the surgery to be done.^[1-3] In these situations the selective lobar bronchial blockade is a technique that

allows one-lung ventilation while the operated lobe is collapsed in patients with previous pulmonary resection requiring subsequent resection or with limited pulmonary reserve. With the implementation of surveillance protocols following pulmonary resection for lung cancer, we might expect a greater detection rate for patients developing a second resectable primary lung tumor.^[4] It is also now not uncommon for patients to present for repeat thoracotomies for resection of certain types of metastatic tumors within the lungs. Therefore, in the future, it is likely that the number of patients presenting for a subsequent, often contralateral, pulmonary resection will increase.

This strategy can also be used to protect the other lobes from a significant bleeding or an infection, and not only the contralateral lung. In the setting of inflammatory lung

This is an open access journal, and articles are distributed under the terms of the Creative Commons Attribution-NonCommercial-ShareAlike 4.0 License, which allows others to remix, tweak, and build upon the work non-commercially, as long as appropriate credit is given and the new creations are licensed under the identical terms.

For reprints contact: WKHLRPMedknow_reprints@wolterskluwer.com

How to cite this article: Gil MV, Rubio-Haro R, Morales-Sarabia J, Perez EB, Petrini G, Guijarro R, *et al.* A new strategy in lung/lobe isolation in patients with a lung abscess or a previous lung resection using double lumen tubes combined with bronchial blockers. *Ann Card Anaesth* 2022;25:343-5.

Access this article online	
Quick Response Code:	Website: www.annals.in
	DOI: 10.4103/aca.ACA_16_21

disease with an infection, protection of the intact lobe from contamination is important.

In this case series, we present our experience with seven cases in which we applied this strategy of a combined use of a DLT and a BB. Figure 1 shows the first four cases, in which the aim of the strategy was to isolate, not only the contralateral lung, but also the lobe of the same lung in which the infected lobe was to be resected. Figure 2 shows images of a patient and view of the technique.

Figure 3 shows the last three cases, in which the aim of this strategy was to prevent/treat hypoxemia because of the presence of a contralateral lobectomy. After lung resection, a series of cardiopulmonary changes and adaptations are expected to occur in the remaining lung tissue.^[5] An increase in pulmonary arterial pressure (PAP) appears because of the resection itself, changes in the position of the heart and big vessels after pneumonectomy^[6] and pulmonary hypoxic vasoconstriction in chronic obstructive pulmonary disease patients with FEV1 <50%. This increase in PAP generates more overload and progressively change the morphology

of the right ventricle, producing its dysfunction. Another change is the loss of pulmonary tissue, which result in an even “more subatmospheric” pleural pressure (from appr. -6.5 cm H₂O preoperatively, to up to -10-12 cm H₂O), producing a change in the balance of pleural and pulmonary water and consequently an increased risk of pulmonary edema.^[7]

Some anatomic changes appear after lung resection, including expansion of the remaining lung to fill the thoracic cavity, upward displacement of the hemidiaphragm, and a lateral shift of the mediastinum.^[8] Changes in the bronchial angle are much greater after a left than right upper lobectomy, due to the much longer left main bronchus.^[9] A preoperative assessment of chest X-ray and CT scan must be mandatory in patients with a previous lung resection because most tracheobronchial distortions that cause problems during placement of endobronchial tubes or blockers can be seen on the preoperative imaging.

In conclusion, as presented in these seven clinical cases, the strategy of a combined use of a DLT and a BB can be very helpful in avoiding hypoxemia in patients with a contralateral lobectomy; it is also helpful in protecting the other lobe/s of the same lung from bleeding or infection. There is not much-published literature in this topic, so we believe that higher quality observational studies would be of interest to demonstrate the superiority and usefulness of this technique.

In our experience, the VivaSight DLT is very useful in managing these patients since we can constantly monitor the position of the BB and detect early possible dislocations, as well as reposition it quickly and in some cases without requiring a fiberscope. The use of extracorporeal membrane oxygenation (ECMO) has been described in thoracic surgery, mainly in lung resections in patients with contralateral pneumonectomy or in patients with severely lung impaired function.^[10] The use of ECMO in patients with contralateral lobectomy has not been described but can be a future alternative for patients in which one or two-lobe ventilation (even with CPAP in other lobe) is not enough to maintain an adequate oxygenation and ventilation and in which a surgery can significantly improve their cancer prognosis.

Financial support and sponsorship

Nil.

Conflicts of interest

There are no conflicts of interest.

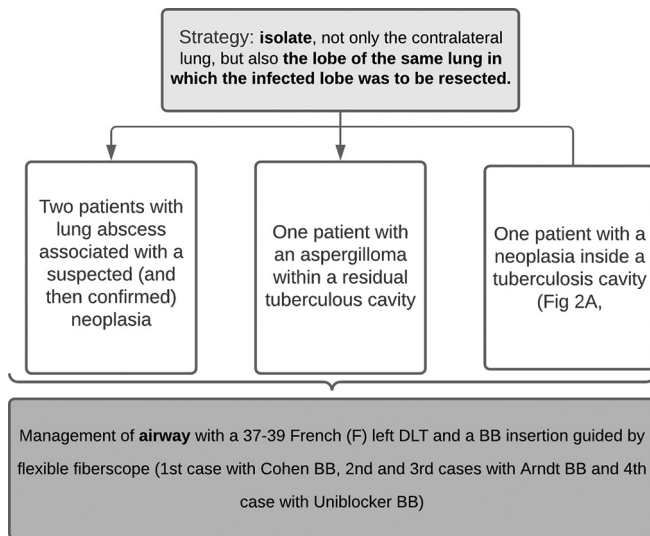


Figure 1: Flow chart shows the four cases in which we also isolate the lobe of the same lung in which the infected lobe was to be resected, with a combined use of a DLT and BB

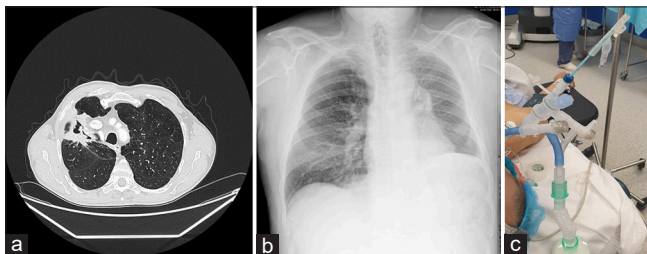


Figure 2: (a) Neoplasia inside a tuberculosis cavity in a CT. (b) X-ray of a patient with a left lower lobectomy. (c) View from a 37F left VivaSight© DLT of a bronchial blocker in the intermedium right bronchus

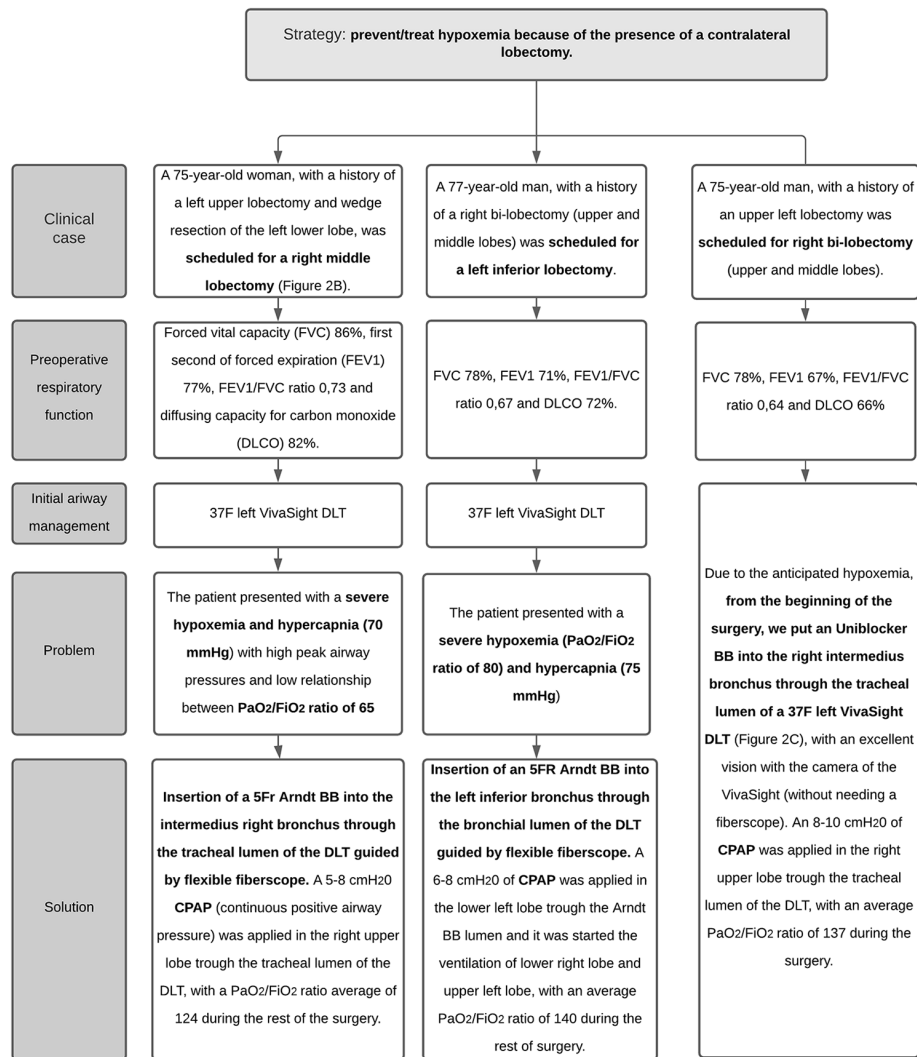


Figure 3: Flow chart shows three case in which we achieve an adequate oxygenation and ventilation, even with a presence of a contralateral lobectomy, with a combined use of a DLT and BB

REFERENCES

- McGlade DP, Slinger PD. The elective combined use of a double lumen tube and endobronchial blocker to provide selective lobar isolation for lung resection following contralateral lobectomy. *Anesthesiology* 2003;99:1021-2.
- Cruz P, Orozco HD, Garutti Martínez I, Hernández Fernández G. Selective lobar blockade with a Coopdech blocker combined with a double-lumen endotracheal tube for lung metastases resection by laser. *Rev Bras Anesthesiol* 2018;68:200-4.
- Sumitani M, Matsubara Y, Mashimo T, Takeda S. Selective lobar bronchial blockade using a double-lumen endotracheal tube and bronchial blocker. *Gen Thorac Cardiovasc Surg* 2007;55:225-7.
- Naunheim KS, Virgo KS. Postoperative surveillance following lung cancer resection. *Chest Surg Clin N Am* 2001;11:213-25.
- Granell M; Kawagoe I; Broseta A; Giner I; Sentürk M. Thoracic surgery in patients with a previous lung resection. In: Granell Gil M, Sentürk M, editors. *Anesthesia in Thoracic Anesthesia*. Changes of Paradigms. Switzerland: Springer; 2020. p. 313-25.
- Smulders SA, Holverda S, Vonk-Noordegraaf A, van den Bosch HC, Post JC, Marcus JT, et al. Cardiac function and position more than 5 years after pneumonectomy. *Ann Thorac Surg* 2007;83:1986-92.
- Salito C, Bovio D, Orsetti G, Salati M, Brunelli A, Aliverti A, et al. Effect of lung resection on pleuro-pulmonary mechanics and fluid balance. *Respir Physiol Neurobiol* 2016;221:35-40.
- Nonaka M, Kadokura M, Yamamoto S, Kataoka D, Iyano K, Kushihashi T, et al. Analysis of the anatomic changes in the thoracic cage after a lung resection using magnetic resonance imaging. *Surg Today* 2000;30:879-85.
- Seok Y, Cho S, Lee JY, Yang HC, Kim K, Jheon S. The effect of postoperative change in bronchial angle on postoperative pulmonary function after upper lobectomy in lung cancer patients. *Interact Cardiovasc Thorac Surg* 2014;18:183-8.
- Gillon SA, Toufektzian L, Harrison-Phipps K, Puchakayala M, Daly K, Ioannou N, et al. Perioperative extracorporeal membrane oxygenation to facilitate lung resection after contralateral pneumonectomy. *Ann Thorac Surg* 2016;101:e71-3.