

Prevalence of Marine-Lenhart syndrome on ^{99m}Tc-thyroid scintigraphy and response to radioiodine: A single institutional retrospective study

ABSTRACT

Marine-Lenhart Syndrome is a rare entity, described as Graves' disease with coexisting functioning thyroid nodules. It is often diagnosed on thyroid scintigraphy as a cold nodule with surrounding extranodular hyperactivity initially and postradioiodine ablation, they regain function on the follow-up thyroid scintigraphy due to endogenous thyroid-stimulating hormone (TSH) stimulation. We retrospectively reviewed all thyroid scintigraphy database performed between January 2018 and March 2020 in our institute. We searched patients with Graves' disease with the following criteria to suggest Marine-Lenhart Syndrome: (a) initial thyroid scintigraphy showing features of Graves' disease with coexistent poorly functioning nodules (b) There is normalization of uptake within the nodule on thyroid scan after radioiodine ablation suggestive of endogenous TSH stimulation (this also indirectly proves nodules are TSH dependent), (c) nodule(s) is/are benign on fine-needle aspiration cytology. Four patients (1.46%) were confirmed as Marine-Lenhart Syndrome as per the criteria. Three patients were female, and one was male. The eye signs were present in two of four patients. Two patients had two hypofunctioning nodules, whereas the remaining two had a single nodule and required re-ablation with radioiodine. Marine-Lenhart Syndrome requires special attention as these patients are relatively radioiodine resistant, require higher activity for iodine-131; however, it is curable with radioiodine treatment.

Keywords: Cold nodules, Marine-Lenhart Syndrome, nodular Graves' disease, scintigraphy, thyroid scan

INTRODUCTION

Graves' disease is the most common cause of thyrotoxicosis. The pathophysiology is different from toxic multinodular goiter (TMNG) or toxic adenomas. Graves' disease is an autoimmune disease with thyroid hormone receptor stimulating antibodies (TSHR) in the body, causing excess hormone production, whereas, in TMNG, there are multiple functioning nodules in the thyroid. Various studies have shown the incidence of thyroid nodules being 2%–6% by palpation, 19%–35% in ultrasonography (USG), and 8%–65% in autopsy series.^[1] Most of them are benign hypofunctioning colloid nodules.

In general, the thyroid gland nodules are seen in approximately 10%–15% of patients with Graves' disease.^[2] They exist as a broad spectrum of conditions, including Graves' with Hashimoto's pseudo nodules, nodular goiter, autonomous

adenomas, hyperplastic nodules, and differentiated thyroid cancer. Thyroid scintigraphy with technetium-99 m (Tc-99m) pertechnetate is a well-established nuclear medicine study to differentiate between various causes of thyrotoxicosis. The mechanism of uptake of pertechnetate is through sodium

KANHAIYALAL AGRAWAL, P. SAI SRADHA PATRO, BIKASH RANJAN MEHER¹, GOPINATH GNANASEGARAN²

Departments of Nuclear Medicine and ¹Pharmacology, All India Institute of Medical Sciences, Bhubaneswar, Odisha, India, ²Department of Nuclear Medicine, Royal Free NHS Hospital Trust, London, UK

Address for correspondence: Dr. Kanhaiyalal Agrawal, Department of Nuclear Medicine, All India Institute of Medical Sciences, Bhubaneswar, Odisha, India.
E-mail: nuemed_kanhaiyalal@aiimsbhubaneswar.edu.in


Submitted: 25-Sep-2020, **Revised:** 14-Jan-2021,

Accepted: 26-Jan-2021, **Published:** 22-Sep-2021

This is an open access journal, and articles are distributed under the terms of the Creative Commons Attribution-NonCommercial-ShareAlike 4.0 License, which allows others to remix, tweak, and build upon the work non-commercially, as long as appropriate credit is given and the new creations are licensed under the identical terms.

For reprints contact: WKHLRPMedknow_reprints@wolterskluwer.com

How to cite this article: Agrawal K, Patro PS, Meher BR, Gnanasegaran G. Prevalence of Marine-Lenhart syndrome on ^{99m}Tc-thyroid scintigraphy and response to radioiodine: A single institutional retrospective study. World J Nucl Med 2021;20:369-73.

Access this article online	
Website: www.wjnm.org	Quick Response Code 
DOI: 10.4103/wjnm.wjnm_130_20	

iodide symporters (NIS) in the thyroid follicles. In Graves' disease, there is greater expression of NIS due to stimulation by TSHR antibodies which is independent of endogenous TSH, hence shows increased tracer uptake in the thyroid. Radioiodine therapy with beta-emitting iodine-131 (I-131) is a commonly performed treatment for persistent Graves' disease with the primary goal to achieve the hypothyroid state.

Marine-Lenhart Syndrome or nodular Graves' disease is a rare entity of Graves' disease which fulfills the following criteria: (a) the thyroid scintigraphy showing features of Graves' disease with one or two poorly functioning nodules; (b) the nodules are TSH dependent and the extranodular thyroid tissue is independent of TSH; (c) there is the return of nodular function after endogenous or exogenous TSH stimulation; and (d) the nodule(s) is/are benign on histopathology.^[3] These characteristics can be better demonstrated by thyroid scintigraphy with Tc-99m pertechnetate when there is a nodule which is clinically visible or detected on ultrasonography in a patient with Graves' disease. Patients with nodular Graves' disease show characteristic overall increased uptake of tracer but the hypofunctioning TSH-dependent nodules show reduced tracer uptake. Postradioiodine ablation when there is endogenous stimulation of TSH, these nodules show regain of tracer uptake due to increase in NIS expression.

It is always essential to identify this syndrome as these nodules show greater resistance to radioiodine, hence require higher radioiodine dose to treat the thyrotoxicosis. It is also essential to rule out any sinister pathology in these nodules by fine-needle aspiration cytology (FNAC) before radioiodine ablation. In this retrospective study, we reviewed the prevalence of Marine-Lenhart Syndrome in Graves' disease patients on Tc-99m pertechnetate thyroid scintigraphy and the role of radioiodine treatment in this disorder.

MATERIALS AND METHODS

The study was performed in the department of nuclear medicine of a tertiary care hospital in India. The institutional ethics committee approved this study through reference number T/IM-NF/Nuc.Med/20/07. The study retrospectively reviewed the patients' database in whom thyroid scintigraphy was performed between January 2018 and March 2020. We searched the patients with clinical findings reports suggestive of Graves' disease within this group. Further, we identified the patients with the following criteria to suggest Marine-Lenhart Syndrome:

- a. Initial thyroid scintigraphy showing features of Graves' disease with poorly functioning nodules
- b. Return of tracer uptake within the nodule on the thyroid scan after radioiodine ablation
- c. Nodule(s) is/are benign on FNAC.

Patients were followed up after radioiodine ablation to assess response to ablation and characterization of the nodules on follow-up thyroid scintigraphy.

RESULTS

We reviewed the record of all patients who underwent Tc-99m thyroid scintigraphy between January 2018 and March 2020. Out of these, 274 patients had clinical and scan findings consistent with diffuse toxic goiter or Graves' disease. Four of these 274 patients (1.46%) were confirmed as Marine-Lenhart Syndrome as per the criteria. Three patients were female, and one out of four was a male patient. The eye signs were present in two of four patients. Two patients had two hypofunctioning nodules, whereas the rest two of them had a single nodule. Further, re-ablation with radioiodine was required in two patients.

Patient 1

A 46-year-old female presented with chief complaints of neck swelling and weight loss for the past 2 years. The patient also had palpitations, excessive sweating, generalized weakness, and menstrual irregularity. On clinical examination, the patient had a neck swelling (left > right), which moved with deglutition, painless, and was rubbery inconsistency. There was no significant cervical lymphadenopathy. However, significant findings include sinus tachycardia, tremor, and bilateral exophthalmos. The thyroid profile suggested thyrotoxicosis, while the patient was on treatment with carbimazole. Given the persistence of thyrotoxicosis, she was referred for radioiodine ablation. Tc-99m pertechnetate thyroid scintigraphy [Figure 1a] showed increased trapping function in both enlarged lobes (pertechnetate uptake at 20 min was 28%) with a coexistent large cold nodule at the inferior pole of the left thyroid lobe. Overall findings suggested Graves' disease with a cold nodule. USG of the thyroid suggested the nodule as a benign colloid nodule and was confirmed on fine-needle aspiration cytology (FNAC). After ruling out malignancy, 10 mCi of I-131 radioiodine ablation was performed with conservative management of symptoms. On follow-up after 3 months, there was a partial clinical and biochemical response. Because of this, re-ablation with 15 mCi of I-131 radioiodine was performed. The follow-up thyroid scintigraphy showed normal tracer uptake in the previously seen cold nodule [Figure 1b]. Later, she became biochemically hypothyroid and was started on levothyroxine supplementation.




Figure 1: Preablation Tc-99m thyroid scintigraphy (a) shows increased trapping function in both enlarged lobes (uptake at 20 min – 27.7%) with a large cold nodule at the inferior pole of the left thyroid lobe suggestive of Graves' disease with a cold nodule. Postradioiodine ablation scan (b) shows normalization of tracer uptake in the previously described cold nodule. Fine-needle aspiration cytology from the nodule showed benign pathology

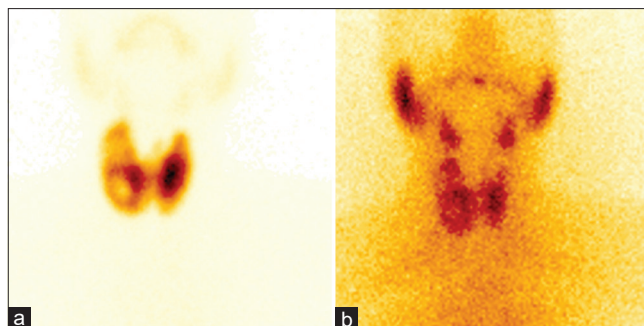


Figure 2: Preablation Tc-99m thyroid scintigraphy (a) shows increased trapping function in both lobes of the enlarged thyroid gland (uptake at 20 min – 19.7%) with cold nodules at the upper and lower poles of the right thyroid lobe. Overall findings were suggestive of Graves' disease with cold nodules in the right thyroid lobe. Postradioiodine ablation scan (b) shows normalization of tracer uptake in the previously described cold nodules and the rest of the thyroid

Patient 2

A 42-year-old female presented with chief complaints of neck swelling and generalized weakness for the past 3 years. She also complained of frequent loose motions, palpitation, and loss of weight. The patient had sinus tachycardia with a pulse rate of 121/min and blood pressure 156/94 mmHg on clinical examination. She had a diffuse neck swelling, which moved with deglutition, painless, and was elastic in consistency are two different words. There was no palpable nodule within the thyroid or lymphadenopathy in the neck, and there were no eye signs. Her thyroid profile was suggestive of thyrotoxicosis and was treated with carbimazole and propranolol with no significant response. Tc-99m pertechnetate thyroid scintigraphy [Figure 2a] showed increased trapping function within both lobes of the enlarged thyroid gland (pertechnetate uptake at 20 min was 20%) with coexisting cold nodules at the upper and lower poles of the right thyroid lobe. The background activity was suppressed. Overall findings were suggestive of Graves' disease with cold nodules in the right thyroid lobe. USG of the thyroid suggested the nodule as a cystic colloid nodule. After ruling out malignancy on FNAC, 15 mCi of I-131 ablation was performed. During the follow-up after 3 months, the patient was clinically and biochemically euthyroid. The follow-up thyroid scintigraphy showed normal tracer uptake in the previously described cold nodule with pertechnetate uptake at 20 min was 1.0% [Figure 2b].

Patient 3

A 40-year-old female presented with neck swelling for the past 5 years. The patient also had weight loss, palpitation, and anxiety. On clinical examination, she had sinus tachycardia (pulse rate 131/min) and blood pressure 160/96 mmHg. She had a diffuse neck swelling, which moved with deglutition, painless, and was rubbery in consistency are two different words. There was also a palpable nodule within the

thyroid but no lymphadenopathy in the neck. There were no eye signs. Her thyroid profile suggested thyrotoxicosis and was under medical management with carbimazole. Because of the persistence of thyrotoxicosis, she was referred for radioiodine ablation. Tc-99m pertechnetate thyroid scintigraphy [Figure 3a] showed increased trapping function in enlarged lobes (pertechnetate uptake at 20 min – 31.5%) along with photopenic areas in both thyroid lobes. The background activity was suppressed. Overall findings were suggestive of Graves' disease with two cold nodules. USG of the thyroid suggested the nodules as benign colloid nodules, which was further confirmed with FNAC. 15 mCi I-131 was administered orally for radioiodine ablation. During the follow-up after 3 months, there was a partial clinical and biochemical response. Because of this, re-ablation with 15 mCi I-131 was performed. On further follow-up, thyroid scintigraphy showed normal tracer uptake in the previously seen cold nodules [Figure 3b]. Later, she was biochemically hypothyroid and was started on levothyroxine supplement.

Patient 4

A 27-year-old male with chief complaints of weight loss and palpitations presented for thyroid scintigraphy for the last 2 years. He also complains of loose motions. Clinically, he had mild neck swelling, which moved with deglutition (Grade I goiter) with no palpable neck node. The patient had tremor and mild bilateral proptosis. The patient was prescribed carbimazole and propranolol. Given the persistence of thyrotoxicosis, he was referred for radioiodine ablation. Tc-99m pertechnetate thyroid scintigraphy [Figure 4a] showed increased trapping function in both enlarged lobes (pertechnetate uptake at 20 min – 20%) with relatively decreased uptake at the inferior pole of the right lobe. Overall findings suggested Graves' disease with a warm nodule. USG of the thyroid described it as a benign colloid

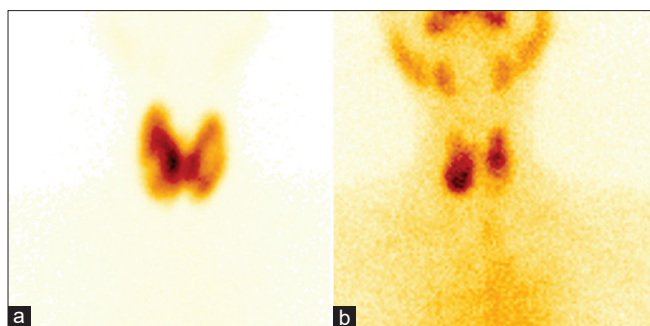


Figure 3: Increased uptake in both lobes of the enlarged thyroid (uptake at 20 min – 31.5%) with photon deficient areas in both lobes on preablation Tc-99m thyroid scintigraphy (a) suggestive of Graves' disease with two cold nodules. Postradioiodine ablation scan (b) shows increase in tracer uptake in the previously described cold nodules

nodule, which was confirmed with FNAC. 15 mCi of I-131 was administered orally for radioiodine ablation. On follow-up, thyroid scintigraphy showed increased tracer uptake in the nodule compared to the previous study [Figure 4b]. On further follow-up, the patient became biochemically hypothyroid and was prescribed a levothyroxine supplement.

DISCUSSION

In this study, we found the prevalence of Marine-Lenhart syndrome in patients with Graves' disease to be 1.46%. Further, there was female predilection (three out of four patients), which corresponds to the known fact that a higher incidence of thyroid nodules occurs in females. The prevalence is reported between 2.7% and 4.3%.^[2,4,5]

Marine-Lenhart Syndrome is a rare entity of Graves' disease where it coexists with TSH sensitive functioning nodules. D. Marine and C. H. Lenhart first described the entity in the year 1911.^[6] Subsequently, the term was coined by David Charkes in 1972 when he described ten patients with Graves' disease and functioning nodules with the following characteristics as described: (a) nonsuppressibility of radioiodine uptake in a hyperthyroid patient whose thyroid gland contains one or more functioning nodules; (b) TSH failed to alter the scintigraphy appearance of the thyroid; (c) overall radioiodine uptake is stimulated by TSH; (d) stimulation of radioiodine uptake by the nodule by TSH, 1.7-fold or greater.^[7] However, recently many authors have suggested following new criteria refining the old one to classify the disease as Marine-Lenhart Syndrome, which we used as the eligibility criteria in this study:^[3] (a) the thyroid scintigraphy showing features of Graves' disease with one or two poorly functioning nodules; (b) the nodules are TSH dependent and the extranodular thyroid tissue is independent of TSH – proven by uptake in nodules after an increase in TSH level due to radio ablation; (c) there

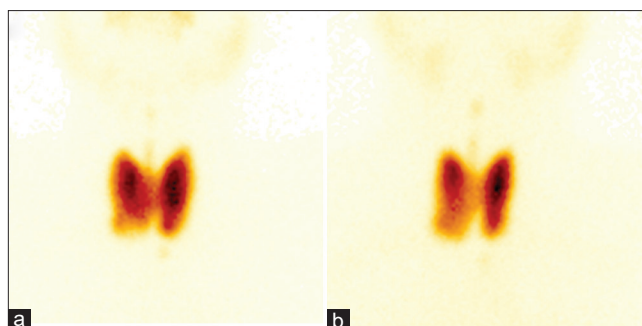


Figure 4: Increased trapping function in both lobes of the enlarged thyroid gland (uptake at 20 min – 19.8%) with relatively decreased uptake at the inferior pole of the right lobe on preablation Tc-99m thyroid scintigraphy (a), suggestive of Graves' disease with a warm nodule. Postradioiodine ablation scan (b) shows increase in tracer uptake in the previously described cold nodules

is a return of nodular function after endogenous or exogenous TSH stimulation; (d) the nodule(s) is/are benign on histopathology. These characteristics can be well demonstrated by Tc-99m pertechnetate thyroid scintigraphy as the mechanism of its uptake is based on NIS expression by the thyroid follicles which is increased by the TSHR stimulating antibodies in Graves' disease (independent of endogenous TSH) whereas the hypofunctioning nodules having TSH dependent NIS expression appear as cold nodules. Postendogenous TSH stimulation after radioiodine ablation, there is return of trapping function of these nodules on thyroid scintigraphy further confirming the diagnosis. The presence of exophthalmos and acropathy features clinically further differentiate this rare entity of nodular Graves' disease from toxic multinodular goiter. This autoimmune condition can also be confirmed biochemically by the presence of thyroid-stimulating antibodies. In our study, only half of the patients had exophthalmos.

Since the reported incidence of malignancy in all cold nodules is about 10%, it must be ruled out using USG and FNAC before proceeding for radioiodine therapy. The most common type of malignancy in the thyroid in the presence of Graves' disease is papillary thyroid cancer.^[8] In case of malignant nodules, surgery is the treatment of choice.

All cases in the present study required a higher activity of I-131 with two of the patients requiring a second radioiodine ablation, supporting the fact that they are relatively radioiodine resistant. The relative radioiodine resistance of these nodules was explained histopathologically as marked nuclear polyploidy in the extranodular tissue but only scattered polyploidy in these follicular adenoma nuclei. It makes the extranodular tissue more susceptible to radioiodine damage.^[7] Previous studies have also shown that these cases of nodular Graves' disease can be successfully

treated with non-surgical means by I-131 radioiodine ablation with a complete resolution with a slightly higher activity of radioiodine.^[2]

The current study has a few limitations. The study was retrospective, and USG thyroid was not performed in all the patients. Hence, we might have missed a few tiny or small nodules in Graves' disease on thyroid scintigraphy. However, possibly the radioiodine treatment dose is not affected in a small cold nodules setting. Nevertheless, confirmation in a future study is required.

CONCLUSION

Marine-Lenhart Syndrome is a rare entity of Graves' disease coexisting with hypofunctioning nodules on thyroid scintigraphy. This entity needs special attention as these patients are relatively radioiodine resistant, requiring higher activities of I-131. However, it is curable with radioiodine treatment. Further, sinister pathology has to be ruled out pre ablation because of malignancy risk in cold nodules. These nodules usually gain tracer uptake after normalization of TSH following successful ablation. The gain of function or uptake of these nodules can be seen on a thyroid scintigraphy postablation. Thus, thyroid scintigraphy pre- and postablation in nodular Graves' disease helps in characterizing this rare entity.

Declaration of patient consent

The authors certify that they have obtained all appropriate patient consent forms. In the form the patient(s) has/have

given his/her/their consent for his/her/their images and other clinical information to be reported in the journal. The patients understand that their names and initials will not be published and due efforts will be made to conceal their identity, but anonymity cannot be guaranteed.

Financial support and sponsorship

Nil.

Conflicts of interest

There are no conflicts of interest.

REFERENCES

1. Dean DS, Gharib H. Epidemiology of thyroid nodules. *Best Pract Res Clin Endocrinol Metab* 2008;22:901-11.
2. Carnell NE, Valente WA. Thyroid nodules in Graves' disease: Classification, characterization, and response to treatment. *Thyroid* 1998;8:647-52.
3. Harisankar CN, Preethi GR, Chungath BB. Hybrid SPECT/CT evaluation of Marine-Lenhart syndrome. *Clin Nucl Med* 2013;38:e89-90.
4. Cakir M. Marine-Lenhart syndrome. *J Natl Med Assoc* 2005;97:1036-8.
5. Chandramouly B, Mann D, Cunningham RP, Giegerich E. Marine-Lenhart syndrome. Graves' disease with poorly functioning nodules. *Clin Nucl Med* 1992;17:905-6.
6. Marine D, Lenhart CH. Pathological anatomy of exophthalmic goiter: The anatomical and physiological relations of the thyroid gland to the disease; the treatment. *Arch Intern Med* 1911;8:265-316.
7. Charkes ND. Graves' disease with functioning nodules (Marine-Lenhart syndrome). *J Nucl Med* 1972;13:885-92.
8. Boutzios G, Vasileiadis I, Zapanti E, Charitoudis G, Karakostas E, Ieromonachou P, *et al.* Higher incidence of tall cell variant of papillary thyroid carcinoma in Graves' Disease. *Thyroid* 2014;24:347-54.