

Modified double-opposing Z-plasty for patients with Veau I cleft palate

Are lateral relaxing incisions necessary?

Hyung Joon Seo, MD^{a,b}, Rafael Denadai, MD^a, Dax Carlo Go Pascasio, MD^a, Lun-Jou Lo, MD^{a,*}

Abstract

Low fistula rate and a satisfactory speech outcome were previously reported by adopting a modified Furlow palatoplasty using small double-opposing Z-plasty (DOZ). The purposes of this study were to (1) describe the technical standardization of further modification of this small DOZ using the medial incision (MIDOZ) approach for Veau I cleft repair; (2) assess the early postoperative outcomes of a single surgeon's experience using this technique; and (3) evaluate the temporal association of this standardization with the necessity of lateral relaxing incisions.

A prospective study (n=24) was performed consecutively to non-syndromic patients with Veau I cleft palate who underwent MIDOZ approach. Patients with similar characteristics who underwent small DOZ were included as a retrospective group (n=25) to control for the potential effect of the standardization of surgical maneuvers (including the hamulus fracture) on the rate of lateral relaxing incisions. Six-month complication rate was collected.

No postoperative complications, such as bleeding, flap necrosis, dehiscence or fistula were observed. The prospective group had a significantly (all $P < .05$) higher rate of hamulus fractures (n=48, 100%) and a lower rate of lateral relaxing incisions (n=1, 2%) than the retrospective group (n=16, 32%; n=26, 52%).

This technical standardization for performing palatoplasty using MIDOZ approach provided adequate Veau I cleft palate closure, without fistula formation, and with a low need of lateral relaxing incisions.

Abbreviations: DOZ = double-opposing Z-plasty, MIDOZ = medial incision double-opposing Z-plasty.

Keywords: cleft palate, fistula, palatoplasty, relaxing incision, Z-plasty

1. Introduction

Outcomes of cleft palate repairs have improved significantly with the evolution of technical refinements over the last decades, with increasing emphasis on a 2-layer, tension-free closure to decrease the risk of postoperative fistula formation, achieve a proper muscle repair (e.g., straight-line approaches with levator muscle

repositioning or Furlow double-opposing Z-plasty [DOZ] with muscle overlapping) to restore a mechanism for normal speech production, and also to reduce the bone exposure and scar formation to attenuate maxillary growth interference.^[1–5] However, there still has been controversy in establishing consensus regarding an optimal surgical technique for all Veau cleft types.^[6–16]

After Dr Leonard Furlow described the DOZ for palatal repair in 1978,^[17] this technique has been widely adopted for cleft palate repairs worldwide.^[8,12,18–27] Dr Samuel Noordhoff performed the first palatoplasty using DOZ at the Chang Gung Memorial Hospital in 1985.^[21] Since then, the Furlow's original technique as well as modified Furlow procedures have been adopted by subsequent generations of plastic surgeons for primary palatoplasty and correction of velopharyngeal insufficiency.^[22–27] The senior author demonstrated a modified DOZ in the primary palate repair and achieved a low fistula rate and satisfactory speech outcome.^[27]

Based on the experience accumulated in last 20 years, the senior author has noticed anecdotally that the subgroup of patients with Veau I cleft palate may be repaired by a further modified small DOZ using only medial incision approach (namely, the medial incision DOZ; MIDOZ) with no lateral relaxing incisions of the hard or soft palate, no bony exposure, and consequently, less scar formation. To this end, specific principles of meticulous tissue dissection and mobilization (oral and nasal layers, greater palatine pedicle, and pyramidal process region)^[28–30] as well as muscle reconstruction using small DOZ^[27] were combined in a standardized fashion using an only medial incision to maximize vascularity and to allow adequate palatal flap mobilizations with tension-free closure. The

Editor: N/A.

HJS and RD contributed equally in this study.

The study was reviewed and approved by the Institutional Review Board, Chang Gung Medical Foundation (201900008B0).

The authors have no funding and conflicts of interest to disclose.

Supplemental Digital Content is available for this article.

^a Department of Plastic and Reconstructive Surgery and Craniofacial Research Center, Chang Gung Memorial Hospital, Chang Gung University, Taoyuan, Taiwan, ^b Department of Plastic and Reconstructive Surgery, Pusan National University Hospital, Busan, Korea.

* Correspondence: Lun-Jou Lo, Department of Plastic and Reconstructive Surgery, Chang Gung Memorial Hospital, 5 Fu-Shin Street, Kwei Shan, Taoyuan 333, Taiwan (e-mail: lunjoulo@cgmh.org.tw).

Copyright © 2019 the Author(s). Published by Wolters Kluwer Health, Inc. This is an open access article distributed under the terms of the Creative Commons Attribution-Non Commercial License 4.0 (CCBY-NC), where it is permissible to download, share, remix, transform, and buildup the work provided it is properly cited. The work cannot be used commercially without permission from the journal.

How to cite this article: Seo HJ, Denadai R, Pascasio DC, Lo LJ. Modified double-opposing Z-plasty for patients with Veau I cleft palate: are lateral relaxing incisions necessary?. *Medicine* 2019;98:50(e18392).

Received: 29 April 2019 / Received in final form: 22 September 2019 /

Accepted: 15 November 2019

<http://dx.doi.org/10.1097/MD.00000000000018392>

senior author hypothesizes that this MIDOZ technique could not increase the fistula formation for early postoperative outcome while achieving a satisfactory speech outcome and diminishing the possible adverse effect to the transverse maxillary arch development and midfacial growth for long-term postoperative outcomes.

The purposes of this study were to (1) describe the technical standardization of the MIDOZ for patients with Veau I cleft palate; (2) assess the early postoperative outcomes of a single senior surgeon's experience using this technique; and (3) evaluate the temporal association of this standardization with the necessity of lateral relaxing incisions.

2. Methods

A prospective study was performed of consecutive non-syndromic patients with Veau I cleft palate who underwent primary palatoplasty using the MIDOZ at the Craniofacial Center, Chang Gung Memorial Hospital between January 2018 and January 2019. Consecutive non-syndromic patients with Veau I cleft palate who underwent primary modified Furlow palatoplasty using double opposing Z-plasty between 2015 and 2017 were included as a retrospective group to control for the potential effect of the standardization of surgical maneuvers on the rate of lateral relaxing incisions and postoperative fistula formation. The study was reviewed and approved by the Institutional Review Board, Chang Gung Medical Foundation (201900008B0). Patient's informed consents by the parents were obtained.

Demographic and surgical (adopted surgical maneuvers [hamulus fracture and lateral relaxing incisions] and complications) data were collected. Postoperative complications such as bleeding requiring operative intervention, flap necrosis, wound dehiscence (a breakdown of partial thickness of repair that spontaneously closed without intervention) and fistula (any communication between the oral and nasal cavities due to complete, full-thickness breakdown of repair)^[27,30] were identified based on multidisciplinary clinical examinations during hospital stay/visits at 1, 7 and 14 days and 1, 3 and 6 months after cleft palate repair. The final data collection was performed in mid-July 2019.

Patients with age at primary cleft palate repair older than 15 months, submucous cleft palate, Veau II to IV cleft palate, presence of any associated syndrome (e.g., Pierre Robin sequence), and/or incomplete medical records were excluded from this study. The study was approved by the Institutional Review Board (Chang Gung Medical Foundation, 201900008B0) and complied with the 1983 amendment of the 1975 Declaration of Helsinki.

2.1. Surgical technique

Cleft palate repair was routinely performed at 9 months of age, however in some occasions, was delayed until 12 to 15 months of age due to late referral or medical issues. All procedures were conducted by a single senior surgeon (LJL) using a 2.5× loupe magnification.

Incision line was designed from uvula to cleft edge between the nasal and oral mucosa in both side, then midline anterior extension was designed on hard palate (Fig. 1). After infiltration with epinephrine solution, medial incision was done in the soft palate extending to the uvula using a no. 11 blade. The midline

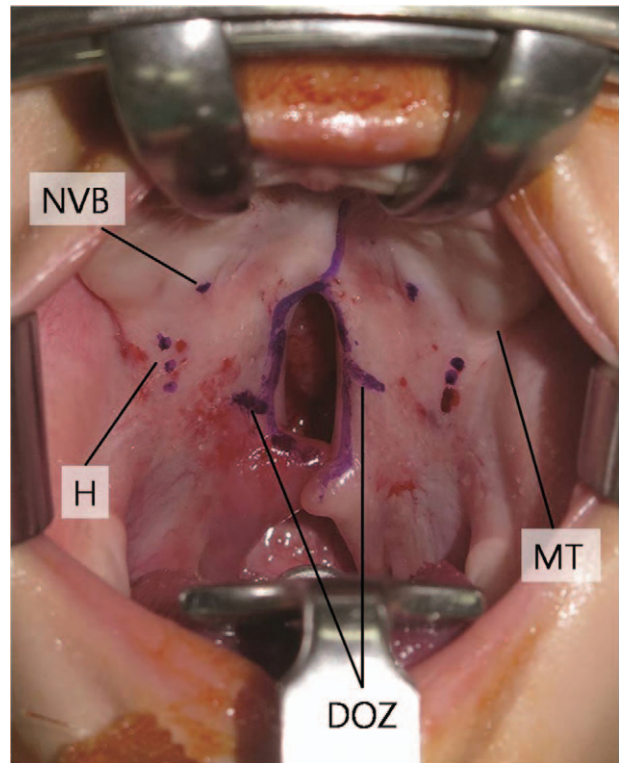


Figure 1. Design for the MIDOZ. DOZ = double-opposing Z-plasty (oral side), H = pterygoid hamulus, MT = maxillary tuberosity, NVB = neurovascular bundle.

hard palate incision was performed using a no. 15 blade. Through the left side medial incision, the following surgical maneuvers were carefully executed in a standardized sequence for the prospective group: elevation of the oral mucoperiosteal flap from the hard palate; detachment of malpositioned insertion of the levator palatini muscle to the posterior margin of the palatal bone; circumferential dissection of the greater palatine neurovascular bundle; releasing of the ligamentous fibers in the pyramidal process region; identification of the pterygoid hamulus and space of Ernest; cutting of the hamulus at the base with preserving the integrity of the tensor veli palatini muscle; widening of space of Ernst; and elevation of the nasal flap from the palatal bone (Figs. 2 and 3). All these steps were performed in the right side, except for the difference in the levator muscle dissection. For the oral-side flaps, the left side was elevated as a musculomucosa flap and the right side as a mucosal flap only. For the nasal-side flaps, the musculomucosa flap was on the right side and the mucosal flap on the left side. It is advised that a thin muscle layer be left in the left nasal mucosa flap and right side oral mucosal flap to ensure flap integrity with more vascularity. Following these steps, the flap mobilizations were clinically judged (see Video 1, <http://links.lww.com/MD/D491>, Supplemental Video (that demonstrate the step-by-step for the incision and dissection of Veau I cleft repair using the medial incision approach. 4 minutes 4 seconds, 353 MB), which demonstrates the step-by-step for the Veau I cleft repair using the only medial incision approach). If the flaps could easily align without tension in the midline, no lateral relaxing incision was necessary. If tension was present, a lateral relaxing incision was made on one side and then on the other side if needed. A buccal fat pad flap was adopted for covering the lateral relaxing incision site. After

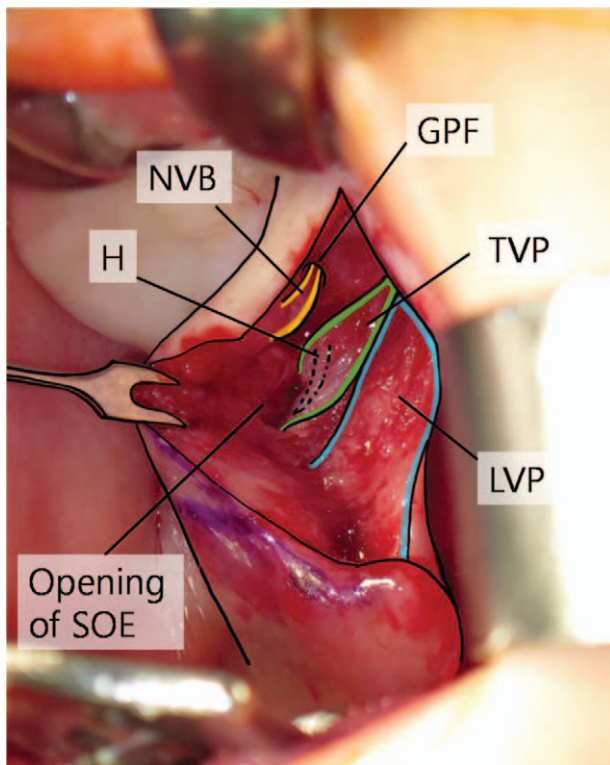


Figure 2. Major anatomical components after dissection through the only medial incision approach. GPF=greater palatine foramen, H=pterygoid hamulus, LVP=levator veli palatini muscle, NVB=neurovascular bundle, SOE=space of Ernst, TVP=tensor veli palatini muscle.

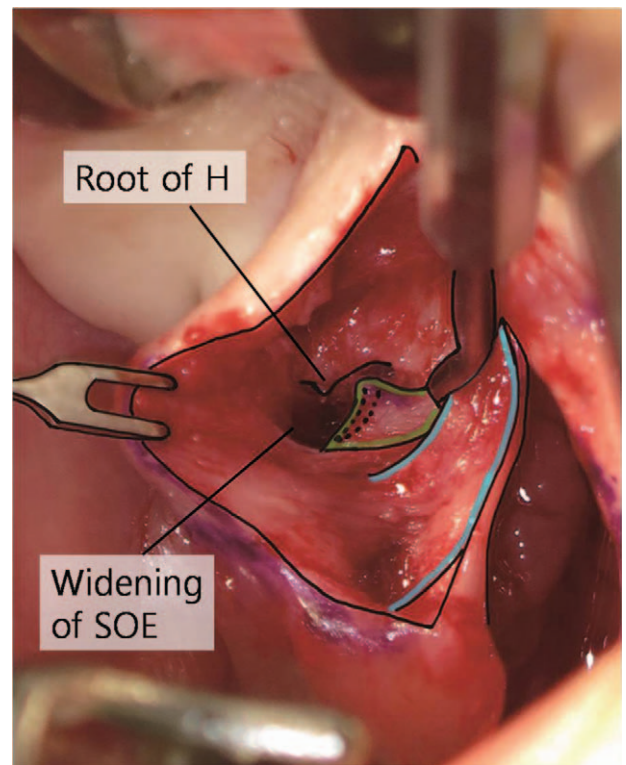


Figure 3. Pterygoid hamulus (H) fracture and widening of the space of Ernst (SOE) to enhance flap mobilization.

completion of flap dissections, the small DOZ technique^[27] was performed for muscle reconstruction (Figs. 4 and 5; see Video 2, <http://links.lww.com/MD/D492>, Supplemental Video (that demonstrate the step-by-step for the muscle reconstruction using the double-opposing Z-plasty technique, and wound closure under reduced tension without lateral relaxing incision. 2 minutes 15 seconds, 195 MB), which demonstrates the step-by-step for the muscle reconstruction using the double-opposing Z-plasty technique).

For the retrospective group, all repairs were performed as preconized in the modified Furlow palatoplasty using small DOZ,^[27] but the intraoperative decisions regarding the need for hamulus fracture and/or the lateral relaxing incisions were not standardized as described for the prospective group.

2.2. Statistical analysis

In the descriptive analysis, the mean and standard deviations were used for metric variables, and percentages were given for categorical variables. Chi-square test was adopted for comparative analyses. For all tests, $P < .05$ was considered statistically significant. All analyses were performed with the Statistical Package for Social Sciences (SPSS version 17.0 for Windows, Chicago, IL).

3. Results

A total of 49 non-syndromic patients with Veau I cleft palate who underwent primary palatoplasty using the MIDOZ technique ($n=24$, 49%) or the small DOZ technique ($n=25$, 51%) were

included (Table 1). No significant difference was observed among the included groups regarding age at surgery or gender (all $P > .05$). No postoperative complications, such as bleeding, flap necrosis, dehiscence, or fistula, were observed in this cohort study.

In the comparative analyses, the prospective group presented a significantly (all $P < .05$) higher rate of hamulus fractures ($n=48$, 100%) and a lower rate of lateral relaxing incisions ($n=1$, 2%) than the retrospective group ($n=16$, 32%; $n=26$, 52%; Table 1).

4. Discussion

Numerous refinements in the basic cleft palate repair principles have been described, but the optimal repair still remains scientifically unproven.^[6–21,27–30] Within the armamentarium of cleft surgical maneuvers, the lateral relaxing incisions have been systematically adopted in all patients or selectively used when further palatal flap mobilization is required based on the intraoperative judgment case by case.^[6–21,27] However, there is a debate about the potential harms of these lateral relaxing incisions as the exposed raw surface, the healing by secondary intention, and the scarring process may impair the maxillary arch development and anteroposterior maxillary growth.^[2,3,31] While there is no unanimity in the literature regarding the casual independent factor for maxillary growth disturbance after cleft palate repair, the lateral relaxing incisions remains as a likely factor among the multiple potential factors.^[2,3,31,32]

In this study, we evaluated the evolutionary experience of a senior surgeon in the treatment of patients with Veau I cleft palate. For this subgroup of cleft patients, satisfactory outcomes (absence of fistula and 14 of 16 patients, 88%, had no

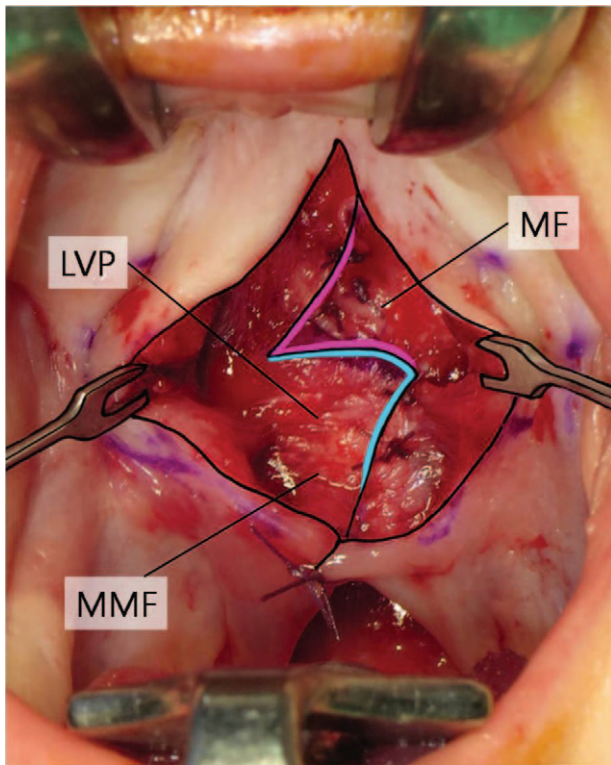


Figure 4. Nasal side Z-plasty with levator muscle reconstruction. For the nasal side repair, the right posterior-based musculomucosal flap (MMF) was incised at 60° in the middle of the soft palate to achieve a 5-mm limb for the Z-plasty, whereas the left anterior based nasal mucosal flap (MF) was incised at 60° to achieve a corresponding 5-mm limb. The right-nasal-side musculomucosa flap was rotated posteriorly and sutured at appropriate tension (4-0 Vicryl; Ethicon, Inc., Somerville, NJ) to the left-nasal-side mucosal flap. LVP=levator veli palatini muscle.

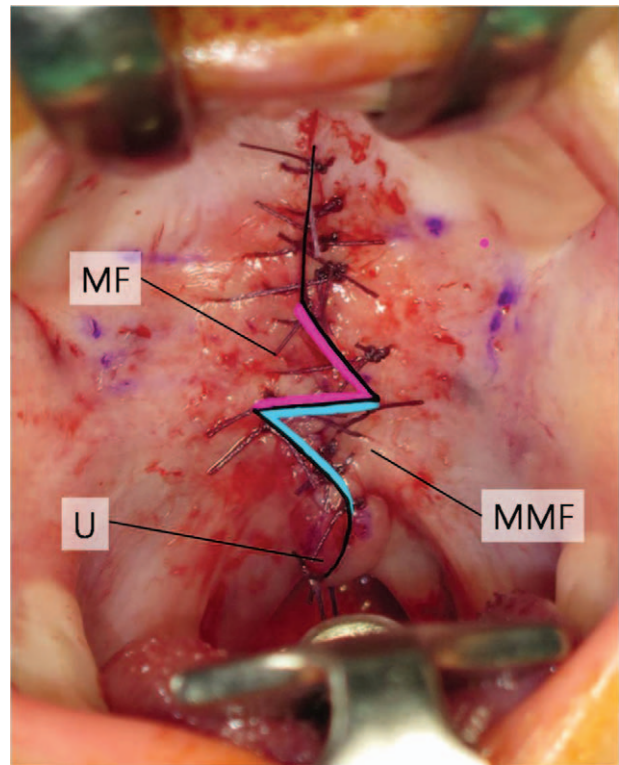


Figure 5. Uvula (U) repair and oral side Z-plasty. For uvula reconstruction, an intermuscular stitch was applied with a single buried suture for intrauvular muscle alignment. A Z-plasty of the opposite fashion was then designed for the oral side repair; the left posterior-based musculomucosal flap (MMF) was rotated posteriorly and sutured to the right anterior-based mucosal flap (MF).

velopharyngeal insufficiency) were reported previously by adopting the palatoplasty using small DOZ.^[27] In this previous study, the surgical maneuvers including the hamulus fracture and the lateral relaxing incisions were not performed in a standardized and sequential manner for all included patients.^[27] This aspect is also revealed by the retrospective group of the present study, as in 83% of patients who received lateral relaxing incisions, the hamulus fracture was not performed.

In this context, the senior author decided to mitigate the future potential negative impact on the maxillary arch development and midface growth while being cautious not to increase the occurrence of fistula and/or velopharyngeal insufficiency. The general long-term target is to decrease the burden in the cleft population. A low rate of fistula and a satisfactory speech outcome may diminish the total number of secondary surgeries. Furthermore, the minimization of the maxillary arch and midface interference may reduce drastically the need for aggressive and time-consuming orthodontic treatment. Importantly, the reduction of the total number of orthognathic surgeries (a common

Table 1
Characteristics of included patients and comparative analysis.

Variables	Prospective group	Retrospective group	Total	P-value [§]
Number of patients	24	25	49	
Gender, female n (%)	15 (63)	18 (72)	31 (63)	>.05
Age at surgery (mo) M±SD	9.6±1.2	8.9±1.1	9.2±1.2	>.05
Surgical maneuvers* n (%)				
Hamulus fracture (yes/no)	48 (100)/0 (0)	16 (32)/34 (68)	64 (65)/34 (35)	<.001
Lateral relaxing incision (yes/no)	1 (2) [‡] /47 (98)	26 (52)/24 (48)	27 (28)/71 (72)	.002
Complications [†]	0 (0)	0 (0)	0 (0)	–

% = percentage of patients, – = not applicable, M = mean, n = number of patients or palatal sides, SD = standard deviation.

* Data presented by palatal side.

† Bleeding, flap necrosis, infection, dehiscence, and/or fistula.

‡ Unilateral lateral relaxing incision.

§ Intergroup comparative analyses.

therapeutic endpoint in cleft literature) has not been considered as a long-term endpoint in our center, because orthognathic surgery has been widely indicated and performed in our cleft patients not only to correct a Class III malocclusion but also to improve the facial appearance, symmetry, proportion, and aesthetics.^[33]

For the proposed MIDOZ approach, and some technical principles^[27-30] were compiled and formally adopted in a systematized way to achieve anatomical reconstruction with decreased disruption of normal tissues. The step-by-step process meticulously described for this approach is considered as a key element for the accurate palatal dissection. It is fundamental that the order of the maneuvers is followed, as each specific step positively influences the subsequent step, and the progressive sum of the steps allow the medial mobilization of flaps. Particularly, the management of the pyramidal process region through the only medial incision is technically demanding as some maneuvers are performed with limited visualization. Traction of the oral flap by skin hook, having the vascular pedicle properly visualized cranially, and releasing the fibrous connections from the pyramidal process permit the identification of the hamulus and space of Ernest using the Penfield elevator no. 1. The hamulus can be then fractured at its base and the space of Ernest be widened with preservation of tensor veli palatini muscle. This technical standardization combined with the appropriate use of instruments (loupe magnification, good lighting, and blunt elevators and scissors) resulted in a significant reduction in the need of lateral relaxing incisions. Notably, this was not accompanied by the increase of the fistula occurrence, in accordance with our primary hypothesis.

One patient in the prospective group required a unilateral lateral relaxing incision to attain sufficient medial approximation of oral side flaps. While potential explanations (e.g., width of cleft, availability of soft tissue, improper anatomical identification and/or mishandling or incomplete execution of one or more of the surgical steps) for this particular patient may be hypothesized, we believe it is essential to emphasize that the ultimate goal of cleft palate repair should be to restore the normal physiological function, rather than the absence of a lateral relaxing incision. Palatal reconstruction without lateral relaxing incisions should not be considered as more important than the benefit of these incisions for tension-free closure and reducing fistula formation. Therefore, the senior surgeon has emphasized for all residents and craniofacial fellows in training the importance of adding unilateral or bilateral lateral relaxing incision whenever there is any tension at the midline or in dubious situations. In these scenarios, the buccal fat pad flap can cover the raw surface and at least partially minimize the secondary healing process with fibrosis.^[27,34]

In the literature, different authors have described modified lateral relaxing incisions (e.g., only a small incision lateral to the hamulus) while others have reported palatoplasty without lateral relaxing incisions.^[30,35-45] Overall, the described benefits of these modified surgical approaches lies on the absence of exposed raw surface or healing by secondary intention, supposedly reducing perioperative contamination, bleeding, and pain and also minimizing postoperative scarring and bone growth interference.^[30,35-45] Most of the previous studies as well as the present investigation have reported only early outcomes such as surgery-related complications including the fistula rate, while others have also demonstrated satisfactory speech outcomes.^[30,35-45] Although some mixed results concerning long-term maxillary arch and/or midface status have been reported after minimal incision

palatoplasty, this should still be the target of future investigations using only medial incision approaches.^[30,35-45]

In these previous studies minimal incision or only medial incision repairs were addressed^[30,35-45] some maneuvers adopted to optimize tension-free closure were similar to those detailed for the MIDOZ approach, while others (e.g., dissection of the alveolar region, tissues extending to the choanae and pterygoid plate) were not adopted in our patients. Because of the potential direct damage to the maxillary arch and/or to the dental germs secondary to the alveolar manipulation, we prefer to perform lateral relaxing incisions to achieve a freely movable oral flap according to the need of each patient. Moreover, the adopted surgical maneuvers allowed tension-free nasal closure without mucosal tearing in our patients, demonstrating that additional dissections or releasing close to the choanae and/or the medial pterygoid plate are not mandatory. One can criticize the MIDOZ approach for incorporating the hamulus fracture as a key surgical step. However, the literature has shown that the hamulus fracture does not have a negative effect on the middle ear outcome including otitis media with effusion, need for tympanostomy tubes, and hearing ability.^[30,46,47] Certainly, other surgeons may substitute or incorporate different maneuvers into our technique and compare the results of these modifications in future studies.

Both straight-line intravelar veloplasty and Furlow DOZ methods have been adopted for palatal muscle reconstruction in previous studies reporting only medial incision repairs.^[30,35] As complete separation of the velar muscle from the oral and nasal mucosa and the achievement of optimal midline tension are not simple, the intravelar veloplasty has been considered as more operator dependent than the DOZ.^[4,41,43] The resulting scar in straight-line intravelar veloplasty methods may theoretically result palatal shortening due to the longitudinal scar contraction.^[4] On the other hand, DOZ preserves intact musculomucosa layers, breaks linear scar and also decreases scarring of the soft palate due to the optimized flap vascularity.^[4,12,17-21,27] The original Furlow DOZ provides a significant lengthening of the soft palate, whereas when used without lateral relaxing incisions it may result tension.^[4,12,17-21] In our small DOZ technique, each limb was only 5 mm as the central concept has been not only to lengthen the soft palate but also to facilitate dissection of abnormal muscle insertions, to obtain enough palatal muscle for repositioning and to achieve wound closure with minimal tension.^[27] If an adequately functioning soft palate with a transverse orientation of the levator muscle sling is achieved, the additional length of the originally reported Z-plasty is not required to attain adequate velopharyngeal closure.^[12,17-21,27] However, we did not have further comparative groups, such as patients receiving straight-line intravelar veloplasty or hybrid repairs (e.g., mucosal Z-plasty in combination with intravelar veloplasty). Future studies encompassing different surgical approaches in a well-selected cohort of patients would test the hypotheses raised here.

There were limitations in this study. For the retrospective group, the study design was a retrospective chart review and therefore subject to confounding errors. As we assessed the experience of a single senior surgeon working in a hospital considered as a high-volume center,^[48] any extrapolation of the findings should be carried out with caution. Similar to previous studies,^[30,35-45] the intraoperative judgment and decision-making regarding the grade of tension in the midline and the need for lateral relaxing incision was subjective and dependent on

the experience of each surgeon. Since, all patients were included in the last 3 years of practice, the clinical judgment of the senior surgeon can be considered constant in both the evaluated periods. Therefore, we consider that the inclusion of technical maneuvers in a standardized way was the main determining factor in reducing the need for lateral relaxing incisions, without increasing the fistula occurrence. Future studies should evaluate the impact of surgeons with varying degrees of experience and backgrounds^[49,50] in performing the MIDOZ approach.

We included only non-syndromic patients with Veau I cleft palate. As there are only medial incision techniques being applicable to the complete spectrum of clefts (Veau types I–IV),^[30,35–45] others may try to expand the criteria inclusion used here. As the muscle reconstruction was performed according to the previously described palatoplasty using small DOZ, we hypothesize that the speech outcomes will be similar to those previously reported, that is, an overall velopharyngeal insufficiency surgery rate of 5.5%.^[27] The benefit of preventing transverse maxillary arch collapse and anteroposterior midface growth inhibition by having no lateral relaxing incisions remains merely theoretical at this moment because our 6-month follow-up period is too short for any definitive conclusion. These data are prospectively recorded, and the senior surgeon intends to report this outcome in a future long-term longitudinal study. Further parameters not addressed in this study, that is, cleft and palatal lengths and widths,^[18] should also be the target of future investigation.

5. Conclusion

The described surgical standardization for MIDOZ provides successful early outcomes in Veau I cleft repair, with a low need for lateral relaxing incisions and with no increase of postoperative fistula formation.

Acknowledgment

We would like to thank Dr M. Samuel Noordhoff for teaching and supervising the cleft care in this center

Author contributions

Conceptualization: Lun-Jou Lo.

Data curation: Hyung Joon Seo.

Formal analysis: Rafael Denadai.

Investigation: Hyung Joon Seo, Dax Carlo G. Pascasio.

Methodology: Rafael Denadai.

Supervision: Lun-Jou Lo.

Visualization: Dax Carlo G. Pascasio.

Writing – review & editing: Lun-Jou Lo.

References

- Stein MJ, Zhang Z, Fell M, et al. Determining postoperative outcomes after cleft palate repair: a systematic review and meta-analysis. *J Plast Reconstr Aesthet Surg* 2019;72:85–91.
- Kappen IFPM, Yoder WR, Mink van der Molen AB, et al. Long-term craniofacial morphology in young adults treated for a non-syndromal UCLP: a systematic review. *J Plast Reconstr Aesthet Surg* 2018;71:504–17.
- Reddy RR, Gosla Reddy S, Vaidhyanathan A, et al. Maxillofacial growth and speech outcome after one-stage or two-stage palatoplasty in unilateral cleft lip and palate. A systematic review. *J Craniomaxillofac Surg* 2017;45:995–1003.
- Timbang MR, Gharb BB, Rampazzo A, et al. A systematic review comparing Furlow double-opposing Z-plasty and straight-line intravelar veloplasty methods of cleft palate repair. *Plast Reconstr Surg* 2014;134:1014–22.
- Hardwicke JT, Landini G, Richard BM. Fistula incidence after primary cleft palate repair: a systematic review of the literature. *Plast Reconstr Surg* 2014;134:618e–27e.
- Tse RW, Siebold B. Cleft palate repair: description of an approach, its evolution, and analysis of postoperative fistulas. *Plast Reconstr Surg* 2018;141:1201–14.
- Woo AS. Evidence-based medicine: cleft palate. *Plast Reconstr Surg* 2017;139:191e–203e.
- Mann RJ, Martin MD, Eichhorn MG, et al. The double opposing z-plasty plus or minus buccal flap approach for repair of cleft palate: a review of 505 consecutive cases. *Plast Reconstr Surg* 2017;139:735e–44e.
- Hopper RA, Tse R, Smartt J, et al. Cleft palate repair and velopharyngeal dysfunction. *Plast Reconstr Surg* 2014;133:852e–64e.
- Chepla KJ, Gosain AK. Evidence-based medicine: cleft palate. *Plast Reconstr Surg* 2013;132:1644–8.
- Mahoney MH, Swan MC, Fisher DM. Prospective analysis of presurgical risk factors for outcomes in primary palatoplasty. *Plast Reconstr Surg* 2013;132:165–71.
- Jackson O, Stransky CA, Jawad AF, et al. The Children's Hospital of Philadelphia modification of the Furlow double-opposing Z-palatoplasty: 30-year experience and long-term speech outcomes. *Plast Reconstr Surg* 2013;132:613–22.
- Fisher DM, Sommerlad BC. Cleft lip, cleft palate, and velopharyngeal insufficiency. *Plast Reconstr Surg* 2011;128:342e–60e.
- Andrades P, Espinosa-de-los-Monteros A, Shell DH4th, et al. The importance of radical intravelar veloplasty during two-flap palatoplasty. *Plast Reconstr Surg* 2008;122:1121–30.
- Salzer KE, Sng KW, Sperry EE. Two-flap palatoplasty: 20-year experience and evolution of surgical technique. *Plast Reconstr Surg* 2006;118:193–204.
- Cutting C, Rosenbaum J, Rovati L. The technique of muscle repair in the cleft soft palate. *Oper Tech Plast Reconstr Surg* 1995;2:215–22.
- Furlow LTJr. Cleft palate repair by double opposing z-plasty. *Plast Reconstr Surg* 1986;78:724–38.
- Chang BL, Yu JW, Nikonova E, et al. Palatal measurements pre- and post-Furlow cleft palate repair: analysis of palatal lengthening and comparison within cleft types. *Cleft Palate Craniofac J* 2019;56:601–9.
- Losee JE, Smith DM, Afifi AM, et al. A successful algorithm for limiting postoperative fistulae following palatal procedures in the patient with orofacial clefting. *Plast Reconstr Surg* 2008;122:544–54.
- Randall P, LaRossa D, Solomon M, et al. Experience with the Furlow double-reversing z-plasty for cleft palate repair. *Plast Reconstr Surg* 1986;77:569–76.
- Chen KT, Noordhoff SM. Experience with Furlow palatoplasty. *Changcheng Yi Xue Za Zhi* 1994;17:211–9.
- Mardini S, Chim H, Seselgyte R, et al. Predictors of success in Furlow palatoplasty for submucous clefts: an experience with 91 consecutive patients. *Plast Reconstr Surg* 2016;137:135e–41e.
- Chen PK, Wu J, Hung KF, et al. Surgical correction of submucous cleft palate with Furlow palatoplasty. *Plast Reconstr Surg* 1996;97:1136–46.
- Chen PK, Wu JT, Chen YR, et al. Correction of secondary velopharyngeal insufficiency in cleft palate patients with the Furlow palatoplasty. *Plast Reconstr Surg* 1994;94:933–41.
- Yamaguchi K, Lonic D, Lee CH, et al. A treatment protocol for velopharyngeal insufficiency and the outcome. *Plast Reconstr Surg* 2016;138:290e–9e.
- Hsu PJ, Wang SH, Yun C, et al. Redo double-opposing z-plasty is effective for correction of marginal velopharyngeal insufficiency. *J Plast Reconstr Aesthet Surg* 2015;68:1215–20.
- Yamaguchi K, Lonic D, Lee CH, et al. Modified Furlow palatoplasty using small double-opposing z-plasty: surgical technique and outcome. *Plast Reconstr Surg* 2016;137:1825–31.
- Nguyen DC, Patel KB, Parikh RP, et al. Five surgical maneuvers on nasal mucosa movement in cleft palate repair: a cadaver study. *J Plast Reconstr Aesthet Surg* 2016;69:789–95.
- Mendonca DA, Patel KB, Skolnick GB, et al. Anatomical study of the effects of five surgical maneuvers on palate movement. *J Plast Reconstr Aesthet Surg* 2014;67:764–9.
- Kane AA, Lo LJ, Yen BD, et al. The effect of hamulus fracture on the outcome of palatoplasty: a preliminary report of a prospective, alternating study. *Cleft Palate Craniofac J* 2000;37:506–11.

- [31] Rossell-Perry P, Cotrina-Rabanal O, Figallo-Hudtwalcker O, et al. Effect of relaxing incisions on the maxillary growth after primary unilateral cleft palate repair in mild and moderate cases: a randomized clinical trial. *Plast Reconstr Surg Glob Open* 2017;5:e1201.
- [32] Diah E, Lo LJ, Huang CS, et al. Maxillary growth of adult patients with unoperated cleft: answers to the debates. *J Plast Reconstr Aesthet Surg* 2007;60:407–13.
- [33] Lonc D, Pai BC, Yamaguchi K, et al. Computer-assisted orthognathic surgery for patients with cleft lip/palate: from traditional planning to three-dimensional surgical simulation. *PLoS One* 2016;11:e0152014.
- [34] Bennett KG, Thurston TE, Vercler CJ, et al. Harvesting the buccal fat pad does not result in aesthetic deformity in cleft patients: a retrospective analysis. *Plast Reconstr Surg* 2017;140:362–8.
- [35] Parikakis K, Larson O, Karsten A. Minimal incision palatoplasty with or without muscle reconstruction in patients with isolated cleft palate—a cephalometric study at 5 and 10 years. *Eur J Orthod* 2018;41:420–7.
- [36] Parikakis KA, Larson O, Larson M, Karsten A. Minimal incision palatoplasty with or without muscle reconstruction in patients with isolated cleft palate: a cast and medical records analysis. *Eur J Orthod* 2018;40:504–11.
- [37] Parikakis K, Larson O, Larson M, et al. Facial growth at 5 and 10 years after Veau-Wardill-Kilner versus minimal-incision technique repair of isolated cleft palate. *Cleft Palate Craniofac J* 2018;55:79–87.
- [38] Ogata H, Sakamoto Y, Kishi K. Cleft palate repair without lateral relaxing incision. *Plast Reconstr Surg Glob Open* 2017;5:e1256.
- [39] Nguyen DC, Patel KB, Skolnick GB, et al. Progressive tightening of the levator veli palatini muscle improves velopharyngeal dysfunction in early outcomes of primary palatoplasty. *Plast Reconstr Surg* 2015;136:131–41.
- [40] Pan BS, Rapp SJ, Vu A, et al. Evolution in minimal-incision palatoplasty: surgical technique and outcomes in 67 consecutive cases. *Plast Reconstr Surg* 2014;134:102–11.
- [41] Becker M, Hansson E. Low rate of fistula formation after Sommerland palatoplasty with or without lateral incisions: an analysis of risk factors for formation of fistulas after palatoplasty. *J Plast Reconstr Aesthet Surg* 2013;66:697–703.
- [42] Nyberg J, Westberg LR, Neovius E, et al. Speech results after one-stage palatoplasty with or without muscle reconstruction for isolated cleft palate. *Cleft Palate Craniofac J* 2010;47:92–103.
- [43] Sommerlad BC. A technique for cleft palate repair. *Plast Reconstr Surg* 2003;112:1542–8.
- [44] Karsten A, Larson M, Larson O. Dental occlusion after Veau-Wardill-Kilner versus minimal incision technique repair of isolated clefts of the hard and soft palate. *Cleft Palate Craniofac J* 2003;40:504–10.
- [45] Mendoza M, Molina F, Azzolini C, et al. Minimal incision palatopharyngoplasty: a preliminary report. *Scand J Plast Reconstr Surg Hand Surg* 1994;28:199–205.
- [46] Jain A, Nimonkar P, Bhola N, et al. Does hamulotomy during palatoplasty have any effect on hearing ability in nonsyndromic cleft palate patients? A prospective, single blind, comparative study. *Scientifica (Cairo)* 2016;2016:9641303.
- [47] Sheahan P, Miller I, Sheahan JN, et al. Long-term otological outcome of hamular fracture during palatoplasty. *Otolaryngol Head Neck Surg* 2004;131:445–51.
- [48] Wes AM, Mazzaferro D, Naran S, et al. Cleft-palate repair: does hospital case-volume impact outcomes or cost? *Plast Reconstr Surg* 2018;141:1193–200.
- [49] Stotland MA, Boonipat T, Lundgren CM, et al. Universal applicability of the Furlow palatoplasty: resident as primary surgeon in a consecutive, nonselective series. *Ann Plast Surg* 2018;80:406–11.
- [50] Schoenbrunner AR, Dalle Ore CL, Lance S, et al. Effect of surgeon volume and craniofacial fellowship training on cleft palate complication rates. *Ann Plast Surg* 2017;78:S229–32.