

A rare association with suffered cardiac arrest, long QT interval, and syndactyly: Timothy syndrome (LQT-8)

Yakup Ergül, İsa Özyılmaz, Sertaç Haydın*, Alper Güzeltaş, Volkan Tuzcu¹

Clinics of Pediatric Cardiology, *Pediatric Cardiovascular Surgery, Mehmet Akif Ersoy Cardiovascular Training and Research Hospital; İstanbul-Turkey

¹Pediatric and Genetic Arrhythmia Center, İstanbul Medipol University Hospital; İstanbul-Turkey

Introduction

Timothy syndrome (TS), also referred to as syndactyly-associated long QT syndrome (LQTS) or LQT8, is a multi-system disorder characterized by developmental defects causing dysmorphic facial features, congenital heart abnormalities, neurocognitive impairment, and webbing of the toes and fingers (syndactyly) (1). TS is caused by mutations of the CACNA1C gene, which encodes L-type calcium channel Ca (V) 1.2. Two types of TS have been defined according to the mutation sites: G406R in exon 8A (TS1) and G402S/G406R in exon 8 (TS2). These gain-of-function mutations result in an impaired open-state and voltage-dependent inactivation of the L-type calcium channel, ultimately

leading to a markedly prolonged myocardial action potential (delayed ventricular repolarization) (1-4).

This paper presents a two-and-a-half-year-old female patient who had cardiac arrest (CA) during an operation for inguinal hernia (IH) and syndactyly upon which short-term resuscitation was performed. The diagnosis of TS was established on the basis of the electrocardiography (ECG)-Holter findings [long QTc (corrected QT) (>600 ms), 2:1 AV block (AVB), and T-wave alternans (TWA)] and typical clinical features, and it was confirmed by molecular genetic analysis (MGA). An epicardial dual-chamber implantable cardioverter defibrillator (EDCICD) was implanted in the patient, and treatment with propranolol was initiated. To the best of our knowledge, this is the first report from Turkey about TS.

Case Report

The female patient at the age of two-and-a-half years was referred to us because of the development of CA and the performance of short-term resuscitation during surgery for IH and syndactyly. According to the physical examination, her weight was 10 kg (<3.p) and height was 80 cm (<3.p). She had physical and neuro-motor development retardation. The patient had a slightly dysmorphic-looking face and syndactyly between the 4th and 5th fingers and 2nd and 3rd toes (Fig. 1). According to her cardiovascular examination, she had bradycardia; her peak heart rate was 45–50/min and blood pressure 105/60 mm Hg. She had a 2/6 systolic murmur over the mesocardiac, and her femoral pulses were bilaterally palpable. All other system examinations were unremarkable was normal, and she had an LQTc interval (QTc: 696 ms) and a 2:1 AVB, and T wave alter-

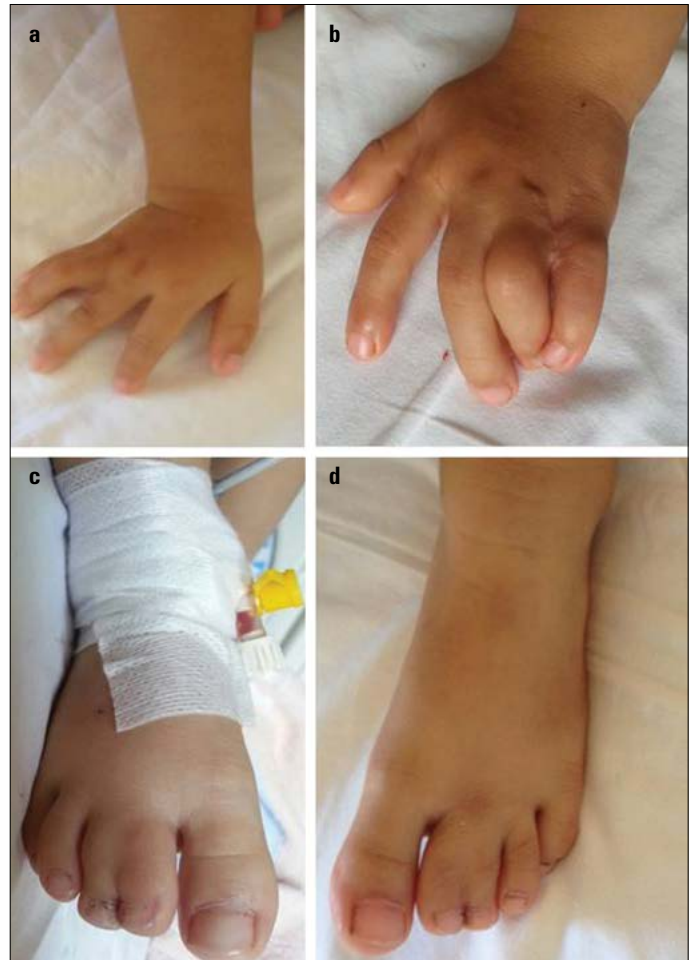

Figure 1. a-d The two-and-a-half-year-old female patient was observed to have syndactyly between her 4th and 5th fingers and 2nd and 3rd toes

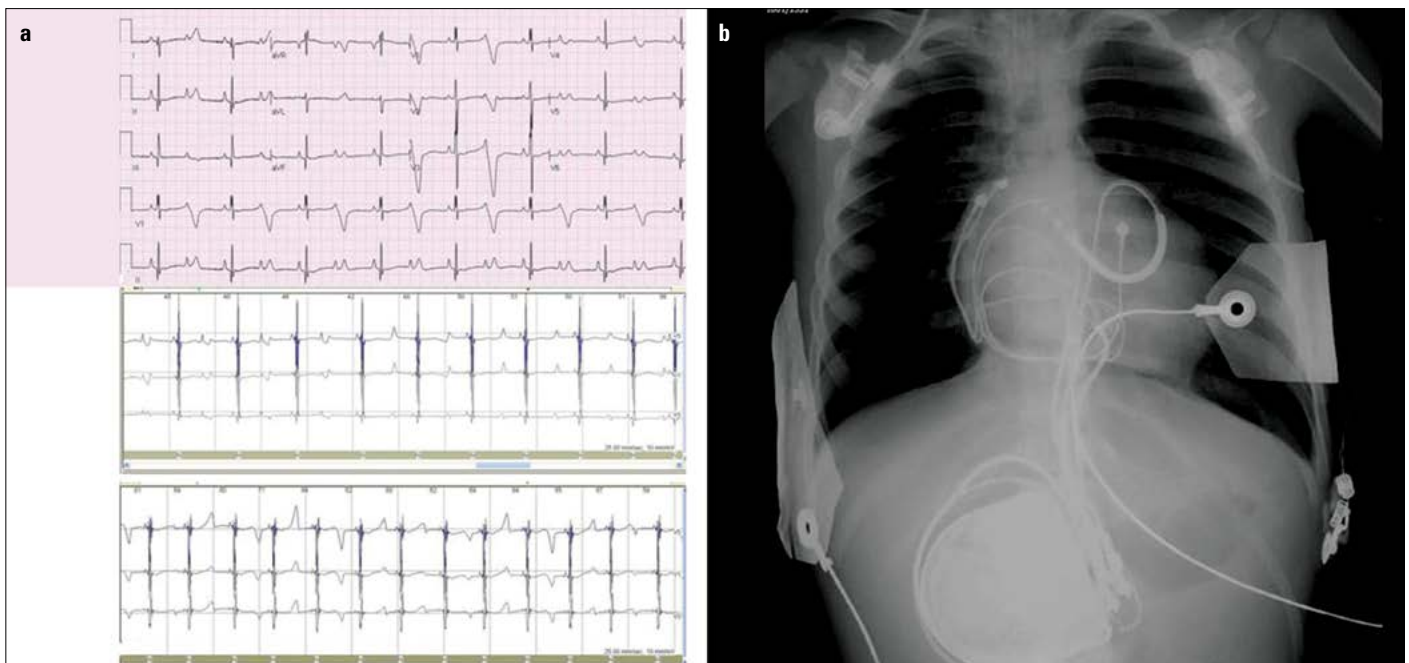


Figure 2. a, b. In the 12-lead-ECG trace of the patient, a long QTc interval (QTc 696 ms) and 2:1 AV block were observed, and Holter ECG monitoring revealed long QT and 2:1 AV block as well as T-wave alternans (a). In the X-ray image, an implanted epicardial dual-chamber ICD (b) can be seen

nans (TWA) as confirmed by 12-lead ECG and 24-h Holter ECG monitoring results (Fig. 2a). Two small mid-muscular ventricular septal defects and a small, patent ductus arteriosus in the echocardiograph were observed. The diagnosis of TS was established on the basis of the ECG and Holter findings and typical clinical features, and it was confirmed by MGA, which showed the typical G406R mutation of exon 8 of the CACNA1C (c.1216G>A) gene. Treatment with a beta-blocker (propranolol, 3 mg/kg/day) was started and EDCICD was implanted in the patient (Fig. 2b).

Discussion

Most children with TS have potentially fatal arrhythmias including 2:1 AVB, torsade de pointes, and ventricular fibrillation (1, 2, 5, 6). The number of TS cases reported in literature in English to date is below 35 (4), and our case is the first genetically diagnosed TS case reported in Turkey.

TS is one of the most severe types of LQTS, and its high mortality at a very young age is likely caused by cardiac arrhythmias precipitated by infections, severe illnesses, or anesthesia (1, 4). In our case, because of CA after anesthesia, LQTS should be considered in such cases. Because ventricular tachyarrhythmia is the leading cause of death in patients with TS, effective anti-arrhythmic medications and implantable cardioverter defibrillators (ICDs) are the mainstay of therapy. Because of the small number of patients, no validated drug therapies have been established so far. For other forms of LQTS, beta-blockers are reported to be a treatment option. The calcium channel blockers ranolazine and mexiletine have been used to prevent ventricular tachyarrhythmia (4, 5, 7, 8). Gao et al. (4) showed that mexiletine shortens QTc, attenuates QT-RR slope, and abolishes 2:1 AVB and TWA in a TS patient and TS model via the inhibition of late I_{Na} channel. TS should be considered in every patient with a confirmed diagnosis as soon as the body weight allows the procedure for primary prophylaxis of sudden cardiac death even in patients without documented ventricular tachycardia (1-5). Because the age and weight of our patient were appropriate, an epicardial ICD was implanted in addition to beta-blocker treatment.

Conclusion

The presence of bradycardia, LQT-interval, and 2:1 AVB in combination with multi-systemic signs during the newborn stage and infancy period should suggest TS. Because of the nature and poor progress of the disease, ICD implantation should be performed along with medical treatment for patients at the appropriate age and weight.

References

1. Splawski I, Timothy KW, Sharpe LM, Decher N, Kumar P, Bloise R, et al. Ca(V)1.2 calcium channel dysfunction causes a multisystem disorder including arrhythmia and autism. *Cell* 2004; 119: 19-31. [\[CrossRef\]](#)
2. Splawski I, Timothy KW, Decher N, Kumar P, Sachse FB, Beggs AH, et al. Severe arrhythmia disorder caused by cardiac L-type calcium channel mutations. *Proc Natl Acad Sci* 2005; 102: 8089-96. [\[CrossRef\]](#)
3. Yarotsky V, Gao G, Peterson BZ, Elmslie KS. The Timothy syndrome mutation of cardiac CaV1.2 (L-type) channels: multiple altered gating mechanisms and pharmacological restoration of inactivation. *J Physiol* 2009; 587: 551-65. [\[CrossRef\]](#)
4. Gao Y, Xue X, Hu D, Liu W, Yuan Y, Sun H, et al. Inhibition of late sodium current by mexiletine: a novel pharmacotherapeutic approach in Timothy syndrome. *Circ Arrhythm Electrophysiol* 2013; 6: 614-22. [\[CrossRef\]](#)
5. Krause U, Gravenhorst V, Kriebel T, Ruschewski W, Paul T. A rare association of long QT syndrome and syndactyly: Timothy syndrome (LQT 8). *Clin Res Cardiol* 2011; 100: 1123-7. [\[CrossRef\]](#)
6. Tester DJ, Ackerman MJ. Genetics of long QT syndrome. *Methodist Debakey Cardiovasc J* 2014; 10: 29-33. [\[CrossRef\]](#)
7. Jacobs A, Knight BP, McDonald KT, Burke MC. Verapamil decreases ventricular tachyarrhythmias in a patient with Timothy syndrome (LQT8). *Heart Rhythm* 2006; 3: 967-70. [\[CrossRef\]](#)
8. Sicouri S, Timothy KW, Zygmunt AC, Glass A, Goodrow RJ, Belardinelli L, et al. Cellular basis for the electrocardiographic and arrhythmic manifestations of Timothy syndrome: effects of ranolazine. *Heart Rhythm* 2007; 4: 638-47. [\[CrossRef\]](#)

Address for Correspondence: Dr. Yakup Ergül,
Mehmet Akif Ersoy Kalp Damar Eğitim ve Araştırma
Hastanesi, Padiyatrik Kardiyoloji Bölümü, Halkalı, Küçükçekmece,
İstanbul-Türkiye

Phone: +90 212 692 20 00 (Ext 4029)

Fax: +90 212 471 94 94

E-mail: yakupergul77@hotmail.com

©Copyright 2015 by Turkish Society of Cardiology - Available online at www.anatoljcardiol.com

DOI: 10.5152/AnatolJCardiol.2015.6315

