

**CASE REPORT**

# Tachycardia cycle length alternans caused by alternate conduction velocity on the slow conduction zone in a postoperative scar-related atrial tachycardia

Chen Su MD<sup>1,2</sup> | Menghui Liu MD<sup>1,2</sup>  | Yuedong Ma MD<sup>1,2</sup> | Lichun Wang MD<sup>1,2</sup> 

<sup>1</sup>Department of Cardiology, The First Affiliated Hospital, Sun Yat-Sen University, Guangzhou, People's Republic of China

<sup>2</sup>Key Laboratory on Assisted Circulation, Ministry of Health, Guangzhou, People's Republic of China

**Correspondence**

Dr. Lichun Wang, No. 58 Zhongshan 2nd RD, Guangzhou, Guangdong 510080, People's Republic of China.

Email: wanglich@mail.sysu.edu.cn

**Abstract**

The underlying mechanism for stable beat-to-beat cycle length variability (CL alternans) in scar-related atrial tachycardia (AT) had not been elucidated clearly. We described a case with postoperative dual-loop reentrant AT in right atrium. When the loop depended on cavo-tricuspid isthmus was blocked by ablation, the AT transformed into a CL alternate tachycardia. High density and resolution mapping revealed that the CL alternans was caused by the alternate conduction velocities at the slow conduct region. A further ablation line was created from the slow conduction zone to the inferior vena cave, and afterward no AT was inducible.

**KEYWORDS**

atrial tachycardia, cycle length alternans, slow conduction zone

## 1 | INTRODUCTION

Stable beat-to-beat cycle length (CL) variability (CL alternans) in scar-related atrial tachycardia (AT) was sparsely reported.<sup>1</sup> However, the underlying mechanism for the CL alternans has not been elucidated clearly. We described a case with postoperative dual-loop reentrant AT in right atrium. When the loop depended on cavo-tricuspid isthmus was blocked by ablation, the AT transformed into a CL alternate tachycardia. High density and resolution mapping revealed that the CL alternans was caused by the alternate conduction velocities at the slow conduct region in the circuit isthmus.

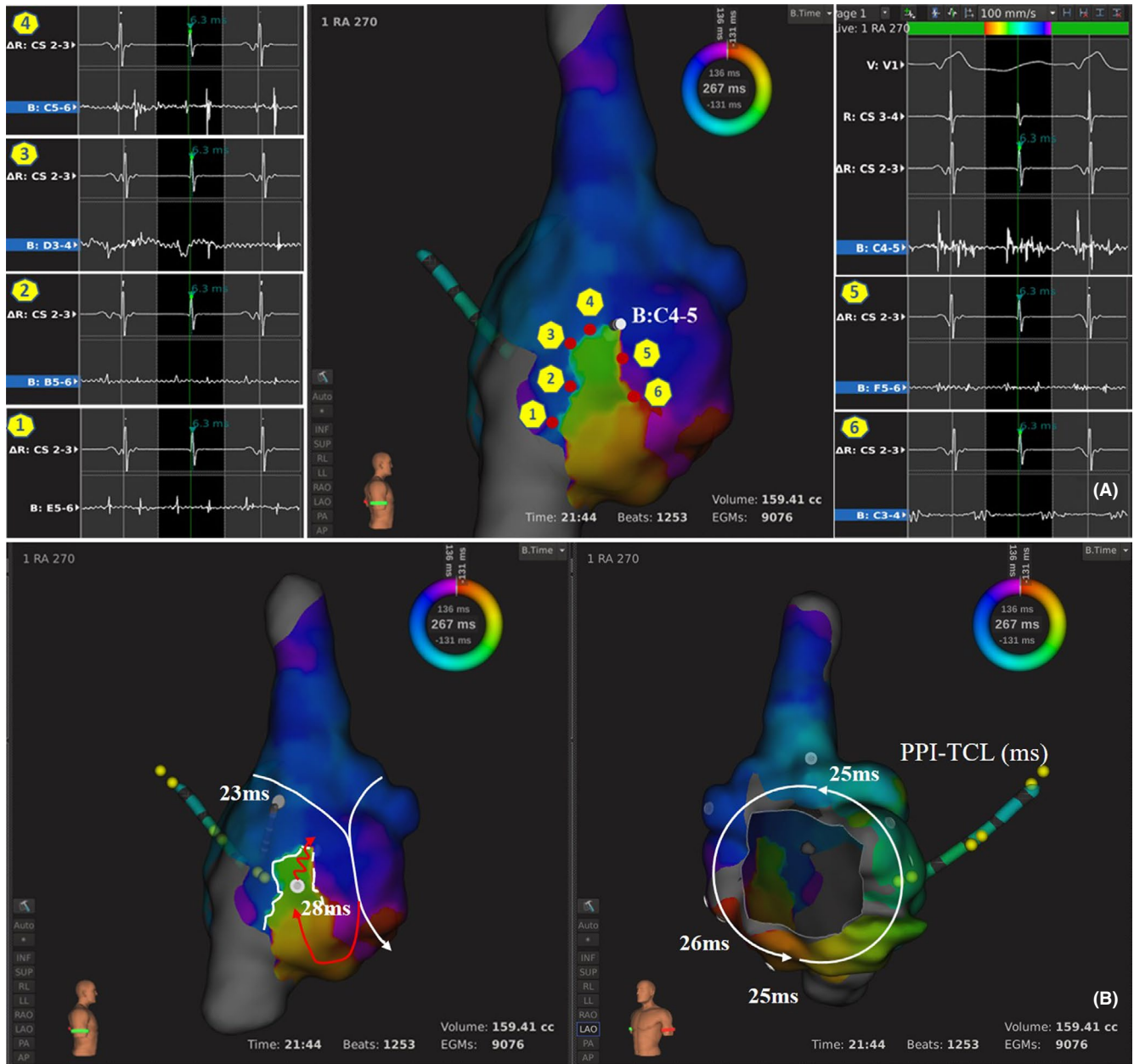
## 2 | CASE REPORT

A 45-year-old woman, who had undergone a radical correction for tetralogy of Fallot (TOF) 26 years before, presented with persistent AT for 10 years. During the electrophysiological study, the

clinical AT CL was 267 ms. Through high density and high resolution electroanatomic mapping with IntellaMap Orion basket catheter and Rhythmia™ system (Boston Scientific, MA, USA), a dual-loop reentrant AT configured figure-of-eight in right atrium was confirmed combined with pacing mapping (Figure 1). One loop (Loop 1) was a counter-clockwise cavo-tricuspid isthmus dependent circuit, the other (Loop 2) rotated in the free wall of RA through a narrow passage which was delimited by conduction block lines (double potentials) in anterior and posterior borders. The sharing pathway of the two loops (the common isthmus) was between the tricuspid annulus and the anterior block line of the narrow passage. A line ablation was first applied along the cavo-tricuspid isthmus considering the difficulty in ablating the common isthmus with successful bidirectional block. During the procedure, the activating sequence of atrium changed suddenly, which could be identified by the sharp transformation of P wave morphology. The CL of tachycardia also extended and turned into 320 ms and 280 ms alternately (Figure 2D). Although the AT was blunted terminated, remapping displayed the

This is an open access article under the terms of the Creative Commons Attribution-NonCommercial License, which permits use, distribution and reproduction in any medium, provided the original work is properly cited and is not used for commercial purposes.

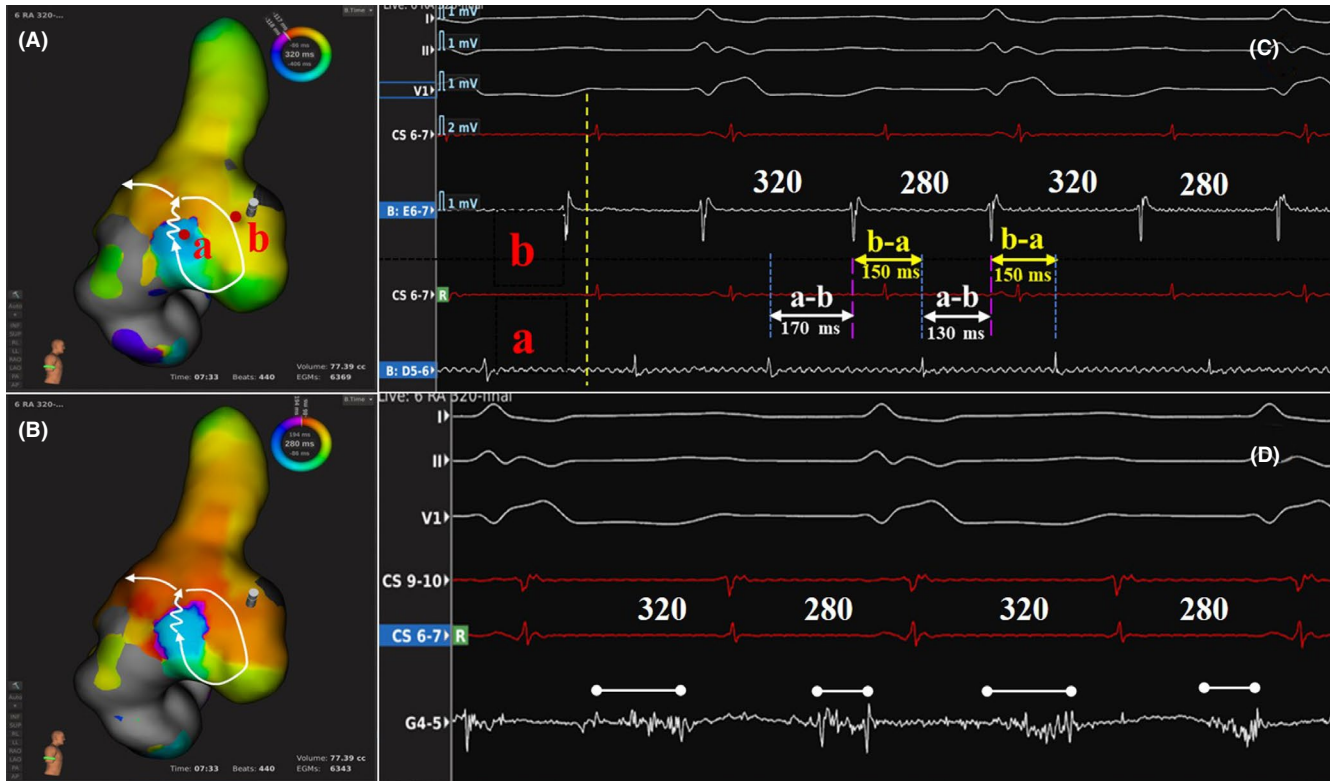
© 2019 The Authors. *Journal of Arrhythmia* published by John Wiley & Sons Australia, Ltd on behalf of the Japanese Heart Rhythm Society.



**FIGURE 1** Postoperative scar-related AT with dual-loop reentrant circuit configured figure-of-eight. A, double potentials with longer isoelectric line were showed at sites 1-5. Double potential without isoelectric line was showed at site 6. At the site the probe located (B:C4-5), a long-fractionated potential was showed. B, the white dots were the sites where the entrainment mappings were performed. The white numbers were the intervals (ms) of PPI-TCL. The PPI-TCL at the site “a” was 28 ms, similar to that at the other sites around tricuspid annulus, indicated this region was not a dead end. The long-fractionated potential site was the exit. So, the loop 2 around the incision scar was existence (red line and arrow), and the loop 1 was a counter-clockwise cavo-tricuspid isthmus dependent reentrant circuit (white line and arrow)

same reentrant circuit as the loop 2 in both 320 ms and 280 ms CL by adjusting the position of the window of interest (WOI) and setting the cycle length to 320 and 280 ms, respectively, to choose the accepted beats (Figure 2A-B). The slow conduction zone in the reentrant circuit is just located on the upper part of the narrow passage. If two points were chosen specially in the upstream (Point a) and the downstream (Point b) of the slow conduction zone, respectively, the activation propagation times from Point “b” to Point “a” were found

to be equal in the two alternate CL, but the time intervals from Point “a” to Point “b” were alternate in accordance with the CL alternation (Figure 2C). This indicated the slow conduction zone was the crucial location where the alternation occurred. Furthermore, fractionated potentials were found in the slow conduction zone, and their durations were approximate long-short alternation too. The difference of the length of fragmented potentials was nearly equal to the difference of the alternate CL. These demonstrated that the change



**FIGURE 2** Tachycardia cycle length alternans caused by alternated conduction velocity at the slow conduction zone. (A, B) the same circuit was shared at both CL 320 ms and 280 ms. The Point “a” and Point “b” in panel A were chosen in the upstream and the downstream of the slow conduction zone, respectively. C, The activation propagation times from Point “b” to Point “a” (b-a, the yellow double-headed arrows) were equal (130 ms) in the two alternate CL, but the time intervals from Point “a” to Point “b” (a-b, the white double-headed arrows) were alternate in accordance with the CL alternans. D, the long-fractionated potentials at the slow conduction zone displayed an approximate long-short alternation in accordance with the CL alternation

of conduction velocity in slow conduction zone contributed to the change of CL (Figure 2D). Therefore, a further ablation line was created from the slow conduction zone to the inferior vena cava (IVC) along the anterior border of the narrow passage. Afterward no AT was inducible and the patient has been free from AT for 13 months.

### 3 | DISCUSSION

Atrial tachycardia related to the open-heart surgery was complex and often had multiple loops.<sup>2</sup> Mapping sometimes was challenged. In this case, the high density and resolution mapping system successfully visualized the precise reentrant circuits of a dual-loop AT with a figure-eight configuration, and the circuits were further confirmed by entrainment mapping.

Although reentrant tachycardia usually exhibited stable CL, its variability also could be seen sometimes, especially in complicated tachycardia. Recently Takigawa et al found 16.7% cases had CL variability in their multiple-loop AT group, and this CL variability was more frequently observed in nonanatomic macroreentrant ATs.<sup>3</sup> As for stable beat-to-beat CL alternation, three cases were observed by Anter et al in their 24 recurrent scar-related ATs, and all of them showed dual-loop reentries with

figure-of-eight configuration.<sup>1</sup> However, the underlying mechanism for the CL alternans was not described in these reports. In our case, first a figure-of-eight dual-loop reentrant AT was mapped in RA. At this time, the tachycardia CL was stable. When cavo-tricuspid isthmus dependent reentrant loop (loop 1) was blocked, the AT abruptly altered and only took a reentry in the RA free wall (loop 2), which was so-called a nonanatomic macroreentrant AT as defined by Takigawa, and manifested an extended and alternate CL. Further in this CL alternate AT, high density and resolution mapping showed that both the long and the short CL reentries shared the same circuits with a slow conduction zone located on the upper part of the narrow passage. Comparing the activation propagation across and beyond the slow conduction zone, we found the tachycardia CL alternation was determined by the fast-slow alternans of the conduction velocity across the slow conduction zone. In addition, the long-short alternate fractionated potentials recorded in the slow conduction zone further confirmed the above conclusion. Of course, the distinct recording of alternate fractionated potentials probably attributed to the small-spacing and mini-electrodes of IntellaMap Orion catheter (Boston Scientific, MA, USA), because accumulative evidences showed small and close-spacing electrodes could improve mapping resolution.<sup>4,5</sup>

## 4 | CONCLUSION

This case demonstrated the tachycardia CL alternans could be caused by fast-slow alternate conduction velocity in the slow conduction zone of reentrant circuit.

## CONFLICT OF INTEREST

The authors declare no conflict of interests for this article.

## ETHICS AND CONSENT STATEMENT

Ethical permission was unnecessary and the patient consent obtained.

## ORCID

Menghui Liu  <https://orcid.org/0000-0001-6021-4447>

Lichun Wang  <https://orcid.org/0000-0002-9757-3256>

## REFERENCES

1. Anter E, McElderry TH, Contreras-Valdes FM, Li J, Tung P, Leshem E, et al. Evaluation of a novel high-resolution mapping technology for

ablation of recurrent scar-related atrial tachycardias. *Heart Rhythm*. 2016;13(10):2048–55.

2. Yang JD, Sun Q, Guo XG, Zhou GB, Liu X, Luo B, et al. Right atrial dual-loop reentrant tachycardia after cardiac surgery: prevalence, electrophysiological characteristics, and ablation outcomes. *Heart Rhythm*. 2018;15(8):1148–57.
3. Takigawa M, Derval N, Maury P, Martin R, Denis A, Miyazaki S, et al. Comprehensive multicenter study of the common isthmus in post-atrial fibrillation ablation multiple-loop atrial tachycardia. *Circ Arrhythm Electrophysiol*. 2018;11(6):e6019.
4. Anter E, Tschabrunn CM, Josephson ME. High-resolution mapping of scar-related atrial arrhythmias using smaller electrodes with closer interelectrode spacing. *Circ Arrhythm Electrophysiol*. 2015;8(3):537–45.
5. Josephson ME, Anter E. Substrate mapping for ventricular tachycardia: assumptions and misconceptions. *JACC Clin Electrophysiol*. 2015;1(5):341–52.

**How to cite this article:** Su C, Liu M, Ma Y, Wang L. Tachycardia cycle length alternans caused by alternate conduction velocity on the slow conduction zone in a postoperative scar-related atrial tachycardia. *J Arrhythmia*. 2019;35:558–561. <https://doi.org/10.1002/joa3.12177>