

Management of life-threatening flecainide overdose: A case report and review of the literature



Nancy M. Vu, MD,^{*} Terence E. Hill, MD,[†] Matthew R. Summers, MD,[†] Michael N. Vranian, MD,[†] Michael D. Faulx, MD[†]

From the ^{*}Internal Medicine Institute, and [†]Heart and Vascular Institute, Cleveland Clinic, Cleveland, Ohio.

Introduction

Anti-arrhythmic drug therapy carries an understood risk for toxic side effects, even at therapeutic doses. In cases of high dose ingestion these toxic effects can present rapidly with extra-cardiac symptoms, malignant arrhythmias and life-threatening hemodynamic deterioration. Prescribing clinicians should maintain familiarity with the mechanisms and kinetics of the anti-arrhythmic drugs they prescribe, as well as the clinical manifestations of anti-arrhythmic drug toxicity. Here we present a case of intentional flecainide overdose complicated by amphetamine co-ingestion. We hope this case illustrates the importance of prompt symptom recognition, mechanism-directed medical management and the utility of short term mechanical hemodynamic support in the management of anti-arrhythmic drug toxicity.

Case Presentation

A 23-year-old man with a medical history of symptomatic premature atrial complexes and paroxysmal atrial tachycardia, bicuspid aortic valve without significant stenosis or regurgitation, and severe depression with several prior suicide attempts presented to an outside hospital emergency department after ingesting a large but unknown quantity of dextroamphetamine-amphetamine and flecainide pills. An electrocardiogram (ECG) obtained 1 month prior to presentation was normal. An echocardiogram performed at that time revealed normal biventricular systolic function.

He was initially conscious but later became unresponsive. He was noted to be in a persistent wide complex rhythm (Figure 1) that quickly degenerated to pulseless ventricular tachycardia and ventricular fibrillation requiring resuscitation and multiple defibrillations. After return of spontaneous circulation, he was intubated, started on a sodium bicarbonate infusion, and transferred to our coronary intensive care unit. Urine toxicology results were positive for cannabinoids,

amphetamines, and benzodiazepines. Results of a laboratory examination were significant for an elevated lactate concentration at 4.6 mmol/L, preserved renal function, and mildly elevated hepatic transaminases. His condition was initially managed with oral gastric-tube suctioning, high-dose hypertonic sodium bicarbonate, aggressive potassium and magnesium supplementation, hyperventilation to maintain a relative alkalotic state, and intravenous lipid emulsion. Although his QRS transiently narrowed with this management, he later developed progressive QRS widening (Figure 2) and recurrent hemodynamically unstable episodes of ventricular tachycardia that were refractory to intravenous amiodarone and lidocaine infusions and required progressive vasopressor support. Transvenous pacing at rates above his slow ventricular tachycardia was attempted, but his hemodynamics worsened. Given his continued clinical deterioration despite multiple and varied attempts to medically manage his overdose, we opted to pursue mechanical circulatory support with percutaneous venoarterial extracorporeal membrane oxygenation (ECMO), which was initiated approximately 8 hours after initial presentation.

Access for ECMO was obtained via the femoral artery and vein. Femoral arteriography prior to ECMO placement revealed small-caliber arteries, likely secondary to profound vasoconstriction, which restricted cannula size and subsequent flow rates. Cannulation and ECMO initiation were otherwise uncomplicated. His echocardiogram following ECMO initiation demonstrated severely reduced biventricular function and profound ventricular dyssynchrony (Video 1). He endured several hemodynamically significant wide complex rhythms necessitating repeat cardioversion though systemic perfusion was maintained via ECMO. By hospital day 3, he maintained normal sinus rhythm with narrowing of his QRS despite a persistently elevated flecainide level at 2.00 $\mu\text{g}/\text{mL}$ (therapeutic range 0.20–1.00 $\mu\text{g}/\text{mL}$). His renal function remained unaffected throughout his admission and his transaminase levels improved. He tolerated an ECMO turnaround and was decannulated on hospital day 5. Shortly afterward, he was extubated and transferred to the regular nursing floor. His remaining hospital course was complicated by health care-associated pneumonia, and he was discharged home on hospital day 12. Flecainide was not

KEYWORDS Flecainide; Overdose (Heart Rhythm Case Reports 2016;2:228–231)

Address reprint requests and correspondence: Dr Michael D. Faulx, Cleveland Clinic Main Campus, Mail Code J2-4, 9500 Euclid Avenue, Cleveland, OH 44195. E-mail address: faulxm@ccf.org.

KEY TEACHING POINTS

- Lethal consequences of flecainide overdose may be more likely with coingestion of amphetamines secondary to pharmacodynamics and pharmacokinetic interactions.
- High-dose hypertonic sodium bicarbonate is the mainstay of medical therapy of flecainide overdose and should be dosed aggressively (initial 50–100 mEq bolus with subsequent therapy to get pH > 7.5 and sodium concentration > 150 mEq/L).
- Mechanical circulatory support should be given early consideration in cases of coingestion of medications that may potentiate the cardiotoxic effects of flecainide, such as amphetamines.

restarted on discharge, and he subsequently underwent a successful atrial tachycardia ablation. His echocardiogram prior to discharge showed a return to normal biventricular function, and his ECG also normalized (Figure 3).

Discussion

Flecainide is a Vaughan Williams class IC lipophilic antiarrhythmic agent indicated for patients with supraventricular arrhythmias without evidence of ischemic or structural heart disease. Flecainide exerts its action by delaying phase 0 depolarization through its high-affinity binding for open-state sodium channels. Physiologically, this results in a slowing of conduction in the atria, ventricles, and His-

Purkinje system along with an increased refractory period in ventricular tissue.¹ The sodium channel–blocking properties of flecainide are use-dependent in that the effects are potentiated by increasing heart rate.

Flecainide is known to have proarrhythmic potential even at usual doses, particularly in patients with underlying coronary artery disease or structural heart disease.² Bradycardias and QRS widening result from slowing of conduction in the atrial and ventricular myocytes as well as the His-Purkinje fibers in a dose-dependent fashion. Additionally, tachyarrhythmias, particularly ventricular tachycardia, frequently complicate flecainide overdose, and an increased propensity toward ventricular tachycardia may even be seen at normal doses. There are limited experimental data regarding the mechanism, but it has been proposed that the cause is nonuniform conduction slowing and prolonging of the ventricular myocyte refractory period, leading to the development of reentrant circuits.^{3,4}

Flecainide toxicity is rare but potentially fatal, with a mortality rate upward of 10%.⁵ Symptoms of toxicity include noncardiac manifestations, such as nausea, vomiting, and seizures, as well as cardiac manifestations, including bradycardia, widening of the QRS complex, and ventricular tachyarrhythmia.⁵ The management strategy for flecainide toxicity has been studied only through case reports, and successful management can be extremely challenging given its high oral bioavailability (approximately 90%) and slow rate of elimination. Flecainide is not effectively dialyzed, likely because of its large volume of distribution. The mainstay of medical therapy has been the use of high-dose sodium bicarbonate to offset the cardiotoxic effects of the drug by inducing a high-dose sodium load along with serum

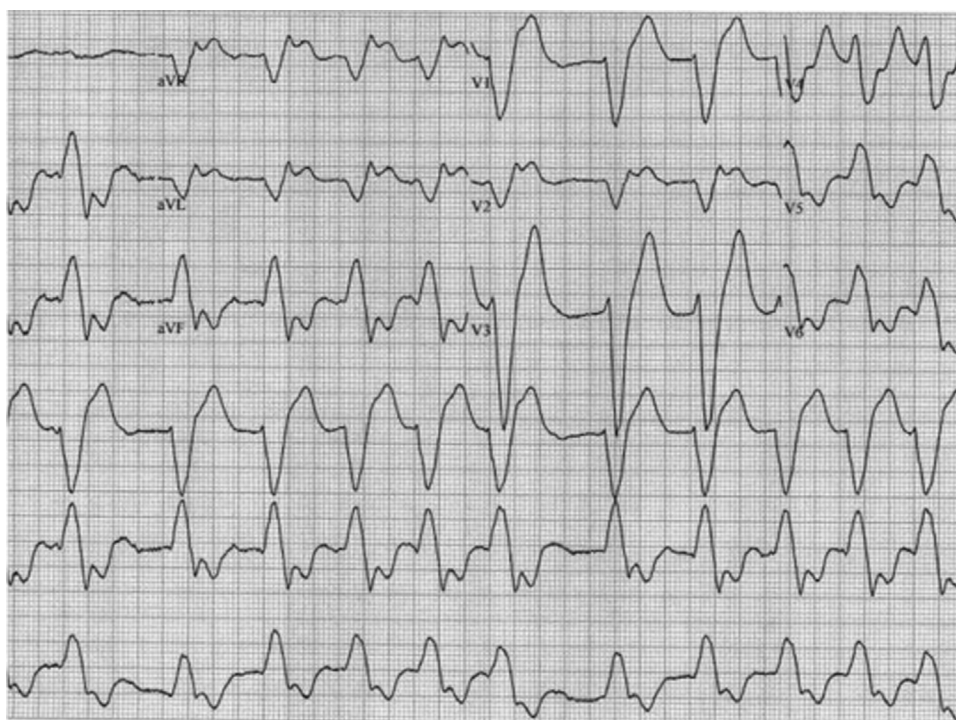


Figure 1. Electrocardiogram obtained upon arrival to the outside hospital emergency department.

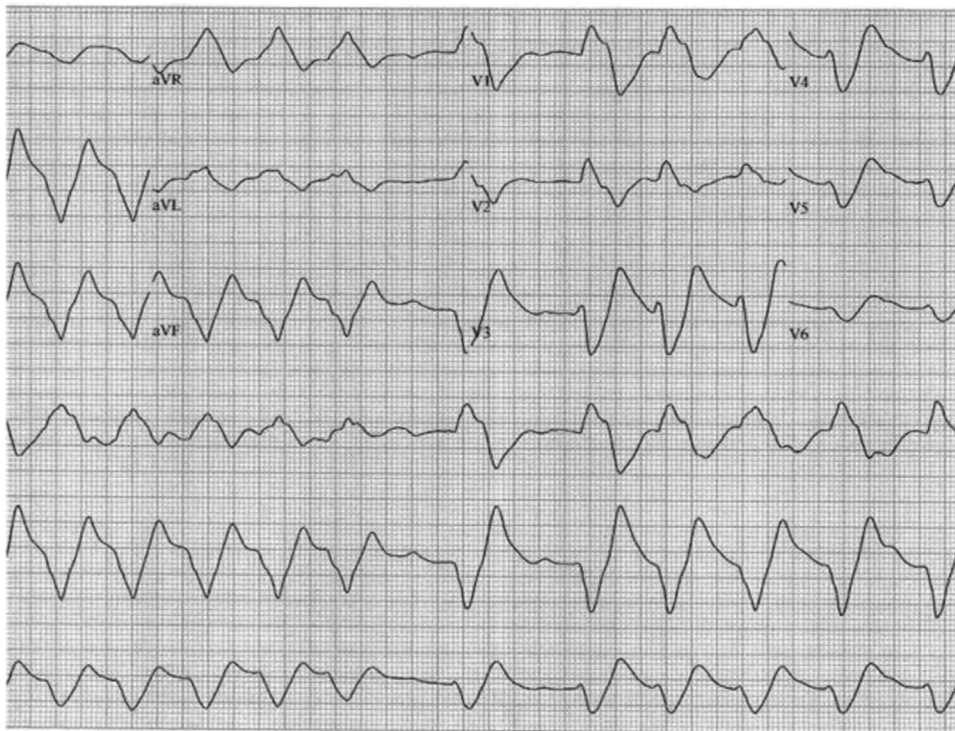


Figure 2. Electrocardiogram obtained after attempted medical management and prior to the initiation of venoarterial extracorporeal membrane oxygenation (ECMO).

alkalinization. This therapy alone has been shown to rescue patients from even life-threatening overdose.⁶

Though the molecular mechanism underlying drug pH and drug-sodium concentration is not completely understood, increases in both sodium ion concentration and pH

have been shown to reverse the flecainide effect in canine Purkinje fibers. This phenomenon is thought to be mediated by competitive inhibition and electrostatic repulsion preventing flecainide binding. Alkalinization also facilitates flecainide dissociation from the sodium channel-binding site.^{7,8}

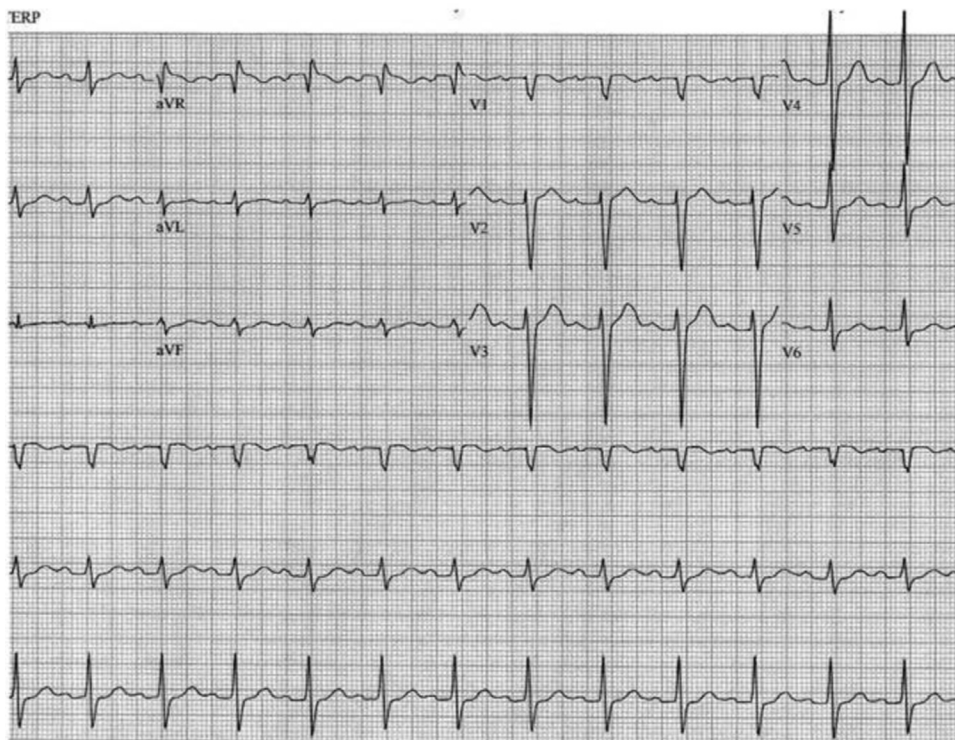


Figure 3. Electrocardiogram obtained prior to hospital discharge.

Additional medical therapy that has been used for flecainide overdose has included antiarrhythmics, intravenous fat emulsion, and transvenous or transcutaneous pacing to treat cardiac arrhythmias.^{9–12} Amiodarone and lidocaine have been reported as effective, though the mechanism is not entirely clear.^{10,11} Overdrive pacing has not been effective in suppressing tachyarrhythmias, likely because of the use-dependent properties of the drug, though pacing is effective in treating significant bradyarrhythmia.^{9,13} Success has been reported with intravenous fat emulsion, which is thought to sequester the lipophilic drug and decrease the amount of drug available to the sodium channel receptors.¹²

Mechanical circulatory support with ECMO has been previously reported in cases of life-threatening flecainide toxicity after the failure of medical therapy.^{9,14} ECMO is the preferred method of mechanical support in this type of toxicity as its function is not dependent on a perfusing cardiac rhythm and it provides biventricular support. The maintenance of hepatic and renal perfusion (and therefore function) also helps to hasten elimination of the drug.

Notably, our patient's case was complicated by coingestion of dextroamphetamine-amphetamine, which may have contributed to the severity of his presentation. Amphetamine toxicity is known to cause β -adrenergic receptor stimulation and can cause cardiac tachyarrhythmia. Polypharmacy ingestion is commonly encountered in suicide attempts, especially in young U.S. adults, for whom poisoning is among the most common modes of suicide attempt.¹⁵ Therapy frequently must address multiple toxicities in these cases. Given the presentation of our patient with a wide complex rhythm in the absence of the typical neurologic signs of amphetamine toxicity, we concluded that flecainide was the primary driver for his clinical instability, and the patient was treated accordingly.

Conclusion

Flecainide overdose may cause potentially fatal arrhythmia, myocardial depression, and ventricular dyssynchrony. Hypertonic sodium bicarbonate is the mainstay of medical therapy, though there may be a role for other antiarrhythmics and intravenous fat emulsion. In the failure of initial medical

therapy, consideration should be given to the early use of venoarterial ECMO, which can provide life-saving hemodynamic support and promote natural drug clearance.

Appendix Supplementary data

Supplementary data associated with this article can be found in the online version at <http://dx.doi.org/10.1016/j.hrcr.2015.12.013>.

References

1. Roden DM, Woosley RL. Drug therapy. Flecainide. *N Engl J Med* 1986;315(1):36–41.
2. Ruskin JN. The cardiac arrhythmia suppression trial (CAST). *N Engl J Med* 1989;321(6):386–388.
3. Brugada J, Boersma L, Kirchhof C, Alessie M. Proarrhythmic effects of flecainide. Experimental evidence for increased susceptibility to reentrant arrhythmias. *Circulation* 1991;84(4):1808–1818.
4. Di Grande A, Giuffrida C, Narbone G, Le Moli C, Nigro F, Di Mauro A, Pirrone G, Tabita V, Alongi B. Management of sodium-channel blocker poisoning: the role of hypertonic sodium salts. *Eur Rev Med Pharmacol Sci* 2010;14(1):25–30.
5. Koppel C, Oberdisse U, Heinemeyer G. Clinical course and outcome in class IC antiarrhythmic overdose. *J Toxicol Clin Toxicol* 1990;28(4):433–444.
6. Devin R, Garrett P, Anstey C. Managing cardiovascular collapse in severe flecainide overdose without recourse to extracorporeal therapy. *Emerg Med Australas* 2007;19(2):155–159.
7. Bou-Abboud E, Nattel S. Relative role of alkalosis and sodium ions in reversal of class I antiarrhythmic drug-induced sodium channel blockade by sodium bicarbonate. *Circulation* 1996;94(8):1954–1961.
8. Barber MJ, Wendt DJ, Starmer CF, Grant AO. Blockade of cardiac sodium channels. Competition between the permeant ion and antiarrhythmic drugs. *J Clin Invest* 1992;90(2):368–381.
9. Auzinger GM, Scheinkestel CD. Successful extracorporeal life support in a case of severe flecainide intoxication. *Crit Care Med* 2001;29(4):887–890.
10. Wynn J, Fingerhood M, Keefe D, Maza S, Miura D, Somberg JC. Refractory ventricular tachycardia with flecainide. *Am Heart J* 1986;112(1):174–175.
11. Siegers A, Board P. Amiodarone used in successful resuscitation after near-fatal flecainide overdose. *Resuscitation* 2002;53(1):105–108.
12. Ellsworth H, Stellpflug SJ, Cole JB, Dolan JA, Harris CR. A life-threatening flecainide overdose treated with intravenous fat emulsion. *Pacing Clin Electrophysiol* 2013;36(3):e87–e89.
13. Lloyd T, Zimmerman J, Griffin GD. Irreversible third-degree heart block and pacemaker implant in a case of flecainide toxicity. *Am J Emerg Med* 2013;31(9):1418.e1–1418.e2.
14. Brumfield E, Bernard KR, Kabrhel C. Life-threatening flecainide overdose treated with intralipid and extracorporeal membrane oxygenation. *Am J Emerg Med* 2015;33(12):1840.e3–1840.e5.
15. Nock MK, Borges G, Bromet EJ, Cha CB, Kessler RC, Lee S. Suicide and suicidal behavior. *Epidemiol Rev* 2008;30:133–154.