



Strangulated ileus from barbed suture following robot-assisted radical cystectomy: A case report

Shugo Yajima, Yasukazu Nakanishi^{*}, Shunya Matsumoto, Naoya Ookubo, Kenji Tanabe, Hitoshi Masuda

National Cancer Center Hospital East, Chiba, Japan

ARTICLE INFO

Keywords:

Barbed suture
Robot-assisted radical cystectomy
Small bowel obstruction
V-loc™

ABSTRACT

The barbed suture e.g. V-Loc™, are occasionally used in urological surgery due to the practical advantage of omitting the need for surgical knots and reducing surgical time.

In this report, an 83-year-old man diagnosed as having invasive bladder cancer underwent robot-assisted radical cystectomy: on the thirteenth postoperative day, he was diagnosed as having strangulated ileus of the small bowel. The small bowel was strangulated by bands formed between the stump of V-Loc™ and the fatty appendices of the sigmoid colon.

This is the first report of a small bowel ileus associated with the barbed suture in the field of urology.

1. Introduction

Radical cystectomy is a standard treatment for patients with multiple, recurrent, and muscle-invasive bladder cancer (MIBC), and robot-assisted radical cystectomy (RARC) with urinary diversion has recently been explored as a viable surgical option.

In the procedure of RARC, the V-Loc™ (Covidien, Mansfield, MA, USA) suture is sometimes used for stitching and division of the prostatic venous plexus. The V-Loc™ suture is composed of monofilaments with small barbs cut into the length of the surface, which self-fix to the tissue: this self-anchoring capacity eliminates the need for surgical knots and facilitates laparoscopic surgery by reducing the operative time.¹

However, a potential disadvantage of this practice and the use of such suture material is that the exposed suture barbs may catch on the adjacent small bowel, mesentery, or omentum leading to serosa injury, obstruction, or volvulus: there are several case reports of postoperative small bowel obstruction (SBO) related to the V-Loc™ after transabdominal preperitoneal laparoscopic hernia repair (TAPP)² and myomectomy.³

Although barbed sutures are frequently used in urological surgery, bowel complications associated with their use were seldom reported. Here we report a rare case of entrapment fatty appendices of the sigmoid colon and strangulated ileus of the small bowel following the use of

barbed suture in RARC.

2. Case

An 83-year-old Japanese male diagnosed as having MIBC underwent RARC with intracorporeal ileal conduit using a Da Vinci Xi surgical system (Intuitive Surgical Inc., Sunnyvale, CA, USA), after four courses of neoadjuvant chemotherapy with cisplatin and gemcitabine. An estimated 250 ml of blood was lost during the surgical procedures; the total operative time was 353 minutes. We used a 3-0 V-Loc™ suture to stitch and divide the prostatic venous plexus (Fig. 1).

On the fourth postoperative day, he began to consume a liquid diet. On the thirteenth postoperative day, the patient suddenly developed lower abdominal pain and distension with associated vomiting and intolerance of feed. Laboratory investigation demonstrated hemoglobin of 11.4 g/dL, white blood cell count of 13,000/μL, blood lactate concentration of 1.4 mmol/L, and C-reactive protein of 0.46 mg/dL. Computed tomography of the abdomen and pelvis showed dilatation of the small bowel and closed-loop findings (Fig. 2). He was suspected of having strangulated ileus. Therefore, exploratory laparoscopy was performed by a gastrointestinal surgeon under general anesthesia. A 12-mm port was placed in the umbilical region and two 5-mm ports were placed in the right and left lower quadrant of the abdomen.

Abbreviations: MIBC, muscle-invasive bladder cancer; RARC, robot-assisted radical cystectomy; SBO, small bowel obstruction; TAPP, transabdominal preperitoneal laparoscopic hernia repair.

^{*} Corresponding author. National Cancer Center Hospital East, 6-5-1 Kashiwa no ha, Kashiwa city, Chiba, 277–8577, Japan.

E-mail address: yanakani@east.ncc.go.jp (Y. Nakanishi).

<https://doi.org/10.1016/j.eucr.2021.101916>

Received 27 September 2021; Accepted 22 October 2021

Available online 22 October 2021

2214-4420/© 2021 The Authors.

Published by Elsevier Inc.

This is an open access article under the CC BY-NC-ND license

(<http://creativecommons.org/licenses/by-nc-nd/4.0/>).

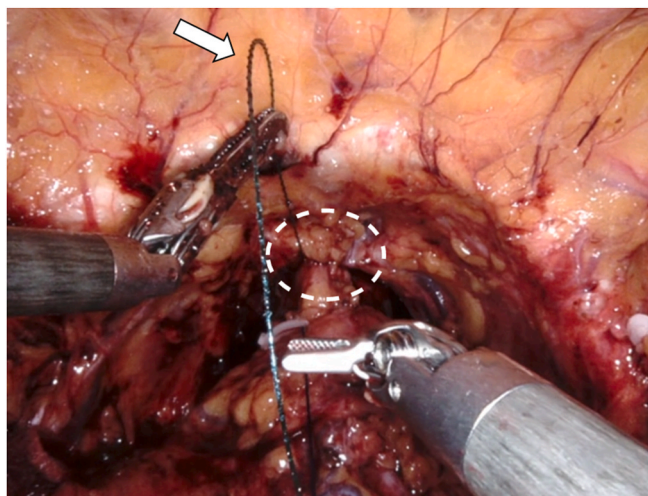


Fig. 1. The prostatic venous plexus (circle with white broken lines) was stitched using a 3-0 V-Loc™ suture (white arrow).

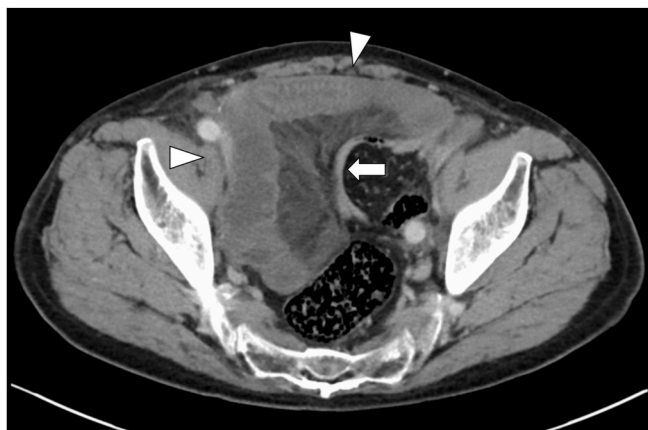

Fig. 2. Computed tomography of the pelvis showed dilatation of the small bowel (white arrowhead) and decompressed distal bowel (white arrow).

The laparoscopic observation indicated that the small bowel was strangulated by bands formed by fatty appendices of the sigmoid colon (Fig. 3a). When the bands formed by the fatty appendices of the sigmoid colon were resected, the V-Loc™ came out from inside (Fig. 3b). The

strangulated small bowel appeared dark and congested initially, and even after releasing the strangulation, the bowel did not regain its normal color (Fig. 3c). We resected the small bowel in the congested area and performed functional end-to-end anastomosis using the linear stapler. An estimated 85 ml of blood was lost during the surgical procedures; the total operative time was 69 minutes.

The patient presented a satisfactory postoperative course: clear liquids were offered on the first postoperative day, the patient resumed food intake on the fourth postoperative day, and a significant reduction of the levels of white blood cells was progressively observed.

3. Discussion

The barbed suture was first patented for use in surgical procedures in 1999, and the barbed suture V-Loc™ have been introduced into the market in 2009.

While it has the practical advantage of eliminating the need for surgical knots and reducing surgical time, the use of barbed sutures in surgery has to be careful as it is not without risks.

One of the serious complications caused by the use of barbed suture in surgery is SBO. Kindinger et al., 2012 reported a case of small bowel entanglement and obstruction involving an unraveled V-Loc™ suture 4 weeks following a laparoscopic myomectomy: they highlighted that the bowel obstruction was likely due to the presence of barbs that had contributed to the bowel entanglement.³ Similar small bowel obstructions or volvulus complications following the use of V-Loc™ sutures have been reported in the context of gastrointestinal surgery⁴ and as complications after TAPP.² In the context of gastrointestinal surgery, SBO was caused by the V-Loc™ suture directly strangling the small bowel⁴; in the postoperative setting of TAPP, there were often cases of SBO noted secondary to the cut end V-Loc™ suture, which had become integrated into the small bowel mesenterium.²

The manufacturer of V-Loc™ sutures recommends that the suture stump include additional peritoneal tissue surrounding the closure.⁵ However, Api et al. found in a randomized controlled trial in rats in 2015 that the intraperitoneal use of barbed suture material was associated with adhesion formation and that these adhesions could not be prevented by peritonization¹; therefore, in the safe use of V-Loc™ and other barbed sutures, it may not be enough to perform peritonization, and it will be important to minimize the length of the exposed barbed suture end and avoid exposing the barbed suture in the abdominal cavity if possible.

In the field of urology, to the best of our knowledge, this is the first report of SBO associated with barbed sutures, including V-Loc™. In the current case, unlike previous reports of Vloc-related SBO, the SBO

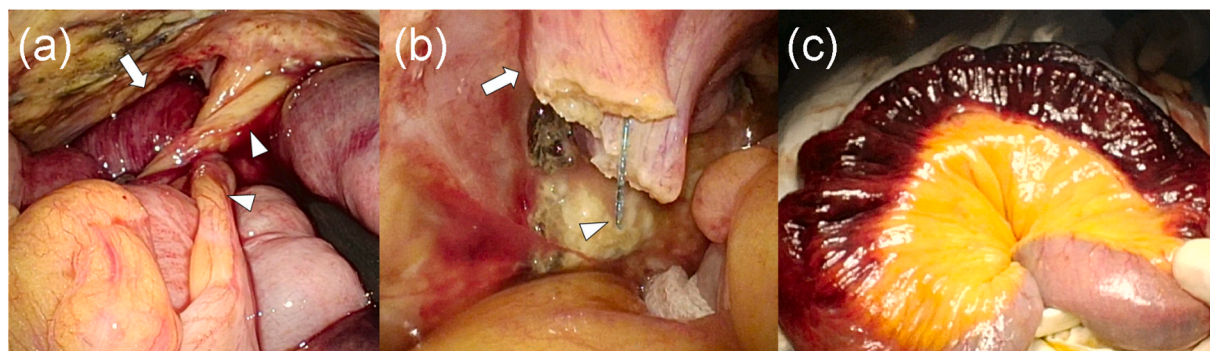


Fig. 3. Findings during the ileus repair.

(a) The small bowel (white arrow) strangulated by bands formed by fatty appendices of the sigmoid colon (white arrowhead) was reddish-black in color.

(b) The white arrow indicates dissected bands formed by the fatty appendices of the sigmoid colon. The V-Loc™ suture (white arrowhead) came out from the inside of the resected band.

(c) The small bowel appeared dark and congested even after releasing the strangulation. (For interpretation of the references to color in this figure legend, the reader is referred to the Web version of this article.)

occurred under a peculiar situation in which a band was formed through adhesions between the fatty appendices of the sigmoid colon and V-Loc™, resulting in an internal hernia. This situation is thought to have occurred because the sigmoid colon fell into the pelvic floor after radical cystectomy. That could have been prevented by minimizing the length of the exposed barbed suture end and avoiding exposure of the barbed suture in the abdominal cavity.

Financial conflict of interest

None.

Declarations of competing interest

None.

Acknowledgements

I gratefully acknowledge the members of our department.

References

1. Api M, Cikman MS, Boza A, Rabus MB, Onenerk M, Aker FV. Peritoneal closure over barbed suture to prevent adhesions: a randomized controlled trial in an animal model. *J Minim Invasive Gynecol.* 2015;22(4):619–625.
2. Tagliaferri EM, Wong Tavera SL, Abad de Jesus JL, Bergmann H, Hammans S, Seidlmayer CM. Small bowel obstruction SBO after TAPP repair caused by a self-anchoring barbed suture device for peritoneal closure: case report. *J Surg Case Rep.* 2018;(7), 2018.
3. Kindinger LM, Setchell TE, Miskry TS. Bowel obstruction due to entanglement with unidirectional barbed suture following laparoscopic myomectomy. *Gynecol Surg.* 2012;9(3):357–358.
4. Oor J, de Castro S, van Wagenveld B. V-loc™ capable of grasping surrounding tissue causes obstruction at the jejunojejunostomy after Roux-en-Y laparoscopic gastric bypass. *Asian J Endosc Surg.* 2015;8(2):209–211.
5. Filser J, Reibetanz J, Krajcinovic K, Germer C-T, Dietz UA, Seyfried F. Small bowel volvulus after transabdominal preperitoneal hernia repair due to improper use of V-Loc™ barbed absorbable wire – do we always “read the instructions first”? *International Journal of Surgery Case Reports.* 2015;8:193–195.