Case Reports in Gastroenterology

Case Rep Gastroenterol 2023;17:327–332
DOI: 10.1159/000534866
Received: March 23, 2023
Accepted: October 24, 2023
Published online: November 15, 2023



**Case Report**

# A Case of Gastric Perforation Caused by Excessive Insufflation during Upper Gastrointestinal Endoscopy: Nonoperative Management

Youn Su Park

Department of Internal Medicine, CHA Ilsan Medical Center, CHA University School of Medicine, Goyang-si, South Korea

**Keywords**
Gastric perforation · Upper gastrointestinal endoscopy · Barogenic gastric rupture · Nonoperative management

**Abstract**
***Introduction:*** Upper gastrointestinal endoscopy is used to diagnose and treat upper gastrointestinal diseases, but it can also cause complications, including perforation. Perforation is a serious complication, so it is important to be aware of the risk factors in advance and to take precautions to prevent it. ***Case Presentation:*** We report a case of gastric perforation caused by excessive insufflation during upper gastrointestinal endoscopy in a 64-year-old man with a history of multiple active gastric ulcers. During the endoscopy, the patient did not cooperate and insufflation was performed for a prolonged period of time. This led to a mucosal laceration and a hole suspected to be a perforation on the lesser curvature of the gastric body. The patient was treated nonsurgically with fasting, intravenous fluids, antibiotics, intravenous proton pump inhibitors, and blood transfusions. No leakage was observed on the follow-up computed tomography scan, and the perforation site was completely healed 2 months later. ***Conclusion:*** In this case, the patient was successfully treated with conservative therapy alone. The treatment of gastric perforation caused by endoscopy has shifted toward conservative therapy in recent years.



Correspondence to:
Youn Su Park, p5018@naver.com

Karger

## Introduction

With recent advances in upper gastrointestinal (GI) endoscopy techniques, it has become widely used worldwide for diagnosing and treating diseases of the esophagus, stomach, and duodenum. The complications of upper GI endoscopy have varying incidence rates according to the definition and investigated statistics, but are generally estimated to be between 0.13 and 0.24%, with a perforation rate of 0.03–0.1% [1, 2]. Perforation during the endoscopic procedure can cause complications such as abdominal pain and peritonitis in patients, and therefore, caution should be taken during the procedure to prevent perforation, and appropriate measures should be prepared in advance. Excessive insufflation can increase the risk of perforation, especially in patients with weakened gastric walls. In this case, the patient's age and dialysis treatment made his gastric wall more susceptible to perforation. The treatment of gastric perforation caused by endoscopy has shifted toward conservative therapy in recent years. In this article, we present a case of gastric perforation caused by excessive insufflation during upper GI endoscopy, as well as cases treated nonsurgically. The CARE Checklist has been completed by the authors for this case report, attached as online supplementary material (for all online suppl. material, see https://doi.org/10.1159/000534866).

## Case Presentation

A 64-year-old man presented to the emergency room with melena. He was undergoing dialysis three times a week and was taking aspirin 100 mg, digoxin 0.125 mg, losartan 100 mg, atorvastatin 10 mg qd for hypertension, hyperlipidemia, atrial fibrillation, and coronary artery stenosis. The patient reported symptoms of nausea and dizziness during the medical history assessment. On physical examination, the blood pressure was measured at 161/81 mm Hg, heart rate was 107 beats/min, respiratory rate was 22 breaths/min, and body temperature was 36.3°C. The patient was drowsy and showed signs of acute illness, including pale conjunctiva and dry mouth. Two years ago, he had a GI endoscopy which showed no abnormalities.

The blood test results were as follows: white blood cell count 4,730/μL, hemoglobin 6.7 g/dL, hematocrit 20.3%, platelet count 133,000/μL, aspartate aminotransferase 8 IU/L, alanine aminotransferase 19 IU/L, total bilirubin 0.33 mg/dL, alkaline phosphatase 254 IU/L, blood urea nitrogen 36.0 mg/dL, creatinine 3.69 mg/dL, C-reactive protein 0.1 mg/dL, sodium 139 mmol/L, potassium (K) 3.65 mmol/L, chloride 99 mmol/L, and bicarbonate (HCO3) 28.8 mmol/L at the time of admission.

During the upper GI endoscopy to evaluate GI bleeding, multiple active gastric ulcers were observed in the antrum (Fig. 1). While attempting a tissue biopsy, the endoscope was not cooperating and insufflation was performed for a prolonged period of time. During the scope retrieval, bleeding was observed, and a mucosal laceration and a hole suspected to be a perforation were found on the lesser curvature of the gastric body (the gastroesophageal junction was intact). Hemostasis was achieved by applying hemoclips to the exposed blood vessels (Fig. 2). No active bleeding was observed afterward, and the endoscopy was terminated to prevent further insufflation. In the abdominal computed tomography scan, pneumoperitoneum was observed within the abdominal cavity, and it was noted that free air was escaping into the abdominal cavity from around the high body area (Fig. 3a, b).

The patient was transferred to the surgical department for close observation to determine the need for surgical intervention and underwent medical treatment including fasting, fluid support, antibiotic coverage, intravenous proton pump inhibitors, and blood

Case Rep Gastroenterol 2023;17:327–332
DOI: 10.1159/000534866



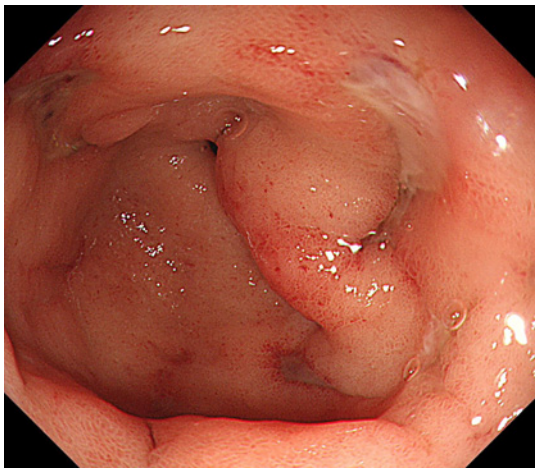

**Fig. 1.** Esophagogastroduodenoscopy (EGD) image showing multiple active gastric ulcers were observed in the antrum.

transfusions. No leakage was observed on the follow-up computed tomography scan taken during the examination with gastrografin injection through a nasogastric tube, and spontaneous closure was expected. The patient's condition improved after starting a diet the next day, and he was discharged 8 days after admission. During the endoscopy performed 2 months later, the perforation site was completely healed (Fig. 4), and the patient has been under further observation without additional bleeding.

## Discussion

This case is meaningful in that it is an important presentation about the rare cause of gastric perforation following upper GI endoscopy. During upper GI endoscopy, risk factors for perforation include the presence of anterior cervical osteophytes, Zenker's diverticulum, areas of stricture, inflammation, ischemia, tumors, and weakened mucosal areas due to caustic agents [2]. Perforation is more likely to occur during therapeutic endoscopy than diagnostic endoscopy. In addition, perforation is more likely to occur when an inexperienced endoscopist inserts the endoscope forcefully or injects too much air without proper visualization, particularly in the cervical esophagus or hypopharynx [3]. In this patient's case, he was elderly and receiving dialysis treatment, which made the gastric wall susceptible to external pressure.

Barogenic gastric rupture is a rare medical condition that occurs when the stomach ruptures due to overdistension caused by the obstruction of normal avenues for gaseous escape. This condition is more likely to occur when there is excessive air or gas in the stomach, such as after diving or cardiopulmonary resuscitation. A gastric tear typically happens on the lesser curvature of the stomach, which has less elasticity and mucosal folds, making it more prone to tearing. This tendency was observed in 73% of the cases reviewed by Albo et al. [4] and in 10 out of the 12 cases reported by Molenat and Boussuges [5]. In the case of this patient, the tear occurred on the lesser curvature due to overdistension caused by excessive air injection, as the gastroesophageal junction was intact anatomically.

GI perforation can lead to problems such as contamination and bleeding of food contents, and if pancreatic enzymes leak through the perforation site into the peritoneal cavity, it can cause damage to other organs and peritonitis. Therefore, prompt surgical treatment is usually necessary. However, in cases of perforation during GI endoscopy, the patient is in a fasting state and the risk of contamination at the perforation site is relatively low, so there is a possibility of improvement with antibiotic therapy alone without surgical treatment. The

Case Rep Gastroenterol 2023;17:327–332
DOI: 10.1159/000534866




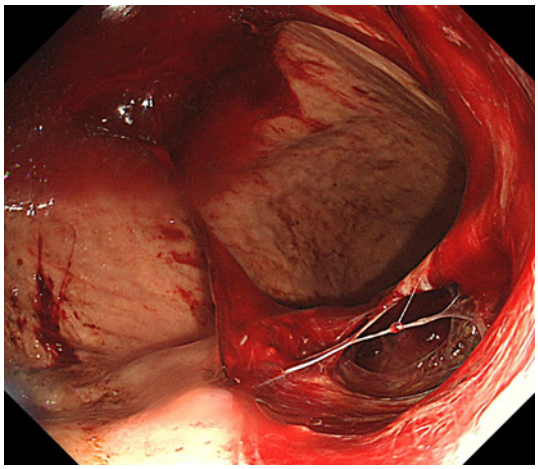

**Fig. 2.** Esophagogastroduodenoscopy (EGD) image showing a mucosal laceration and a hole suspected to be a perforation were found on the lesser curvature side of the body.

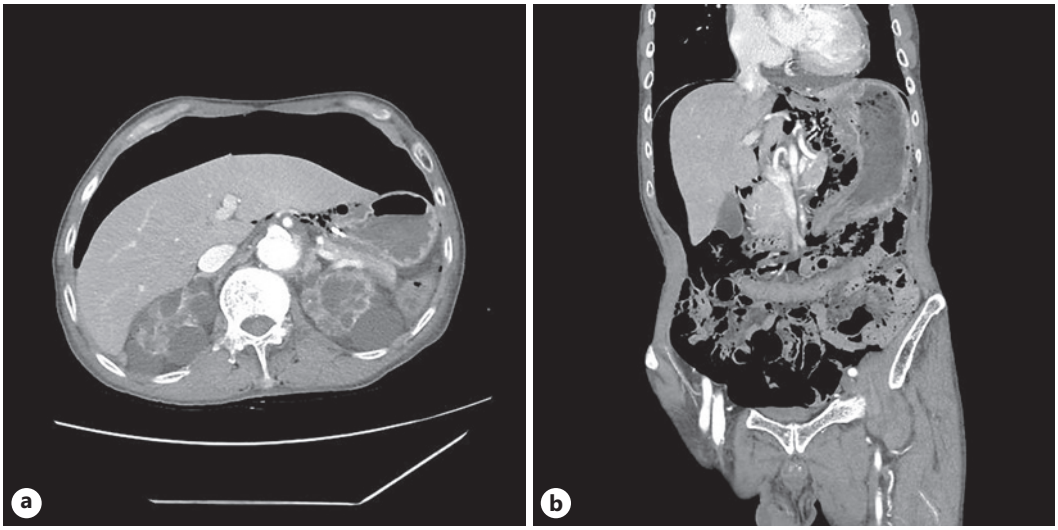


**Fig. 3.** Axial (**a**) and coronal (**b**) views of computed tomography (CT) scan show free air in the abdominal cavity. Leakage of air from the stomach is evident with both CT views.

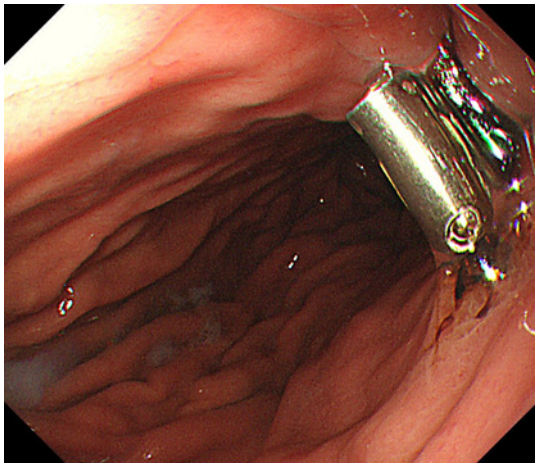

**Fig. 4.** Endoscopic finding during follow-up. Two months later, the perforation site was completely healed.

management for iatrogenic perforation, not spontaneous perforation of benign peptic ulcer disease or malignant disease, is a conservative management [6]. The treatment of GI tract perforations has shifted toward conservative therapy, replacing surgical management in many cases [7]. The European Society of Gastrointestinal Endoscopy Position Statement recommends conservative management as a first-line treatment for iatrogenic gastric perforation caused by esophagogastroduodenoscopy (EGD), if the following criteria are met: perforation is recognized late (>12 h), the presentation is asymptomatic, and there are no signs of peritoneal effusion or sepsis, thus reducing the risk of peritoneal contamination. In certain instances of gastric perforation associated with EGD, clipping during the EGD procedure or surgery may be advised, depending on the clinical presentation or the size of the perforation [8]. In this patient's case, improvement was achieved with conservative treatment alone, as there was no evidence of contrast leakage on follow-up imaging.

## Conclusion

We report a case of gastric perforation due to excessive insufflation during upper GI endoscopy that was successfully treated with nonsurgical management. The case serves as a reminder to endoscopists to exercise caution during the procedure and to prepare appropriate measures for perforation in advance.

## Statement of Ethics

Ethical approval is not required for this study in accordance with local or national guidelines. Written informed consent was obtained from the patient for publication of this case report and all accompanying images.

## Conflict of Interest Statement

The author has no conflicts of interest to declare.

## Funding Sources

The author declares that no funding was received for this study.

## Author Contributions

Youn Su Park contributed to conception, drafting, revising, and editing the article and final approval.

## Data Availability Statement

All data generated or analyzed during this study are included in this article and its online supplementary material files. Further inquiries can be directed to the corresponding author.

## References

1 Wolfsen HC, Hemminger LL, Achem SR, Loeb DS, Stark ME, Bouras EP, et al. Complications of endoscopy of the upper gastrointestinal tract: a single-center experience. Mayo Clin Proc. 2004;79(10):1264–7.
2 Eisen GM, Baron TH, Dominitz JA, Faigel DO, Goldstein JL, Johanson JF, et al. Complications of upper GI endoscopy. Gastrointest Endosc. 2002;55(7):784–93.
3 Waddingham W, Kamran U, Kumar B, Trudgill NJ, Tsiamoulos ZP, Banks M. Complications of diagnostic upper Gastrointestinal endoscopy: common and rare – recognition, assessment and management. BMJ Open Gastroenterol. 2022;9(1):e000688.
4 Albo R, DeLorimier A, Silen W. Spontaneous rupture of the stomach in the adult. Surgery. 1963;53:797–805.
5 Molenat FA, Boussuges AH. Rupture of the stomach complicating diving accidents. Undersea Hyperb Med. 1995; 22(1):87–96.
6 Weledji EP. An overview of gastroduodenal perforation. Front Surg. 2020;7:573901.
7 Goenka MK, Goenka U. Endotherapy of leaks and fistula. World J Gastrointest Endosc. 2015;7:702–13.
8 Paspatis GA, Dumonceau JM, Barthet M, Meisner S, Repici A, Saunders BP, et al. Diagnosis and management of iatrogenic endoscopic perforations: European Society of Gastrointestinal Endoscopy (ESGE) position statement. Endoscopy. 2014;46(8):693–711.