

Anesthesia in Mowat-Wilson syndrome: information on 11 Italian patients

Marianna Spunton,¹ Livia Garavelli,² Paola Cerutti Mainardi,³ Uta Emmig,⁴ Enrico Finale,¹ Andrea Guala¹

¹Department of Pediatrics, Castelli Hospital, Verbania; ²Clinical Genetics Unit, Obstetric and Pediatric Department, S. Maria Nuova Hospital, Reggio Emilia; ³Department of Pediatrics, S. Andrea Hospital, Vercelli; ⁴Department of Anesthesia, S. Biagio Hospital, Domodossola, Italy

Abstract

Mowat-Wilson syndrome is a genetic disease caused by heterozygous mutations or deletions of the *ZEB2* gene and characterized by typical clinical features. The congenital malformations typical of this syndrome call for early diagnostic and surgical procedures requiring general anesthesia, but few information about the anesthesiology management of such patients is available. We enrolled 11 families of patients with Mowat-Wilson syndrome who had undergone surgical or diagnostic procedures requiring general anesthesia, and sent them a retrospective questionnaire including 16 open questions about the procedures. They were further contacted by phone for a semi-structured interview. A total of 37 procedures requiring general anesthesia was reported in 11 patients. Only two patients reported anesthesia-related complications during the procedure. No *true* additional anesthesia-related risk was present for the patients with MW syndrome, besides difficult intubation, weaning and lower respiratory tract infection. Perception of risk, however, is derived by non-medical observation on the part of the parents.

Introduction

Mowat-Wilson syndrome (MWS; OMIM#235730) is a genetic disease caused by heterozygous mutations or deletions of the *ZEB2* gene,^{1,2} and characterized by typical face, epilepsy, moderate-to-severe mental retardation, and variable congenital malformations, including Hirschsprung disease (HSCR), agenesis of the corpus callosum (ACC), congenital heart disease (CHD), genital anomalies (particularly hypospadias in males), and eye defects.

Since the first delineation by Mowat *et al.* (1998), more than 200 patients with *ZEB2* mutations, deletions or cytogenetic abnormalities have been reported primarily from Northern Europe, Australia, Italy and the United States, and over 100 mutations have been described.³⁻¹⁷

Congenital malformations typical of this syndrome call for early diagnostic investigations and surgical resolutions; general anesthesia is required for diagnostic and surgical procedures, both in election and in emergency, but few information about anesthesiologic management is available.⁹

The aim of our study was to collect retrospective data on general anesthesia interviewing a large numbered group of Italian patients with MWS, assess the anesthesiologic outcomes and identify the conditions that required general anesthesia; aware of the fact that few clinical data would be derived from this interview

Materials and Methods

A retrospective cohort study design was performed with questionnaire was sent to the parents using the mailing list of the Italian association of the Mowat-Wilson Syndrome. Thirty six questionnaires were sent out in total and each questionnaire included 16 open questions about age, type of surgery/diagnostic test requiring general anesthesia and outcome of the procedure. Some questions relating to the perception of the families about the knowledge of the disease by the anesthesiologist were also included. All of the families who initially replied to the questionnaire by mail were then contacted by phone for an additional semistructured interview.

Furthermore a further call was necessary to obtain clinical data such as the hospital stay from the clinical documentation in the possession of the families.

Results

We have collected questionnaires from 11 patients with MWS on thirty six.

A total of 37 anesthesiologic procedures was reported in 11 patients; in all cases, anesthesia was required in relation to various type of surgery and diagnostic procedures (Table 1).

The age of surgery and diagnostic procedures is reported in Figure 1.

The more common operations were the following: gastrointestinal surgeries (27%); diagnostic investigation, mainly MRI (24,3%); cardiac surgeries (16,2%); orchiopexy/orchiectomy of a cryptorchid

Correspondence: Enrico Finale, Dipartimento Materno-Infantile, Ospedale Castelli Verbania, Via Fiume 18, 28922 Verbania (VB), Italy.
Tel. +39.0323.541333 - Fax: +39. 0323.541334
E-mail: enrico.finale@gmail.com

Key words: Mowat Wilson syndrome; general anesthesia, anesthesia-related risk.

Acknowledgements: the authors would like to thank Italian Association of the Mowat-Wilson-Syndrome.

Contributions: MS, LG, PCM, UE, EF, AG substantial contributions to the conception design of the work, the acquisition, analysis and interpretation of data; MS, LG, PCM, UE, EF, AG drafting the work and revising it critically for important intellectual content; MS, LG, PCM, UE, EF, AG final approval of the version published; MS, LG, PCM, UE, EF, AG agreement to be accountable for all aspects of the work in ensuring that questions related to the accuracy and integrity of any part of the work are appropriately investigated and resolved.

Conflict of interest: the authors declare no potential conflict of interests.

Funding: none.

Received for publication: 30 November 2017.
Revision received: 14 February 2018.
Accepted for publication: 28 February 2018

This work is licensed under a Creative Commons Attribution NonCommercial 4.0 License (CC BY-NC 4.0).

©Copyright M. Spunton *et al.*, 2018
Licensee PAGEPress, Italy
Pediatric Reports 2018; 10:7514
doi:10.4081/pr.2018.7514

testicle (13,5%); hypospadias correction (5,4%) (Figure 2). Unfortunately it was not possible to derive from the interviews the duration of the single surgical and instrumental procedures.

75.7% of families reported that the anesthesiologists were not aware of the syndrome; nevertheless, 43.2% of parents declared that they have been sufficiently reassured by the competence of the physician to trust him/her, even if we do not have data that attest to the clinical experience of anesthetists with pediatric patients.

In 78.4% of cases no complications of anesthesia emerged during the procedures (data collected from patients' perception of patients and not from clinical data). Two patients reported anesthesia-related problems: a patient had cardiac complication during one procedure and another patient had respiratory complications during two

different procedures.

Anesthesia was required for 33 elective procedures and for 4 urgent procedures. No one of the parents received a report after the procedure.

Discussion

The involvement of patients' organizations in collecting clinical data has been a strong instrument for natural history of rare diseases. The anesthetic risk is present at each procedure but particular syndromes may provide an additional risk.¹⁸ However, very little is known about the anesthetic risk of MWS. The survey through social media has advantages and disadvantages, as well summarized in a

recent article by William Davies:¹⁹ fast turnaround, low costs, a large number of patients recruited (often seen individually in different hospitals) but the evaluation of the point of view of the individuals or the caregivers, the compilation of retrospective questionnaire was on a voluntary basis and this may introduce an additional bias.

However, a similar investigation made for the MWS was done in the same manner for the Cri du Chat syndrome.²⁰

Analysis of the type of surgery allows to note that most of these are made in election, except for those made in urgency (*i.e.* digestive canal at birth), when the diagnosis of MW has not yet been made.

No true additional anesthesia-related risk was present for the patients with MW syndrome, both parents and professionals

can take comfort in knowing the real anesthesiologic risk linked to issues involving the Mowat-Wilson syndrome. It is recommended to carry out an examination of patient's cardiac function before any procedure; in case of cardiac malformation, antibiotic prophylaxis for bacterial endocarditis is required. Furthermore, in according to Deshmukt *et al.*,²¹ *the main anesthetic challenges in MW syndrome are a risk of difficult intubation and possibility of difficulty in weaning, lower respiratory tract infection and anemia.*

The recollections of the patient's parents may be biased, even if it was their choice whether or not to participate in the study, hence we can assume that their responses correspond to reality, but not as a real clinical evaluation.

Table 1. Age of surgery and diagnostic procedures in 11 Italian patients with MWs.

Patient	Age	Type of diagnostic/surgical procedure	Elective/urgent procedure	Patient's trust in the anesthesiologist	Complications	Hospital stay
PT1	3 yr	megacolon resection	elective	excellent	no	9 d
PT2	18 mo	brain MRI	elective	good	no	2 d
	3 yr	brain MRI	elective	good	no	2 d
PT3	52 d	megacolon resection	urgent	very good	no	11 d
	8 yr	undescended testicle	elective	good	no	3 d
PT4	21 d	diagnostic bronchoscopy	elective	satisfactory	no	2 d
	27 d	cardiac catheterization	elective	satisfactory	no	5 d
	29 d	vascular ring correction + PDA closure	urgent	satisfactory	no	7 d
	80 d	transanal endorectal pull-through	elective	N/A	no	11 d
PT5	3 mo	cardiac catheterization + PDA closure	elective	very good	no	6 d
	3 yr	adenotonsillectomy	elective	good	no	3 d
PT6	16 mo	cardiac catheterization	elective	very good	cardiac	5 d
	19 mo	brain MRI	elective	very good	no	2 d
PT7	1 mo	colostomy confection	elective	satisfactory	no	3 d
	6 mo	bowel resection	elective	satisfactory	no	6 d
	9 mo	colostomy reversal	elective	satisfactory	no	7 d
	30 mo	MRI	elective	satisfactory	no	2 d
	4 yr	hypospadias	elective	satisfactory	no	4 d
	5 yr	MRI	elective	satisfactory	no	2 d
	16 yr	undescended testicle removal	elective	satisfactory	no	5 d
PT8	1 mo	pulmonic valve stenosis surgery	elective	very poor	respiratory	5 d
	3 mo	pyloric stenosis	urgent	very poor	no	3 d
	1 yr	IVD closure	elective	very poor	respiratory	4 d
	7 yr	vertebral column arthrodesis	elective	very good	no	7 d
PT9	1 mo	megacolon	urgent	good	no	7 d
	6 mo	bowel resection	elective	good	no	4 d
	9 mo	colostomy reversal	elective	good	no	7 d
	4 yr	hypospadias	elective	good	no	3 d
	16 yr	undescended testicle removal	elective	good	no	4 d
	21 yr	brain MRI + urethrotomy	elective	good	no	3 d
PT10	6 mo	MRI	elective	satisfactory	no	2 d
	3 yr	MRI	elective	satisfactory	no	1 d
	3 yr	facial and hand warts excision	elective	good	no	2 d
PT11	11 mo	tear duct opening + orchidopexy	elective	satisfactory	no	5 d
	1 yr	MRI	elective	satisfactory	no	2 d
	18 mo	muscle biopsy	elective	satisfactory	no	1 d
	4 yr	testicle removal	elective	satisfactory	no	5 d

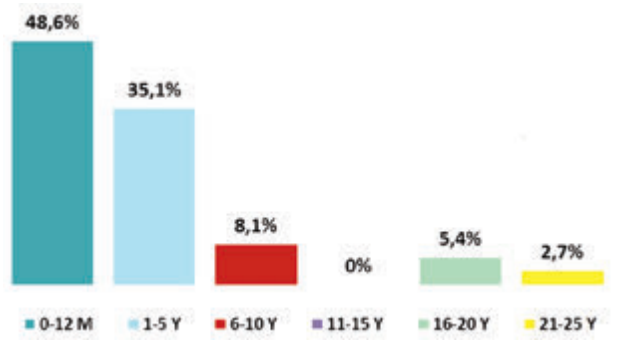


Figure 1. The age of patients as a percentage. At the time of general anesthesia, the age of patients ranged from month to 21 years.

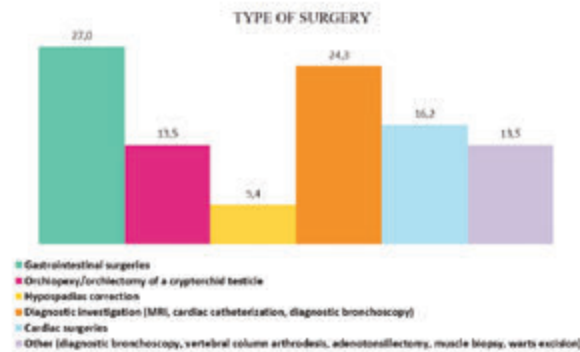


Figure 2. Type of surgery and diagnostic procedures in 11 Italian patients with MWs.

Conclusions

The study presents possible limits, such as potential bias due to the set nature of the design: a retrospective survey based on the memory of the patients' parents. Moreover, the lack of some clinical data such as the duration of surgical and instrumental procedures, ASA score, the experience of the anesthetists inherent in pediatric patients, the anesthetic technique used, do not make the present study definitive. However our perception of risk, however, is derived by non-medical observation on the part of the parents, therefore further investigations – including the analysis of the medical files of all subject – are needed to confirm our findings; a prospective study would be desirable.

References

- Adam MP, Bean LJH, Ranger Miller V. Mowat-Wilson syndrome. Genereviews www.genetests.org
- Bissonnette B, Luginbruehl I, Marciniak B, et al. Syndromes: rapid recognition and perioperative implications. McGraw-Hill, 2006.
- Cacheux V, Dastot-Le Moal F, Kääriäinen H, et al. Loss-of-function mutations in SIP1 Smad interacting protein 1 results in a syndromic Hirschsprung disease. *Hum Mol Genet* 2001;10:1503-10.
- Cerutti Mainardi P, Pastore G, Zweier C, et al. Mowat-Wilson syndrome and mutation in the zinc finger homeobox 1B gene: a well defined clinical entity *J Med Genet* 2004;41:e16.
- Dastot-Le Moal F, Wilson M, Mowat D, et al. ZFH1B mutations in patients with Mowat-Wilson syndrome. *Hum Mutat* 2007;1-9.
- Garavelli L, Donadio A, Zanacca C, et al. Hirschsprung disease, mental retardation, characteristic facial features and mutation in the gene ZFH1B (SIP1): confirmation of the Mowat-Wilson syndrome. *Am J Med Genet* 2003;116A 385-8.
- Garavelli L, Mainardi PC. Mowat-Wilson syndrome. *Orphanet J Rare Dis* 2007;2:42.
- Garavelli L, Zollino M, Mainardi PC, et al. Mowat-Wilson Syndrome: phenotype changing with age. Study of 19 Italian patients and review of the literature. *Am J Med Genet* 2009;149A:417-26.
- Kiernan F, Crowe S. Safe use of the classic laryngeal mask airway and endotracheal intubation in general anaesthesia for a patient with Mowat-Wilson syndrome. *Paediatr Anaesth* 2009;19:174-5.
- Mowat DR, Croaker GDH, Cass DT, et al. Hirschsprung disease, microcephaly, mental retardation, and characteristic facial features: delineation of a new syndrome and identification of a locus at chromosome 2q22-q23. *J Med Genet* 1998;35:617-23.
- Mowat DR, Wilson MJ, Goossens M. Mowat-Wilson syndrome *J Med Genet* 2003;40:305-10.
- Electronic Database Information: Online Mendelian Inheritance in Man (OMIM), <http://www.ncbi.nlm.nih.gov/Omim/>
- Wakamatsu N, Yasukazu Y, Kenichiro Y, et al. Mutations in SIP1, encoding Smad interacting protein-1, cause a form of Hirschsprung disease. *Nat Genet* 2001;27:369-70.
- Wilson M, Mowat D, Dastot-LeMood F. Further delineation of the phenotype associated with heterozygous mutation in ZFH1B. *Am J Med Genet* 2003;119A:257-65.
- Zweier C, Albrecht B, Mitulla B, et al. Mowat-Wilson Syndrome with and without Hirschsprung Disease is a distinct, recognizable Multiple Congenital Anomalies-Mental Retardation Syndrome caused by Mutations in the Zinc finger homeobox 1 B gene (ZFH1B). *Am J Med Genet* 2002;108:177-81.
- Zweier C, Temple IK, Beemer F, et al. Characterisation of deletions of the ZFH1B region and genotype-phenotype analysis in Mowat-Wilson syndrome. *J Med Genet* 2003;40:601-5.
- Zweier C, Thiel CT, Dufke A, et al. Clinical and Mutational Spectrum of Mowat-Wilson Syndrome. *Eur J Med Genet* 2005, 48: 97-111.
- Biro P, Vagts D, Emmig U, et al. Anästhesie bei seltenen Erkrankungen. Berlin: Springer-Verlag 2011.
- Davies W. Insights into rare diseases from social media surveys. *Orphan J Rare Dis* 2016,11:151-5.
- Guala A, Spunton M, Mainardi PC, et al. Anesthesia in Cri du Chat syndrome: information on 51 Italian patients. *Am J Med Genet* 2015,167A:1168-70.
- Deshmukt AS, Kelkar KV, Khedkar SM, et al. Anaesthetic management of Mowat-Wilson syndrome. *Ind J Anaesthesia* 2016,40:292-3.