

# Contralateral pneumothorax and pneumopericardium after dual-chamber pacemaker implantation: Mechanism, diagnosis, and treatment



Teerapat Nantsupawat, MD,\* Jian-Ming Li, MD, PhD,<sup>†</sup> David G. Benditt, MD,\*  
Selcuk Adabag, MD, MSc<sup>†</sup>

From the \*Division of Cardiology, University of Minnesota, Minneapolis, Minnesota, and <sup>†</sup>Division of Cardiology, Minneapolis VA Medical Center, Minneapolis, Minnesota.

## Introduction

Approximately 180,000 patients undergo permanent pacemaker (PPM) implantation in the United States each year.<sup>1</sup> Although pacemaker implantation usually is considered a safe procedure, it can be associated with potential complications such as pocket hematoma, infection, lead dislodgment, pneumothorax, and cardiac tamponade. Pneumothorax, which has been reported to occur in 1% of pacemaker implantations,<sup>2</sup> usually is caused by needle injury while gaining entry to the axillary or subclavian vein. As such, pneumothorax almost always is ipsilateral to the pacemaker. Pneumothorax of the contralateral lung is uncommon unless attempts for vascular entry were made on that side as well. We present a rare case of concomitant contralateral pneumothorax and pneumopericardium after pacemaker implantation.

## Case report

An 83-year-old man with a history of coronary artery disease and paroxysmal atrial fibrillation presented with syncope due to tachycardia-bradycardia syndrome. He underwent dual-chamber PPM implantation via the left axillary vein. A right atrial (RA) lead (Ingevity 7740 active fixation lead, Boston Scientific, Marlborough, MA) was positioned at the anterolateral RA free wall. A right ventricular lead was positioned at the apical septum. At implantation, the RA lead pacing threshold was 0.5 V at 0.5 ms, sensing was 8.0 mV, and impedance

was 668  $\Omega$ . Right ventricular lead pacing threshold was 0.4 V at 0.5 ms, sensing was 12.2 mV, and impedance was 915  $\Omega$ . Postprocedure chest radiography showed normal lead position and no evidence of pneumothorax.

Approximately 24 hours later, the patient developed sudden onset of severe neck and jaw pain that radiated to the anterior chest and worsened with inspiration. His vital signs at that time were blood pressure 157/91 mm Hg, heart rate 79 bpm, respiratory rate 16/min, temperature 98.3°F, and oxygen saturation 98%. On physical examination, no subcutaneous crepitus was noted. Lungs were clear with equal breath sounds. Heart rhythm was regular, without distant heart sounds or pericardial friction rub. Chest radiography showed no pneumothorax and normal lead position (Figure 1). Device interrogation demonstrated no significant change in sensing, pacing threshold, or impedance. Echocardiography showed no pericardial effusion. However, computed tomography (CT) of the chest, performed to exclude pulmonary embolus, revealed that the atrial lead tip had perforated the RA free wall (Figure 2) and caused a small right-sided pneumothorax and pneumopericardium (Figure 3). There was no evidence of pericardial effusion, chronic lung disease, or bullae on CT.

After a multidisciplinary discussion, conservative treatment strategy was pursued because of the small size of the pneumothorax/pneumopericardium and stable hemodynamics. The patient was hospitalized and given oxygen supplementation to facilitate reabsorption of the pneumothorax. Repeat CT after 2 days of observation showed resolution of the pneumothorax and pneumopericardium. The patient was discharged home and has been free of symptoms during 1-year follow-up.

**KEYWORDS** Contralateral; Pacemaker; Perforation; Pneumopericardium; Pneumothorax

(Heart Rhythm Case Reports 2018;4:256–259)

Dr Benditt has served as a consultant for Medtronic Inc and Zoll Corp and has equity in Medtronic Inc and Abbott Inc. Dr Adabag has received investigator-initiated research grants from Medtronic Inc and Boston Scientific Corp. None of the other authors report any potential conflicts of interest.

**Address reprint requests and correspondence:** Dr Teerapat Nantsupawat, Division of Cardiology, Department of Medicine, University of Minnesota, Mail Code 508, 420 Delaware St SE, Minneapolis, MN 55455. E-mail address: [teerapat@umn.edu](mailto:teerapat@umn.edu).

## Discussion

A large number of patients undergo pacemaker implantation for various indications.<sup>3</sup> This case demonstrates that contralateral pneumothorax and pneumopericardium may occur after pacemaker implantation as a result of RA lead perforation

**KEY TEACHING POINTS**

- Contralateral pneumothorax and pneumopericardium commonly present with pleuritic chest pain and/or shortness of breath. Less commonly, patients may report syncope, diaphragmatic stimulation, hypotension, or they may be asymptomatic.
- Electrocardiography, echocardiography, chest radiography, and device interrogation can be normal. Computed tomography is the test of choice to detect contralateral pneumothorax, pneumopericardium, or lead perforation.
- Management of contralateral pneumothorax and pneumopericardium should be guided by the amount of air leakage, the patient's hemodynamics status, and lead parameters. Conservative treatment may be sufficient in patients with stable vital signs, stable lead parameters, and small pneumothorax and pneumopericardium.
- The anteromedial tip of the right atrial appendage and the medial right atrial wall have a thicker wall and might be safer locations for lead implantation.

and can be managed conservatively in a hemodynamically stable patient. Concomitant contralateral pneumothorax and pneumopericardium after device implantation is an extremely rare complication, with only 2 previous cases reported in the literature (Table 1).

**Etiology and mechanism**

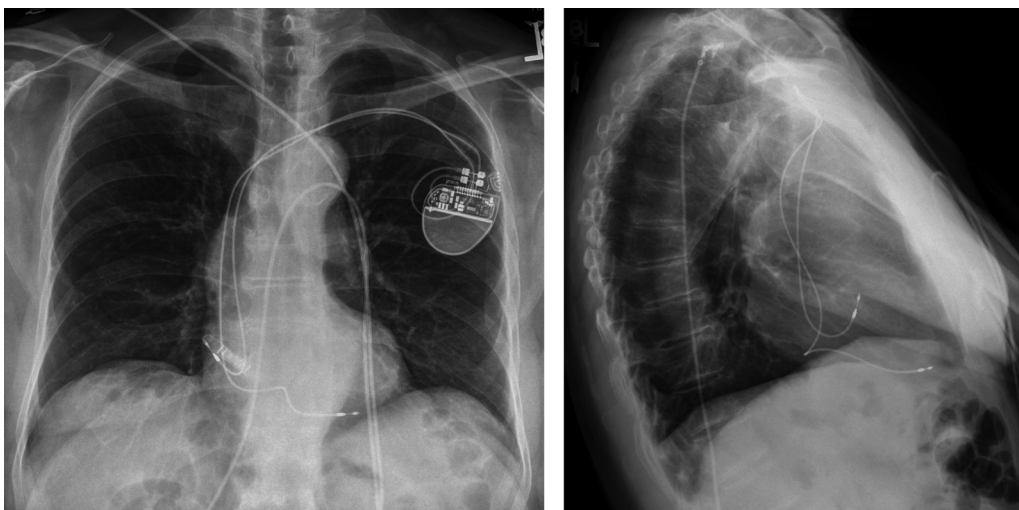
All cases listed in Table 1 could possibly be explained by one common mechanism, in which the lead and/or helix perforated through the RA free wall, pericardium, and right pleura, resulting in contralateral pneumothorax.

Both the pneumothorax and the pneumopericardium in our case seemed to result from the RA free wall perforation, with air from the pleural space tracking along the lead back to the pericardial space. No pericardial effusion was seen in the patients listed in Table 1, likely because the lead tip plugged the small perforation and prevented blood leaking out of the RA into the pericardial space.

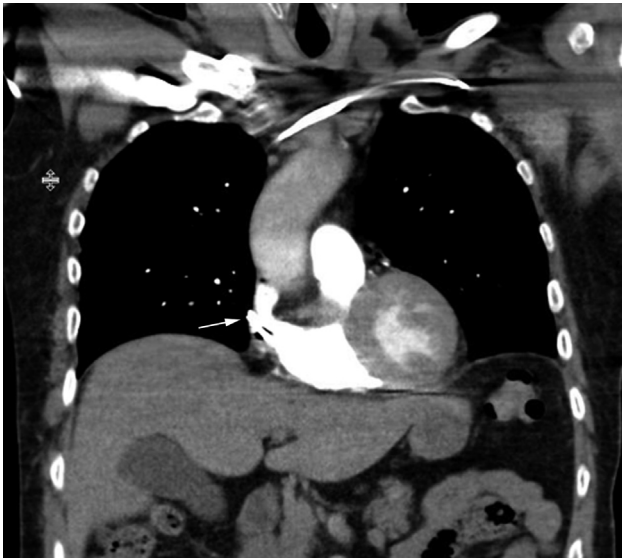
**Signs, symptoms, and diagnosis**

Patients with contralateral pneumothorax commonly present with pleuritic chest pain and/or shortness of breath. Less commonly they present with syncope, diaphragmatic stimulation, hypotension, or they may be asymptomatic. In published reports, symptoms mostly occurred within 1–4 days after device implantation.

Electrocardiography may show loss of atrial sensing or capture. Echocardiography may reveal new pericardial effusion or the pacemaker lead in the pericardial space. Chest radiography could demonstrate pneumothorax, pneumopericardium, or lead tip seen out of cardiac silhouette. Device interrogation may reveal a change in sensing, pacing threshold, or impedance. However, not all tests are equally sensitive. In a report by Srivathsan et al,<sup>4</sup> device interrogation was unchanged despite pneumothorax and pneumopericardium. In another report by Sebastian et al,<sup>5</sup> electrocardiogram, echocardiogram, and device interrogation were all normal. The sensitivity of chest radiography in detecting pneumothorax is approximately 46%.<sup>6</sup> Abnormal lead parameters on device interrogation also depend on whether the protruded helix is active (serves as a cathode) or passive. If the helix is not active, lead



**Figure 1** Chest radiographs in the anteroposterior (left) and lateral (right) views show the right atrial lead in the anterolateral position of the right atrium and the right ventricular lead in the apical septum. No pneumothorax or hemothorax is seen. The implantable loop recorder is in an unusual position.



**Figure 2** Computed tomography in the coronal view reveals the right atrial lead tip perforated the anterolateral wall of the right atrium (*arrow*).

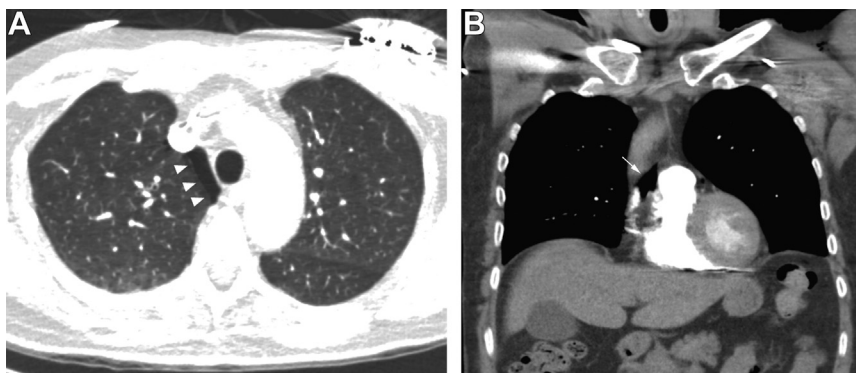
parameters may not change. Interestingly, our RA lead (Boston Scientific Ingevity 7740) has an active helix but lead parameters did not change. It could be that a large part of the electrode remained in contact with the atrial myocardium.

CT scan revealed abnormalities in all cases of contralateral pneumothorax, pneumomediastinum, pneumopericardium, and/or lead perforation after device implant.<sup>7</sup> Although clinical cardiac lead perforation occurs in 0.3% of new pacemaker implants,<sup>8</sup> 15% of RA leads and 6% of ventricular leads showed asymptomatic perforation on CT.<sup>9</sup> Therefore, we recommend CT chest radiography when there is clinical suspicion of cardiac lead perforation.

## Treatment

Because of the rarity of concomitant pneumothorax and pneumopericardium after device implant, management strategy is not well established. Sebastian et al<sup>5</sup> demonstrated resolution of both pneumothorax and pneumopericardium after chest tube insertion alone without the need for RA lead extraction. Srivathsan et al<sup>4</sup> performed both chest tube insertion and atrial lead extraction successfully and uneventfully. Our case demonstrated a successful outcome with conservative treatment. These case reports suggest that pneumopericardium by itself does not signify severe cardiac perforation, and cardiac lead perforations are not uniformly detrimental. Some factors, such as previous cardiac surgery, may mitigate the risk of gross cardiac perforation because of intrapericardial adhesions. Management should be guided by the amount of air or blood leakage, the patient's hemodynamic status, and lead parameters. A chest tube should be considered when pneumothorax involves >10% of the pleural space, the patient has continued respiratory distress, or hemopneumothorax is present.<sup>10</sup>

The helical screw in the ventricular lead was associated with a 2.5-fold higher risk of ventricular perforation.<sup>11</sup> In a CT study, an active fixation RA lead had a trend for a lower rate of perforation than a passive fixation lead.<sup>9</sup> However, this difference was not statistically significant because of the small sample size. J-shape and straight RA leads had similar pericardial complications (1%).<sup>12</sup> Concerns have been raised regarding an increased incidence of cardiac perforation by magnetic resonance imaging-compatible leads because of increased diameter and stiffness.<sup>13</sup> However, objective data on the Ingevity MRI lead are limited. RA leads were all positioned on the anterolateral wall or the RA appendage (Table 1). These findings are consistent with those of Greene et al,<sup>14</sup> who described acute pericarditis with pericardial effusion developing in 4.9% of



**Figure 3** **A:** Computed tomographic chest axial view lung window reveals a small pneumothorax along the medial aspect of the right upper lobe (*arrowheads*). **B:** Computed tomographic coronal view shows pneumopericardium posterior to the aorta (*arrow*).

**Table 1** Published case reports with contralateral pneumothorax and pneumopericardium

Authors	Patient	Atrial lead and position	Symptoms/signs	Postimplant	Abnormal test results	Severity	Treatment
Sebastian et al <sup>6</sup>	73-yr-old man with COPD and Mobitz type II AV block	Active fixation (CapSureFix Novus, Medtronic) Anterolateral RA	Sudden pleuritic chest pain	2 days	CXR: Yes CT: Yes Interrogate: No	50% PTx, moderate-sized pneumopericardium	Chest tube
Srivathsan et al <sup>4</sup>	77-yr-old woman with COPD and 4.5-s sinus pause	Active fixation (Model 5076, Medtronic) Anterolateral RAA	Shortness of breath	8 hours	CXR: Yes CT: Yes Interrogate: No	30% PTx, moderate-sized pneumopericardium	Chest tube, atrial lead extraction
Nantsupawat et al (our case)	83-yr-old man with CAD, CMP, tachy-brady syndrome	Active fixation (Ingevity7740, Boston Scientific) Anterolateral RA	Neck and pleuritic chest pain	1 day	CXR: No CT: Yes Interrogate: No	<10% PTx, small pneumopericardium	Oxygen, observe

CAD = coronary artery disease; CMP = cardiomyopathy; COPD = chronic obstructive pulmonary disease; CT = computed tomography; CXR = chest x-ray (radiography); PTx = pneumothorax; RA = right atrium; RAA = right atrial appendage.

patients, especially when the lead was placed in the lateral and anterolateral RA. Ueda et al<sup>15</sup> demonstrated that the anteromedial tip of the RA appendage and the medial RA wall have a thicker wall and might be safer for lead implant compared to the posterolateral tip of the RA appendage or the lateral RA wall, which have a very thin membrane-like wall between pectinate muscles.

## Conclusion

Contralateral pneumothorax and pneumopericardium is a rare complication after PPM implantation and may not be evident on chest radiography and device interrogation. Conservative treatment, without the need for a chest tube or atrial lead extraction, may be sufficient in patients with stable vital signs, stable lead parameters, and small pneumothorax and pneumopericardium. However, because of the rarity of this condition, the ideal treatment is unknown and deserves further study.

## References

- Kurtz SM, Ochoa JA, Lau E, Shkolnikov Y, Pavri BB, Frisch D, Greenspon AJ. Implantation trends and patient profiles for pacemakers and implantable cardioverter defibrillators in the United States: 1993-2006. *Pacing Clin Electrophysiol* 2010;33:705-711.
- van Rees JB, de Bie MK, Thijssen J, Borleffs CJ, Schalij MJ, van Erven L. Implantation-related complications of implantable cardioverter-defibrillators and cardiac resynchronization therapy devices: a systematic review of randomized clinical trials. *J Am Coll Cardiol* 2011;58:995-1000.
- Raza SS, Li JM, John R, Chen LY, Tholakanahalli VN, Mbai M, Adabag AS. Long-term mortality and pacing outcomes of patients with permanent pacemaker implantation after cardiac surgery. *Pacing Clin Electrophysiol* 2011;34:331-338.
- Srivathsan K, Byrne RA, Appleton CP, Scott LR. Pneumopericardium and pneumothorax contralateral to venous access site after permanent pacemaker implantation. *Europace* 2003;5:361-363.
- Sebastian CC, Wu WC, Shafer M, Choudhary G, Patel PM. Pneumopericardium and pneumothorax after permanent pacemaker implantation. *Pacing Clin Electrophysiol* 2005;28:466-468.
- Ebrahimi A, Youseffard M, Mohammad Kazemi H, Rasouli HR, Asady H, Moghadas Jafari A, Hosseini M. Diagnostic accuracy of chest ultrasonography versus chest radiography for identification of pneumothorax: a systematic review and meta-analysis. *Tanaffos* 2014;13:29-40.
- Henrikson CA, Leng CT, Yuh DD, Brinker JA. Computed tomography to assess possible cardiac lead perforation. *Pacing Clin Electrophysiol* 2006;29:509-511.
- Hill PE. Complications of permanent transvenous cardiac pacing: a 14-year review of all transvenous pacemakers inserted at one community hospital. *Pacing Clin Electrophysiol* 1987;10:564-570.
- Hirschl DA, Jain VR, Spindola-Franco H, Gross JN, Haramati LB. Prevalence and characterization of asymptomatic pacemaker and ICD lead perforation on CT. *Pacing Clin Electrophysiol* 2007;30:28-32.
- Sheldon SH, Hayes DL, Friedman PA, Asirvatham SJ. Implant-related complications: relevant anatomy and an approach for prevention. In: Hayes DL, Asirvatham SJ, Friedman PA, eds. *Cardiac Pacing, Defibrillation and Resynchronization: A Clinical Approach*, Third Edition. Hoboken, NJ: John Wiley & Sons; 2013:219-254.
- Mahapatra S, Bybee KA, Bunch TJ, Espinosa RE, Sinak LJ, McGoon MD, Hayes DL. Incidence and predictors of cardiac perforation after permanent pacemaker placement. *Heart Rhythm* 2005;2:907-911.
- Glikson M, Yaacoby E, Feldman S, Bar-Lev DS, Yaroslavtzev S, Granit C, Rotstein Z, Kaplinsky E, Eldar M. Randomized comparison of J-shaped and straight atrial screw-in pacing leads. *Mayo Clin Proc* 2000;75:1269-1273.
- Acha MR, Keaney JJ, Lubitz SA, Milan DJ, Mansour M, Heist KE, Ptaszek LM, Singh JP, Blendea D, Mela T. Increased perforation risk with an MRI-conditional pacing lead: a single-center study. *Pacing Clin Electrophysiol* 2015;38:334-342.
- Greene TO, Portnow AS, Huang SK. Acute pericarditis resulting from an endocardial active fixation screw-in atrial lead. *Pacing Clin Electrophysiol* 1994;17:21-25.
- Ueda A, McCarthy KP, Sanchez-Quintana D, Ho SY. Right atrial appendage and vestibule: further anatomical insights with implications for invasive electrophysiology. *Europace* 2013;15:728-734.