

Case Report

Open Access

## Concomitant Xeroderma pigmentosum and disseminated small plaque psoriasis: first case of an antinomic association

Khaled Ezzedine\*<sup>1</sup>, Thierry Simonart<sup>1</sup>, Michel Candaele<sup>1</sup>, Denis Malvy<sup>2</sup> and Michel Heenen<sup>1</sup>

Address: <sup>1</sup>Department of Dermatology, Hôpital Erasme, Université Libre de Bruxelles, 808, route de Lennik, Brussels, B-1070 Belgium and <sup>2</sup>Department of Internal Medicine and Infectious diseases, CHU St-André Bordeaux, 1, Rue Jean Burguet, 33075 France

Email: Khaled Ezzedine\* - kezzedin@ulb.ac.be; Thierry Simonart - tsimonar@ulb.ac.be; Michel Candaele - mcandael@ulb.ac.be; Denis Malvy - denis.malvy@chu-bordeaux.fr; Michel Heenen - mheenen@ulb.ac.be

\* Corresponding author

Published: 7 August 2008

Received: 6 June 2008

Cases Journal 2008, 1:74 doi:10.1186/1757-1626-1-74

Accepted: 7 August 2008

This article is available from: <http://www.casesjournal.com/content/1/1/74>

© 2008 Ezzedine et al; licensee BioMed Central Ltd.

This is an Open Access article distributed under the terms of the Creative Commons Attribution License (<http://creativecommons.org/licenses/by/2.0>), which permits unrestricted use, distribution, and reproduction in any medium, provided the original work is properly cited.

### Abstract

We present the case of an eighteen-year-old Caucasian white boy who was diagnosed with xeroderma pigmentosum type A at age 5 and who experienced over the past year disseminated small plaque psoriasis confirmed with skin punch biopsy. The psoriatic lesions were successfully treated with multipotent topical corticosteroids and systemic retinoids. To our knowledge, the association between psoriasis and xeroderma pigmentosum has not been previously reported and may be regarded as unlikely when considering the pathogenesis of both diseases.

### Background

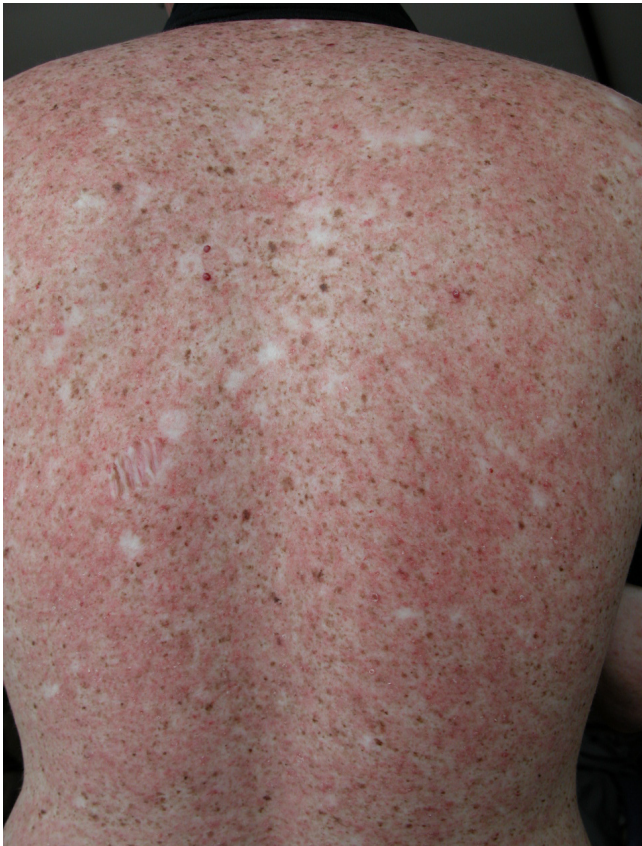Xeroderma pigmentosum (XP) is a rare autosomal recessive disorder characterized by a defect of DNA-repair occurring during UV-induced damage. The disease is quite complex and different subsets of abnormalities in the DNA-repair system may be present during the course of the disease. Thus, patients with XP have a decreased cutaneous immune surveillance which results in an increased risk of UV-induced skin tumours at an early age. Basal cell carcinoma (BCC), squamous cell carcinoma (SCC), actinic keratoses, atypical moles and malignant melanoma, all associated with severe photoaging are commonly seen in such patients. The prognosis of XP is based on early diagnosis as to permit strict UV avoidance and early detection and treatment of skin tumours, especially in photo-exposed areas.

### Case presentation

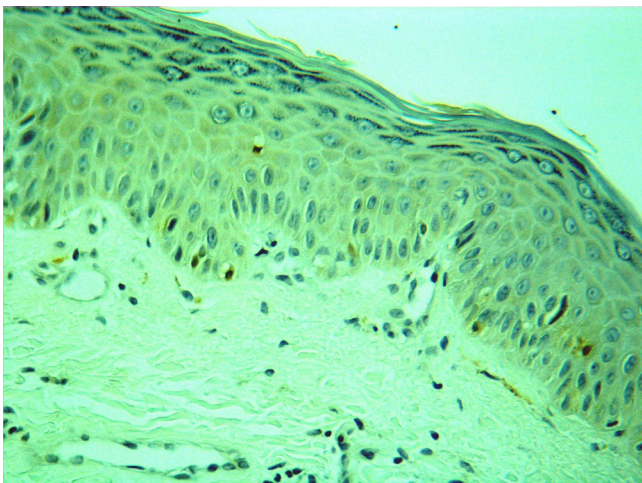
We present the case of an eighteen-year-old white Caucasian boy who was diagnosed with XP type A at age 5. Other clinical signs include photophobia, keratitis and loss of eyelashes. Despite rigorous monitoring and photoprotection, the patient developed over 100 facial skin cancers (mainly BCC and SCC) treated with cryotherapy and surgery. Surprisingly, the patient experienced over the past year disseminated small plaque psoriasis (Fig. 1) confirmed with skin punch biopsy. S100 staining showed reduced density of Langerhans cells in healthy skin (Fig. 2), as previously reported in XP group A [1]. The psoriatic lesions were successfully treated with multipotent topical corticosteroids and systemic retinoids.

### Discussion

To our knowledge, the association between psoriasis and XP has not been previously reported and may be regarded



**Figure 1**  
Association of small erythematous scaly plaques with multiple areas of hyperpigmentation resembling freckles on the patient's back.



**Figure 2**  
S100 staining showing reduced density of Langerhans cells in healthy skin.

as unlikely when considering the pathogenesis of both diseases.

XP patients exhibit Langerhans cell depletion, intensified impairment of natural killer (NK) cell function and enhanced UV-immunosuppression, possibly mediated through increased prostaglandin E2 production [1-4]. By opposition, psoriatic plaques are characterized by immune activation, with NK cell activation and decreased cyclo-oxygenase activity [5,6].

In addition, in XP, unrestricted cellular proliferation is associated with inactivation of members of the iNK4a/Arf locus, such as p14 and p16 [7]. By opposition, in psoriasis, members of the iNK4a/Arf locus are overexpressed, which may contribute to the senescent switch and resistance of psoriatic plaques to cellular transformation despite altered differentiation, angiogenesis, increased telomerase activity, proliferative changes and apoptosis resistance characterising psoriatic skin [8,9].

Further data are required to determine why and how those apparently antinomic diseases can coexist.

#### Abbreviations

BCC: Basal cell carcinoma; DNA: desoxy ribonucleic acid; iNK: invariant natural killer; NK: natural killer; SCC: squamous cell carcinoma; UV: ultraviolet; XP: xeroderma pigmentosum.

#### Competing interests

The authors declare that they have no competing interests.

#### Authors' contributions

KE, TS, MH examined the patient. KE and TS were the major contributors in writing the manuscript. DM first seen the patient and helped to the redaction of the manuscript. MH and MC treated the patient and MH performed the histological examination for the skin biopsy. All authors read and approved the final manuscript.

#### Consent

Written informed consent was obtained from the patient for publication of this case report and accompanying images. A copy of the written consent is available for review by the Editor-in-Chief of this journal.

#### References

1. Jimbo T, Ichihashi M, Mishima Y, Fujiwara Y: **Role of excision repair in UVB-induced depletion and recovery of human epidermal Langerhans cells.** *Arch Dermatol* 1992, **128**:61-7.
2. Horio T, Miyauchi-Hashimoto H, Kuwamoto K, Horiki S, Okamoto H, Tanaka K: **Photobiologic and photoimmunologic characteristics of XPA gene-deficient mice.** *J Invest Dermatol Symp Proc* 2001, **6**:58-63.
3. Kolgen W, van Steeg H, Horst GT van der, Hoeijmakers JH, van Vloten WA, de Gruijl FR, Garssen J: **Association of transcription-coupled repair but not global genome repair with ultraviolet**

- let-B-induced Langerhans cell depletion and local immunosuppression.** *J Invest Dermatol* 2003, **121**:751-6.
4. Ottaviani C, Nasorri F, Bedini C, de Pita O, Girolomoni G, Cavani A: **CD56brightCD16(-) NK cells accumulate in psoriatic skin in response to CXCL10 and CCL5 and exacerbate skin inflammation.** *Eur J Immunol* 2006, **36**:118-28.
  5. Kanda N, Mitsui H, Watanabe S: **Prostaglandin E(2) suppresses CCL27 production through EP2 and EP3 receptors in human keratinocytes.** *J Allergy Clin Immunol* 2004, **114**:1403-9.
  6. Remy W, Sigl I, Leipold B: **Prostaglandin E2 gel improvement of psoriatic lesions.** *Int J Dermatol* 1986, **25**:266-8.
  7. Soufir N, Daya-Grosjean L, de La Salmoniere P, Moles JP, Dubertret L, Sarasin A, Basset-Seguain N: **Association between INK4a-ARF and p53 mutations in skin carcinomas of xeroderma pigmentosum patients.** *J Natl Cancer Inst* 2000, **92**:1841-7.
  8. Chaturvedi V, Cesnjaj M, Bacon P, Panella J, Choubey D, Diaz MO, Nickoloff BJ: **Role of INK4a/Arf locus-encoded senescent checkpoints activated in normal and psoriatic keratinocytes.** *Am J Pathol* 2003, **162**:161-70.
  9. Nickoloff BJ: **Creation of psoriatic plaques: the ultimate tumor suppressor pathway. A new model for an ancient T-cell-mediated skin disease. Viewpoint.** *J Cutan Pathol* 2001, **28**:57-64.

Publish with **BioMed Central** and every scientist can read your work free of charge

*"BioMed Central will be the most significant development for disseminating the results of biomedical research in our lifetime."*

Sir Paul Nurse, Cancer Research UK

Your research papers will be:

- available free of charge to the entire biomedical community
- peer reviewed and published immediately upon acceptance
- cited in PubMed and archived on PubMed Central
- yours — you keep the copyright

Submit your manuscript here:  
[http://www.biomedcentral.com/info/publishing\\_adv.asp](http://www.biomedcentral.com/info/publishing_adv.asp)

