



Lungworm *Eucoleus aerophilus* (*Capillaria aerophila*) infection in a feline immunodeficiency virus-positive cat in France

Sarah Elhamiani Khatat^{1,2}, Dan Rosenberg^{1,3}, Ghita Benchekroun¹ and Bruno Polack⁴

Journal of Feline Medicine and Surgery
Open Reports
1–5

© The Author(s) 2016
Reprints and permissions:
sagepub.co.uk/journalsPermissions.nav
DOI: 10.1177/2055116916651649
jfmsopenreports.com

This paper was handled and processed by the European Editorial Office (ISFM) for publication in JFMS Open Reports



Abstract

Case summary A 2-year-old domestic shorthair female outdoor cat living in France was diagnosed with a lungworm infection due to *Eucoleus aerophilus*. The history and clinical signs, in association with bronchoscopic examination, suggested chronic upper respiratory disease. Cytological examination of bronchoalveolar lavage fluid (BALF) was consistent with suppurative bronchitis. Direct microscopic examination of BALF enabled the identification of *E aerophilus* ova.

Relevance and novel information The cat was positive for feline immunodeficiency virus and had been treated with steroids for a suspected allergic bronchitis, suggesting that immunodeficiency was probably a facilitating factor for *E aerophilus* infection, as described in previous cases. This case report emphasises the importance of considering eucoleosis (capillariosis) in the differential diagnosis of respiratory disease in cats. To our knowledge, this is the first clinical case of *E aerophilus* infection described in a domestic cat in France.

Accepted: 4 May 2016

Introduction

Eucoleus aerophilus (*Capillaria aerophila*) is a nematode belonging to the Trichuridae family that parasitises the respiratory tract of dogs, cats, wild carnivores and occasionally people.^{1–3} The adult stages live under the epithelium of the trachea, bronchi and bronchioles of the infected host.⁴ Females produce barrel-shaped, asymmetric, bipolar plugs and non-embryonated ova inside the mucosa (64.91 ± 1.11 – 65.04 ± 1.50 μm long, 34.89 ± 3.34 – 36.96 ± 3.15 μm wide). The eggs go through the mucosa, get coughed up and swallowed by the host and then shed in the feces. The prepatent period is around 3–5 weeks and infection remains patent for 8–11 months. In optimal climatic conditions, larvae develop within the ova and reach the infectious stage in 30–45 days in the environment; the larvae inside the ova may survive up to 1 year. The ova can also develop in earthworms (facultative intermediate host). The definitive host is infected by direct ingestion of eggs or through an intermediate host. Eggs hatch in the host's digestive tract and larvae migrate via blood vessels to the lungs.^{2,4–6}

The prevalence of *E aerophilus* infection varies according to the host species and geographical areas. In domestic carnivores, prevalence rates range from 0–9% in some countries.^{3,5,7–11} Despite the worldwide distribution of *E aerophilus*, this parasite is still poorly

¹Unit of Small Animal Internal Medicine, Centre Hospitalier Universitaire, Ecole Nationale Vétérinaire d'Alfort, Université Paris-Est, France

²Department of Veterinary Public Health, Unit of Parasitology, Institut Agronomique et Vétérinaire Hassan II, Rabat, Morocco

³MICEN VET, Créteil, France

⁴Unit of Parasitology, Biopôle, Ecole Nationale Vétérinaire, Université Paris-Est, France

Corresponding author:

Sarah Elhamiani Khatat DVM, Department of Veterinary Public Health, Unit of Parasitology, Institut Agronomique et Vétérinaire Hassan II, Madinat Al Irfane, BP 6202, Rabat – Instituts 10101, Morocco

Email: elhamianis@yahoo.fr



Creative Commons Non Commercial CC-BY-NC: This article is distributed under the terms of the Creative Commons

Attribution-NonCommercial 3.0 License (<http://www.creativecommons.org/licenses/by-nc/3.0/>) which permits non-commercial use, reproduction and distribution of the work without further permission provided the original work is attributed as specified on the SAGE and Open Access pages (<https://us.sagepub.com/en-us/nam/open-access-at-sage>).

known and eucoleosis (capillariosis) continues to be neglected.² This lack of knowledge, in association with non-specific clinical signs,¹ could explain why pulmonary eucoleosis is usually considered asymptomatic or subclinical in domestic carnivores.^{2,6} To our knowledge, no data are available on the occurrence of this parasite in France. Despite a worldwide distribution and a high prevalence in wildlife species, infection of domestic carnivores was considered sporadic until the past decade, but this appears to be an underestimation.^{1,12,13}

Case description

A 2-year-old neutered female domestic shorthair outdoor cat was presented for a 4 month history of respiratory signs. The cat was previously presented at a private veterinary practice for snoring, dysphonia and an initially non-productive cough but which had evolved to a productive cough. It was treated with corticosteroids, nebulisation therapy and several antibiotics, including marbofloxacin, doxycycline and cefovecine, but no improvement was achieved. The cat was not regularly vaccinated but had been recently dewormed (praziquantel and pyrantel). It lived in a multi-cat household, consisting of 20 well-vaccinated and regularly dewormed rescue animals. All cats had free access to the outdoors, including a nearby forest. None of the other animals showed clinical signs.

Abnormalities on physical examination included tachypnoea (80 breaths per min), tachycardia (>200 beats per min) and fever (40°C). Thoracic auscultation revealed severe bilateral wheezing and crackles, together with increased breathing sounds on tracheal auscultation and tracheal hypersensitivity.

Thoracic radiographs did not reveal any abnormalities. Bronchoscopy under general anaesthesia (butorphanol 0.2 mg/kg IV, constant rate infusion of propofol) revealed a larynx oedema, a tracheal inflammation and an abundant mucoid to mucopurulent secretion. Cytological examination of the bronchoalveolar lavage fluid (BALF) showed a moderate cell density, a high amount of mostly degenerative neutrophils (>90%) and intracellular bacteria (cocci/bacilli), suggesting suppurative bronchitis (Figure 1). Additionally, direct microscopic examination of the BALF was performed, and numerous *E aerophilus* ova were observed (Figures 2 and 3).

An in-clinic ELISA (IDEXX) for the detection of both feline immunodeficiency virus (FIV) antibodies and feline leukaemia virus antigens was performed and revealed an FIV infection. Complete blood cell count showed moderate leukocytosis (27.3×10^9 cells/l; reference interval [RI] 6.0–11.0) due to a mature neutrophilia (23.6×10^9 cells/l; RI 3.0–11.0) and a mild monocytosis (0.8×10^9 cells/l; RI 0.04–0.5). The cat was hospitalised and received fluid therapy, amoxicillin/clavulanic acid (Augmentin, 20 mg/kg IV q12h; GlaxoSmithKline),

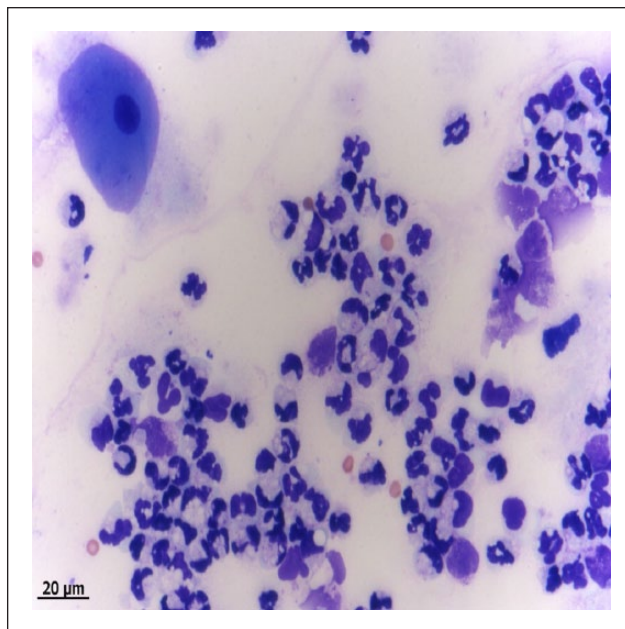


Figure 1 Microscopic image of the bronchoalveolar lavage showing a high amount of neutrophils. May–Grünwald–Giemsa stain (magnification $\times 400$)

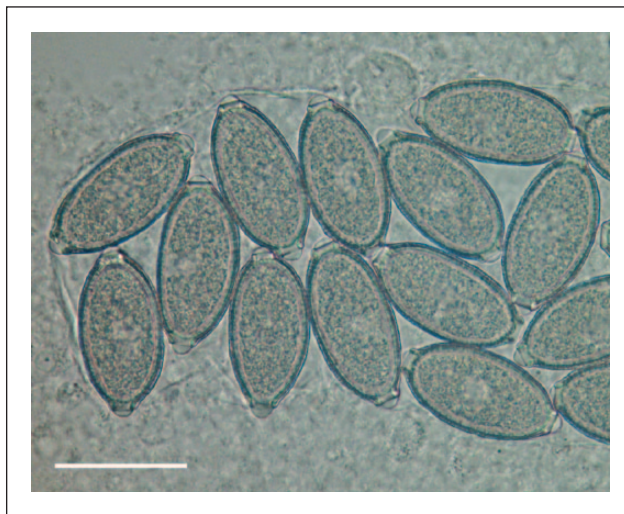


Figure 2 *Eucolus aerophilus* eggs embedded in debris (uterus) of adult helminths observed on direct light microscopic examination of bronchoalveolar lavage (magnification $\times 40$, bar = 50 μm)

prednisolone (Dermipred, 0.5 mg/kg PO q24h; Sogeval), fenbendazole (Panacur, 50 mg/kg PO q24h; Intervet), theophylline (Sepvapulmyl, 4 mg/kg PO q12h Sogeval) and nebulisation therapy. The cat was discharged after 4 days. The antibiotic, corticosteroid and nebulisation therapy had been continued for 21 days and the anthelmintic treatment for 10 days (ie, a 14 day course of fenbendazole in total). Three weeks after discharge, the cat was in a good clinical condition, although some

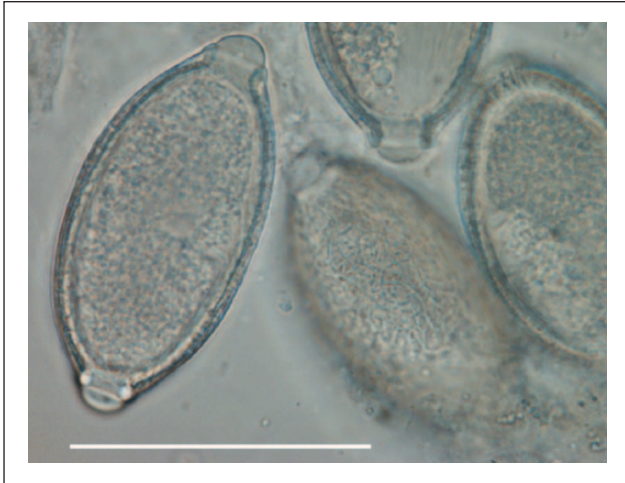


Figure 3 Characteristic *Eucoleus aerophilus* ova. (Left) Barrel-shaped, asymmetric, bipolar-plug egg with the zygote cell occupying the inside space. (Centre) Shell wall surface of an egg showing the network of anastomosing ridges (magnification $\times 100$, bar = 50 μm)

wheezing was still present on tracheal auscultation. Coproscopic examination of samples from the cat was negative for *E aerophilus* ova. The owner was advised to pursue the antibiotic therapy. At the 7 week follow-up, the owner reported that the cat started coughing again 10 days earlier. Coproscopic analysis was positive for *E aerophilus* ova, most probably indicating reinfection or recurrence. A 14 day course of fendendazole (Panacur; Intervet) was repeated in association with amoxicillin/clavulanic acid (Kesium; Sogeval) for 10 days. The owner was lost to follow-up after 2.5 months.

Discussion

Infection with *E aerophilus* appears mostly asymptomatic or subclinical in domestic carnivores.^{2,6} However, a recent study carried out in Italy showed the occurrence of clinical signs in 87.5% and 72.7% of dogs and cats, respectively, indicating that the prevalence of clinical disease might be underestimated.⁵ Clinical signs associated with eucoleosis mimic those of an unspecific chronic bronchitis of varying severity and include coughing, nasal discharge, sneezing, wheezing, bronchovesicular sounds, dyspnoea and weight loss.^{1,3,12} The cough is usually dry and chronic but can evolve to moist and productive, especially when secondary bacterial infection is present. A heavy infection might become lethal owing to bronchopneumonia or respiratory failure.^{2,12,13} The main clinical signs in this cat were a chronic dry cough that evolved to moist and productive, associated with tracheal hypersensitivity. Similarly, a previous case report of feline *E aerophilus* infection described the presence of tracheal hypersensitivity.⁶ The cat also suffered from dyspnoea, associated with wheezing and crackles on pulmonary

auscultation, which is suggestive of a bronchopneumonia. The associated fever was likely secondary to bacterial bronchopneumonia. A retrospective study of 21 cases of feline lower respiratory tract infections showed hyperthermia in 24% of the cases but only in 1/25 cats diagnosed with bronchial disease during the same period.¹⁴ Before the occurrence of the cough and dyspnoea, the cat had presented signs compatible with upper respiratory tract involvement, including snoring and dysphonia, indicating a slow evolution to lower respiratory tract disease. The severity of clinical signs associated with respiratory eucoleosis depends on several factors, including the severity of infection, age of the patient and its immune status.^{6,13,15} Concurrent diseases were also described in previous feline case reports such as FIV infection, *Cryptococcus* species infection and chronic kidney failure associated with occult urinary tract infection.^{6,14,16} Hence, when clinical *E aerophilus* infection is diagnosed in domestic cats, underlying diseases causing immunodeficiency should be investigated. The present cat was also FIV-positive and had been previously treated with steroids for a suspected allergic bronchitis. These two factors might have facilitated *E aerophilus* infection. In addition, the living conditions (ie, a multi-cat household, free access to the outdoors and the proximity of a forest) had probably increased the infection pressure on this cat. Alterations associated with respiratory eucoleosis are similar to those described in chronic obstructive pulmonary diseases and recurrent airway obstruction in people and animals.¹⁷ These similarities might explain the misinterpretation of the clinical signs in the cat, which had been treated for feline asthma with steroidal anti-inflammatory drugs, which possibly aggravated the disease. Therefore, despite the low prevalence of *E aerophilus* infection in domestic animals, this case emphasises that it should be considered in the differential diagnosis of respiratory disease.^{5,12}

In contrast with two other cases of feline respiratory eucoleosis, no thoracic radiographs anomalies were observed in the present cat. These previous reports described a bronchial pattern associated with pulmonary nodules. However, co-infection with *Cryptococcus* species was identified in both cases, which may have contributed to the radiographic lesions.^{6,14,16} In one case, the bronchial patterns remained present even after efficient antimycosal treatment and hence could be associated with *E aerophilus* infection.⁶ Clinical signs, thoracic radiographs, bronchoscopy, haematological and biochemistry profile modifications are all lacking specificity in the diagnosis of pulmonary eucoleosis. Therefore, the diagnosis is based on the identification of ova in the faeces by performing a coproscopic flotation test and/or in the BALF by direct microscopic examination.^{3,12} However, even the identification of ova in faeces has considerable

limitations such as the variable and intermittent excretion of eggs in the faeces and possible misdiagnosis due to sample contamination by eggs from other capillarid or trichuroid species, especially in cases of mixed infections.^{12,16,18} The number of excreted ova decreases after 2–3 months during the last stages of infection. Therefore, BALF examination and the coproscopic flotation can both lack sensitivity for *E aerophilus* diagnosis, especially as most cases, including the present one, are presented several weeks to months after the onset of clinical signs. Multiple faecal samplings have to be performed to increase the test's sensitivity, with a minimum of three samples recommended.¹⁶ Recent studies have demonstrated an interest in molecular tests in the diagnosis of trichuroid infections, as differentiation between species by morphological examination is difficult.^{18,19} Molecular diagnosis could avoid the lack of specificity and sensitivity associated with the abovementioned detection methods and appears to be an interesting complementary tool.¹⁸

Several therapeutic protocols with different molecules have been cited in the literature, including fenbendazole, abamectin, ivermectin and levamisole.^{3,6,13} A recent experimental prospective study also assessed the efficacy and safety of treatment with imidacloprid 10%/moxidectin 1% spot-on (Advocate; Bayer Animal Health) in naturally infected cats. A single administration of this spot-on treatment appeared to be safe and effective. The single dose and ease of application are of a great advantage, especially in indocile or feral animals.¹³ More recently, a case of co-infection by *E aerophila* and *Troglostrongylus brevior* was efficiently treated with a single dose of a solution containing emodepside 2.1%/praziquantel 8.6% spot-on (Profender; Bayer Animal Health).²⁰ Supportive drugs can be added to improve the clinical signs.^{6,15} The present cat was treated with fenbendazole and this enabled a complete remission of the clinical signs and a negative coproscopic examination. However, clinical signs were present 6 weeks after discharge, associated with a positive coproscopic examination showing *E aerophilus* ova. This could be explained either by a reinfection due to the living conditions (ie, multi-cat household and free outdoor access) or a recurrence due to a partial response to fenbendazole. Given the possible direct cycle and the zoonotic potential of *E aerophilus*, sanitary measures are imperative for disease control, especially under group housing conditions.^{4,7,12,15} A few cases of human respiratory eucoleosis due to *E aerophilus* have been documented: eight cases in Russia and Ukraine, and solitary cases in Morocco, Iran and France.^{4,21} The owner of the cat described in this report has been advised to treat all congeners and to isolate the sick cat, also because of its FIV-positive status. In order to detect reinfection promptly, faecal examinations should be performed 6–12 months after a successful therapy,¹⁵ especially when concurrent diseases with

possible associated immunodepression are present. Owners have to be informed of the possible recurrence of the clinical signs.

Conclusions

This report describes a case of respiratory eucoleosis due to *E aerophilus* in a domestic cat. To our knowledge this is the first clinical case of a domestic carnivore infection described in France. Bronchoscopy combined with BALF and tracheal mucus microscopic examination was useful in establishing the diagnosis. This report highlights the importance of including parasitic aetiologies in the differential diagnosis of respiratory complaints, especially when a refractory response to usual treatments occurs and immunodeficiency is present. Allergic bronchitis is considered the first cause of chronic coughing in cats, but in the light of this report, steroidal therapy should be delayed until the exclusion of any possible infectious origin. Considering the zoonotic aspect of *E aerophilus* and its increasing spread, efforts have to be made to improve the knowledge and the diagnosis of this parasite.

Acknowledgements We thank the students (Dr Ramade, Dr Duhamelle and Dr Bensemmane), the veterinarians and the nurses who contributed to the diagnosis and treatment of the cat described in this case report. We are also grateful to Professor Kachani and Dr Tafflin for their contributions to this manuscript.

Funding The authors received no financial support for the research, authorship, and/or publication of this article.

Conflict of interest The authors declared no potential conflicts of interest with respect to the research, authorship, and/or publication of this article.

References

- 1 Di Cesare A, Castagna G, Meloni S, et al. **Mixed trichuroid infestation in a dog from Italy.** *Parasit Vectors* 2012; 5: 128–133.
- 2 Traversa D, Di Cesare A, Lia RP, et al. **New insights into morphological and biological features of *Capillaria aerophila* (Trichocephalida, Trichuridae).** *Parasitol Res* 2011; 109: S97–S104
- 3 Conboy G. **Helminth parasites of the canine and feline respiratory tract.** *Vet Clin North Am Small Anim Pract* 2009; 39: 1109–1126.
- 4 Bowman DD, Hendrix CM, Lindsay DS, et al. *Feline clinical parasitology*. 1st ed. Ames: Iowa State University Press, 2002, pp 338–340.
- 5 Traversa D, Di Cesare A, Milillo P, et al. **Infection by *Eucoleus aerophilus* in dogs and cats: is another extra-intestinal parasitic nematode of pets emerging in Italy?** *Res Vet Sci* 2009; 87: 270–272.
- 6 Barrs VR, Martin P, Nicoll RG, et al. **Pumonary cryptococcosis and *Capillaria aerophila* infection in an FIV-positive cat.** *Aust Vet J* 2000; 78: 154–158.
- 7 Mugnaini L, Papini R, Gorini G, et al. **Pattern and predictive factors of endoparasitism in cats in Central Italy.** *Rev Med Vet* 2012; 163: 89–94.

- 8 Spada E, Proverbio D, Della Pepa A, et al. **Prevalence of faecal-borne parasites in colony stray cats in northern Italy.** *J Feline Med Surg* 2013; 15: 672–677.
- 9 Waap H, Gomes J and Nunes T. **Parasite communities in stray cat populations from Lisbon, Portugal.** *J Helminthol* 2013; 30: 1–7.
- 10 Krone O, Guminsky O, Meinig H, et al. **Endoparasite spectrum of wild cats (*Felis silvestris* Schreber, 1777) and domestic cats (*Felis catus* L) from the Eifel, Pfalz region and Saarland, Germany.** *Eur J Wildl Res* 2008; 54: 95–100.
- 11 Mircean V, Titilincu A and Vasile C. **Prevalence of endoparasites in household cat (*Felis catus*) populations from Transylvania (Romania) and association with risk factors.** *Vet Parasitol* 2010; 171: 163–166.
- 12 Traversa D, Di Cesare A and Conboy G. **Canine and feline cardiopulmonary parasitic nematodes in Europe: emerging and underestimated.** *Parasit Vectors* 2010; 3: 62–83.
- 13 Traversa D, Di Cesare A, Di Giulio E, et al. **Efficacy and safety of imidacloprid 10%/moxidectin 1% spot-on formulation in the treatment of feline infection by *Capillaria aerophila*.** *Parasitol Res* 2012; 111: 1793–1798.
- 14 Foster SF, Marti P, Allan GS, et al. **Lower respiratory tract infections in cats: 21 cases (1995–2000).** *J Feline Med Surg* 2004; 6: 167–180.
- 15 Burgess H, Ruotsalo K, Peregrine AS, et al. ***Eucoleus aerophilus* respiratory infection in a dog with Addison's disease.** *Can Vet J* 2008; 49: 389–392.
- 16 Foster SF, Martin P, Braddock JA, et al. **A retrospective analysis of feline bronchoalveolar lavage cytology and microbiology (1995–2000).** *J Feline Med Surg* 2004; 6: 189–198.
- 17 Nevarez A, Lopez A, Conboy G, et al. **Distribution of *Crenosoma vulpis* and *Eucoleus aerophilus* in the lung of free-ranging red foxes (*Vulpes vulpes*).** *J Vet Diagn Invest* 2005; 17: 486–489.
- 18 Di Cesare A, Castagna G, Otranto D, et al. **Molecular detection of *Capillaria aerophila*, an agent of canine and feline pulmonary capillariasis.** *J Clin Microbiol* 2012; 50: 1958–1963.
- 19 Guardone L, Deplazes P, Macchioni F, et al. **Ribosomal and mitochondrial DNA analysis of *Trichuridae* nematodes of carnivores and small mammals.** *Vet Parasitol* 2013; 197: 364–369.
- 20 Di Cesare A, Iorio R, Crisi P, et al. **Treatment of *Troglostroglylus brevior* (Metastrongyloidea, Crenosomatidae) in mixed lungworm infections using spot-on emodepside.** *J Feline Med Surg* 2015; 17: 181–185.
- 21 Laloševic D, Laloševic V, Klem I, et al. **Pulmonary capillariasis miming bronchial carcinoma.** *Am J Trop Med Hyg* 2008; 78: 14–16.