

OPEN

Disseminated Intravascular Coagulation Following Heart Transplant in an HIV-infected Recipient: Case Report and Review of the Literature

Xun Zhou, MD,¹ Mrinmayee Mandal,² Alejandro Suarez-Pierre, MD,¹ Aravind Krishnan, BA,¹ Charles D. Fraser III, MD,¹ Glenn J.R. Whitman, MD,¹ Robert S.D. Higgins, MD,¹ and Kaushik Mandal, MD³

INTRODUCTION

The introduction of highly active antiretroviral therapy (HAART) has significantly increased life expectancy for patients with HIV infection. End-stage organ failure has supplanted AIDS and opportunistic infections as the leading cause of mortality among HIV-infected (HIV+) individuals.¹ The prevalence of heart disease in this population is heightened by factors such as HIV-associated cardiomyopathy, increased coronary atherosclerosis, and toxicity from antiretrovirals such as abacavir.²

Although no longer considered an absolute contraindication, heart transplantation for HIV+ recipients remains rare.³ Initial outcomes appear promising,¹ but the complication profile in this population is poorly understood.⁴ We present a case of an HIV+ patient undergoing orthotopic heart transplantation complicated by disseminated intravascular coagulation (DIC). We believe this is the first reported case of this complication following heart transplantation in an HIV+ recipient.

CASE DESCRIPTION

A 48-year-old HIV+ man with familial nonischemic cardiomyopathy was hospitalized for an acute heart failure

exacerbation. His HIV infection had been well-controlled since 2015, with a CD4 count of 788 cells/mm³ and undetectable plasma RNA at the time of admission. His HAART regimen, consisting of raltegravir, tenofovir, and emtricitabine, had been designed to avoid exacerbating his heart disease or interacting with immunosuppressive medications, with the expectation that he would require transplantation in the future. Because he required pulmonary artery catheter-guided inotropic therapy, he was evaluated by the heart transplant review committee and listed for transplant as status 1A per 2017 Organ Procurement and Transplantation Network criteria. After a 2-month inpatient hospitalization, a heart became available from an HIV-uninfected donor well matched by size and blood group. He underwent orthotopic heart transplantation without surgical complication. Total ischemic time was 306 minutes. Cross-match was negative for donor-specific antibodies, and his immunosuppression comprised of basiliximab, steroids, mycophenolate mofetil, and tacrolimus.

His immediate postoperative course was notable for isolated right heart failure resulting in cardiogenic shock. Before transplantation, his pulmonary arterial pressure and pulmonary vascular resistance had been within normal limits on inotropic support. Despite attempts at right ventricular afterload reduction with inhaled nitric oxide, his worsening right heart function resulted in acute renal failure, volume overload, and hypoxemic respiratory failure. Continuous venovenous hemodialysis was initiated on postoperative day 1, and he required reintubation and intra-aortic balloon pump placement on postoperative day 3.

On postoperative day 2, he developed progressively painful duskeness of his fingers and toes bilaterally, which evolved into dry gangrene over the ensuing weeks. This was initially attributed to vasopressor-dependent peripheral hypoperfusion. However, laboratory testing revealed thrombocytopenia with a nadir platelet count of 16 000/mm³ and fibrinogen levels of 44 mg/dL on postoperative day 6, concerning for DIC (Figure 1). Heparin-induced thrombocytopenia was excluded by negative serotonin release and heparin-platelet factor 4 enzyme-linked immunosorbent assays. Given the suspicion for DIC, Doppler ultrasonography was performed, demonstrating nonocclusive thrombi of the left subclavian and bilateral internal jugular and brachiocephalic veins. He was systemically anticoagulated with heparin. On postoperative

Received 9 January 2019. Revision received 7 February 2019.

Accepted 3 March 2019.

¹ Division of Cardiac Surgery, Johns Hopkins Hospital, Baltimore, MD.

² Carnegie Mellon University, Pittsburgh, PA.

³ Division of Cardiac Surgery, Milton S. Hershey Medical Center, Pennsylvania State University, Hershey, PA.

X.Z. participated in the writing of the manuscript. M.M. and A.K. participated in the data abstraction and writing of the manuscript. A.S.-P., C.D.F., G.J.R.W., R.S.D.H., and K.M. participated in review and revision of the manuscript.

The authors declare no funding or conflicts of interest.

Correspondence: Xun Zhou, MD, Blalock Building, Room 1265, 600 North Wolfe St, Baltimore, MD 21287. (xzhou31@jhmi.edu).

Copyright © 2019 The Author(s). Transplantation Direct. Published by Wolters Kluwer Health, Inc. This is an open-access article distributed under the terms of the Creative Commons Attribution-Non Commercial-No Derivatives License 4.0 (CCBY-NC-ND), where it is permissible to download and share the work provided it is properly cited. The work cannot be changed in any way or used commercially without permission from the journal.

ISSN: 2373-8731

Transplantation Direct 2019;5:e444; doi: 10.1097/TXD.0000000000000892.

Published online 15 April, 2019.

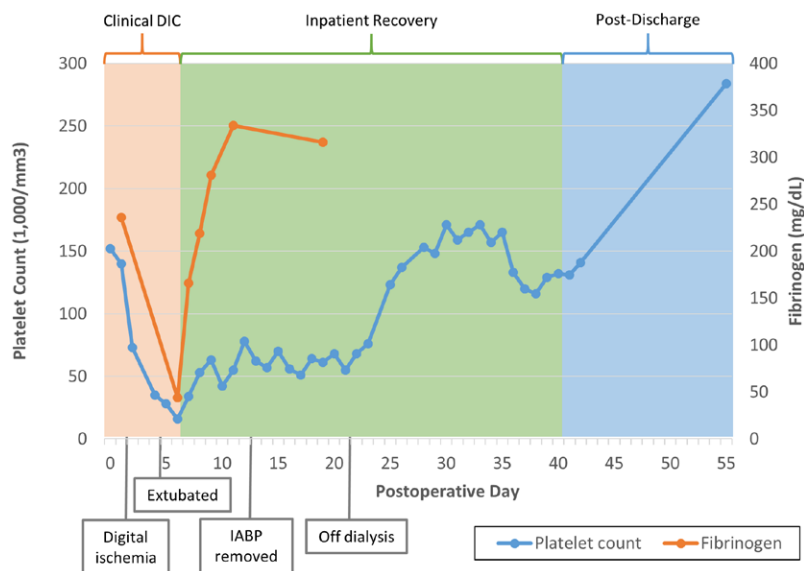


FIGURE 1. Postoperative platelet count and fibrinogen levels. DIC, disseminated intravascular coagulation; IABP, intra-aortic balloon pump.

day 13, he was found to have a decreasing hemoglobin, and computed tomography revealed a retroperitoneal hematoma, requiring discontinuation of his anticoagulation. His fibrinogen and platelet count gradually increased over the remainder of his hospital course to 316 mg/dL and 179 000/mm³, respectively, by the time of discharge on postoperative day 41. Ultimately, he required a total of 8 days of balloon pump support, 1 day of mechanical ventilation, and 21 days of renal replacement therapy before cardiac, pulmonary, and renal function improved to baseline.

A myocardial biopsy performed on postoperative day 22 showed grade 2R rejection, which improved to grade 0 following pulse-dose steroids. At 1-year follow-up, he had good cardiac function with no heart failure symptomatology. Repeat biopsy demonstrated mild rejection, grade 1R, not requiring modification to his immunosuppression. His HIV infection remained well-controlled on his pretransplant antiretroviral regimen throughout his hospitalization and subsequent follow-up, with undetectable viral load and stable CD4 counts.

DISCUSSION

Outcomes for HIV+ patients have dramatically improved since the widespread use of HAART. In many patients, the development of AIDS can be avoided, resulting in similar life expectancy as the general population.¹ The United Network for Organ Sharing first proposed removing HIV as a contraindication for organ transplantation in 2001, resulting in a steady increase in solid organ transplants being performed. Experiences with HIV+ liver and kidney transplant have demonstrated that these patients have higher waitlist mortality before transplant⁵ and increased risk of rejection after transplant^{6,7} but do not appear to be at higher risk of opportunistic infection than HIV- recipients.⁸

Case reports of heart transplantation for HIV+ recipients remain limited. A systematic review of the PubMed database was performed using the MeSH terms “heart transplantation” and “HIV,” which identified 14 instances of HIV+ heart transplant (Table 1). All patients had well-controlled HIV, with undetectable plasma HIV RNA levels and CD4 cell counts

>250 cells/mm³ before transplant. Sixty percent of cases reported some degree of rejection, ranging from grade 1B to 3A. Most cases were uncomplicated, although severe anemia, neutropenic sepsis, and acute cholecystitis were reported.⁹ Multiple reports highlighted challenges titrating immunosuppressants due to presumed pharmacological interactions with antiretrovirals. Overall, these case reports demonstrate that good outcomes can be achieved for cardiac transplantation in HIV+ individuals with proper patient selection. The ideal candidate should have well-controlled disease and demonstrate the ability to be compliant with complex medication regimens.

Consideration of potential drug-drug interactions should be undertaken when evaluating HIV+ patients for potential heart transplantation. The pharmacokinetic interactions of immunosuppressants and antivirals can be difficult to predict, as even drugs within the same class can have varying effects on one another.¹⁰ Protease inhibitors and non-nucleoside reverse transcriptase inhibitors, 2 common classes of antiretrovirals, activate the cytochrome P450 family that metabolizes calcineurin inhibitors.¹¹ Raltegravir is an integrase inhibitor that undergoes cytochrome P450-independent glucuronidation and may be a good choice in this context. Similarly, nucleoside reverse transcriptase inhibitors are metabolized via glucuronidation or direct renal excretion.¹² The combination of raltegravir and 2 nucleoside reverse transcriptase inhibitors has been shown to be well tolerated in HIV+ patients receiving kidney and liver transplants and minimizes the need to adjust calcineurin inhibitor dosing.¹³

While the general management of DIC can be challenging, the intricacies of HIV+ heart transplant necessitate close communication between multiple teams of physicians. A systematic approach was taken to rule out common causes of DIC in postoperative, HIV+, and heart failure patients, such as sepsis, transfusion reactions, and acute hepatic failure. Although AIDS patients may develop sepsis-related DIC, the complication is rare in patients with well-controlled HIV.¹⁴ Chronic HIV infection has been postulated to contribute to a low-grade hypercoagulable state, which may increase the risk of DIC.¹⁵ The etiology in our patient was likely multifactorial,

TABLE 1.
Summary of heart transplant in HIV+ recipients reported in the literature

Year	Gender	Age	HAART regimen at transplant	CD4 count at transplant (/mm ³)	Etiology of heart disease	Bridged to transplant?	Initial immunosuppression regimen	Complications	Rejection?
2001	Male	42	Not described	637	Dilated cardiomyopathy	No	Cyclosporine, mycophenolate mofetil, prednisone, daclizumab	None reported	Yes/NR
2001	Male	39	Zidovudine, lamivudine, ritonavir	>250	Anthracycline-associated cardiomyopathy	No	Cyclosporine, mycophenolate mofetil, prednisone	Autoimmune thrombocytopenia, transfusion-dependent anemia	Yes/3A
2005	Male	47	Not described	443	Dilated cardiomyopathy	No	Cyclosporine, mycophenolate mofetil, prednisone, daclizumab	None reported	Yes/NR
2007	Male	29	Not described	536	Dilated cardiomyopathy	No	Cyclosporine, mycophenolate mofetil, prednisone, daclizumab	None reported	Yes/NR
2007	Male	39	Zidovudine, lamivudine, abacavir	>500	Ischemic heart disease	No	Tacrolimus, mycophenolate mofetil, prednisone, basiliximab	None reported	Yes/3A
2008	Female	43	Not described	793	Dilated cardiomyopathy	No	Cyclosporine, mycophenolate mofetil, prednisone, daclizumab	None reported	No
2008	Male	32	Lamivudine, zidovudine, raltegravir, enfuvirtide	700	Dilated cardiomyopathy	IABP	Not reported	None reported	Yes/2R
2008	Male	48	Not described	279	Dilated cardiomyopathy	VentriAssist	Cyclosporine, mycophenolate mofetil, prednisone, daclizumab	None reported	No
2009	Male	36	Zidovudine, lamivudine, efavirenz	>1000	Dilated cardiomyopathy	No	Cyclosporine, everolimus, prednisone, antithymocyte globulin	None reported	Yes/2R
2009	Female	42	Not described	>450	Nonischemic cardiomyopathy	HeartMate II	Tacrolimus, mycophenolate mofetil, prednisone	None reported	Yes/NR
2011	Male	42	Not described	Not reported	Dilated cardiomyopathy	No	Not reported	None reported	No
2013	Male	44	Abacavir, lamivudine, etravirine, maraviroc	378	Ischemic heart disease	HeartWare	Tacrolimus, mycophenolate mofetil, prednisone	None reported	No
2014	Male	65	Darunavir, ritonavir, emtricitabine, tenofovir	580	Ischemic heart disease	No	Tacrolimus, mycophenolate mofetil, prednisone	Renovascular hypertension	No
2014	Male	66	Abacavir, lamivudine, raltegravir	750	Ischemic heart disease	No	Tacrolimus, mycophenolate mofetil, prednisone	Neutropenia	No
2016	Male	48	Raltegravir, tenofovir, and emtricitabine	788	Nonischemic cardiomyopathy	No	Tacrolimus, mycophenolate mofetil, prednisone	Disseminated intravascular coagulation	Yes/2R

HAART, highly active antiretroviral therapy; IABP, intra-aortic balloon pump.

resulting from a combination of a low-flow state from right heart failure, increased thrombogenicity from HIV, and platelet activation from the inflammatory stress of transplant surgery. While the mantra of DIC management is to treat the underlying trigger, multifactorial etiologies are more difficult to manage. These patients require an interdisciplinary approach to ensure that their regimen of inotropes, immunosuppressants, and antiretrovirals remain appropriate given evolving hematological, cardiac, and renal function.

The landscape of HIV+ transplantation is rapidly changing. In 2013, the HIV Organ Policy Equity Act¹⁶ lifted the long-standing prohibition on the use of HIV+ donor organs, which may improve access to transplantation for HIV+ recipients.¹⁷ However, this approach may also subject vulnerable populations to additional risks such as superinfection, the loss of recipient viral control due to coinfection with the donor's strain of HIV.¹⁸ Additionally, the combination of heart transplant physiology, immunosuppression, and exposure to a novel strain of HIV may predispose these patients to currently unforeseen complications such as DIC. Without more data on outcomes in HIV+ recipients, it is difficult to weigh the risks and benefits of HIV+ donors in heart transplantation. Further study will be necessary to determine whether DIC in this patient population ultimately proves to be a common or important complication. Nonetheless, experience HIV+ donors in abdominal transplantation is encouraging, with similar 5-year survival and graft rejection rates following kidney¹⁹ and liver transplantation.²⁰ While no patients developed worsening of their viral control, many did require adjustments to their antiretroviral regimen to prevent interactions with immunosuppression.

Heart transplantation in HIV+ individuals is likely to become an increasingly common phenomenon, with important implications for clinical and public health. Because HIV and organ transplant immunosuppression affect physiology and biochemistry in complex and interrelated ways, it is possible for de novo risks and unusual complications to arise from their interaction. Given the limitations in our current understanding, further study is required to investigate and characterize the risks unique to this patient population and develop strategies to prevent them.

Consent was obtained from the patient per institutional review board policy and compliance with the Health Insurance Portability and Accountability Act.

REFERENCES

- Agüero F, Castel MA, Cocchi S, et al. An update on heart transplantation in human immunodeficiency virus-infected patients. *Am J Transplant.* 2016;16:21–28.
- Jahangiri B, Haddad H. Cardiac transplantation in HIV-positive patients: are we there yet? *J Heart Lung Transplant.* 2007;26:103–107.
- Boignard A, Blanc M, Chavanon O. High-urgency priority heart transplantation in HIV-positive patients on life support: breaking barriers? *J Heart Lung Transplant.* 2011;30:968–969.
- Richterman A, Blumberg E. The challenges and promise of HIV-infected donors for solid organ transplantation. *Curr Infect Dis Rep.* 2015;17:471.
- Ragni MV, Egtesad B, Schlesinger KW, et al. Pretransplant survival is shorter in HIV-positive than HIV-negative subjects with end-stage liver disease. *Liver Transpl.* 2005;11:1425–1430.
- Locke JE, Mehta S, Reed RD, et al. A national study of outcomes among HIV-infected kidney transplant recipients. *J Am Soc Nephrol.* 2015;26:2222–2229.
- Locke JE, Durand C, Reed RD, et al. Long-term outcomes after liver transplantation among human immunodeficiency virus-infected recipients. *Transplantation.* 2016;100:141–146.
- Stock PG, Barin B, Murphy B, et al. Outcomes of kidney transplantation in HIV-infected recipients. *N Engl J Med.* 2010;363:2004–2014.
- Uriel N, Jorde UP, Cotlaran V, et al. Heart transplantation in human immunodeficiency virus-positive patients. *J Heart Lung Transplant.* 2009;28:667–669.
- Frassetto L, Floren L, Barin B, et al. Changes in clearance, volume and bioavailability of immunosuppressants when given with HAART in HIV-1 infected liver and kidney transplant recipients. *Biopharm Drug Dispos.* 2013;34:442–451.
- Teicher E, Vincent I, Bonhomme-Faivre L, et al. Effect of highly active antiretroviral therapy on tacrolimus pharmacokinetics in hepatitis C virus and HIV co-infected liver transplant recipients in the ANRS HC-08 study. *Clin Pharmacokinet.* 2007;46:941–952.
- Conte AH, Kittleson MM, Dilibero D, et al. Successful orthotopic heart transplantation and immunosuppressive management in 2 human immunodeficiency virus-seropositive patients. *Tex Heart Inst J.* 2016;43:69–74.
- Tricot L, Teicher E, Peytavin G, et al. Safety and efficacy of raltegravir in HIV-infected transplant patients cotreated with immunosuppressive drugs. *Am J Transplant.* 2009;9:1946–1952.
- Fera G, Semeraro N, De Mitrio V, et al. Disseminated intravascular coagulation associated with disseminated cryptococcosis in a patient with acquired immunodeficiency syndrome. *Infection.* 1993;21:171–173.
- Feffer SE, Fox RL, Orsen MM, et al. Thrombotic tendencies and correlation with clinical status in patients infected with HIV. *South Med J.* 1995;88:1126–1130.
- Health Resources and Services Administration (HRSA), Department of Health and Human Services (HHS). Organ procurement and transplantation: implementation of the HIV Organ Policy Equity Act. Final rule. *Fed Regist.* 2015;80:26464–26467.
- Boyersky BJ, Hall EC, Singer AL, et al. Estimating the potential pool of HIV-infected deceased organ donors in the United States. *Am J Transplant.* 2011;11:1209–1217.
- Boyersky BJ, Durand CM, Palella FJ Jr, et al. Challenges and clinical decision-making in HIV-to-HIV transplantation: insights from the HIV literature. *Am J Transplant.* 2015;15:2023–2030.
- Muller E, Barday Z, Mendelson M, et al. HIV-positive-to-HIV-positive kidney transplantation—results at 3 to 5 years. *N Engl J Med.* 2015;372:613–620.
- Hathorn E, Smit E, Elsharkawy AM, et al. HIV-positive-to-HIV-positive liver transplantation. *N Engl J Med.* 2016;375:1807–1809.