

A Rare Q-Fever Infection Diagnosed Using Metagenomic Next-Generation Sequencing in Liver Transplantation Patient: A Case Report and Literature Review

Xinxin Niu^{1,*}, Shuang Qiu^{1,*}, Yafeng Zheng^{2,*}, Li Li¹, Eryun Tian¹, Jie Liu¹, Wei Gai², Qing Zhang¹, Hailong Jin¹

¹Department of Organ Transplantation, The Third Medical Center of Chinese PLA General Hospital, Beijing, People's Republic of China; ²WillingMed Technology (Beijing) Co., Ltd, Beijing, People's Republic of China

*These authors contributed equally to this work

Correspondence: Qing Zhang; Hailong Jin, Department of Organ Transplantation, The Third Medical Center of Chinese PLA General Hospital, Beijing, 100039, People's Republic of China, Email zqy6920@sina.com; jhl309@sina.com

Abstract: Q fever is a zoonotic disease caused by the Gram-negative bacterium *Coxiella burnetii*, typically transmitted through exposure to infected animal secretions. As the clinical signs of Q-fever are largely non-specific in humans, a definitive diagnosis can often be overlooked, particularly when physicians fail to consider *C. burnetii* on the list of differentials. This case report describes Q-fever in a male patient who had previously undergone orthotopic liver transplantation. The patient had a sudden onset of fever and received the anti-infective moxifloxacin which proved ineffective. Despite the comprehensive laboratory tests and CT imaging that were performed, the etiology remained undetermined. The patient's blood was subjected to metagenomic next-generation sequencing (mNGS), which identified *C. burnetii*, after which the patient was treated with doxycycline and recovered well. Eight literature articles on Q fever infection in solid organ transplant recipients were reviewed. To our knowledge, this is the first case of Q fever identified by mNGS in an organ transplantation patient. The case underscores the potential of mNGS has in aiding the rapid detection of rare pathogens in immunocompromised patients.

Keywords: Q-fever, metagenomic next-generation sequencing, case report, liver transplant, *Coxiella burnetii*

Introduction

Q fever is a zoonotic disease caused by *Coxiella burnetii* which is highly contagious Gram-negative bacterial pathogen.¹ *Coxiella burnetii* is prevalent in wild animals, and domestic animals, including goats, sheep, cattle, birds, along with pets such as dogs and cats.² The primary transmission routes to humans are through the consumption of unpasteurized dairy products, inhalation of pathogen-laden aerosols, and potentially tick bites.

Given the atypical clinical presentations and imaging findings associated with Q fever, misdiagnosis and/or delayed diagnoses may be frequent, paving way to multi-organ misfunction or even death, particularly when treatment is delayed.¹ Diagnosis of *C. burnetii* is typically reliant on nucleic acid-based and serological testing methods.¹ However, these techniques are not routinely available in many clinical laboratories, and the biosecurity requirements for handling *C. burnetii* are not always available in most clinical settings. As such metagenomic next-generation sequencing (mNGS) offers a comprehensive detection range, encompassing difficult -to-culture microorganisms, thereby serving as an effective diagnostic tool for infections caused by rare and deadly pathogens.³

Solid organ transplant recipients, who require prolonged use of immunosuppressive therapy post-surgery, are more predisposed to opportunistic infections. Clinical reports of Q fever among solid organ transplant recipients are infrequent.

Here we present a case report of acute Q fever in a liver transplant recipient, diagnosed rapidly using mNGS and successfully treated.

Case Report

The patient was a 41-year-old male dentist who presented with a sudden onset of fever on September 12, 2023, peaking at 38.9°C (Figure 1). He reported chills, cold intolerance, headache, and muscle pain in the neck and shoulders. Laboratory results revealed normal white blood cell (WBC) count and neutrophil percentage (NEU%) (Figure 2A), but an elevated aspartate aminotransferase (AST) level (Figure 2B). Tests for COVID-19, influenza A, and influenza B viruses were negative. A chest CT scan showed no inflammatory lesions. On September 16, the patient’s C-reactive protein (CRP) level was 29.83 mg/L (Figure 2C), with a WBC count of $6.51 \times 10^9/L$ and a NEU% of 61.70% (Figure 2A). Despite self-administering ibuprofen, his symptoms persisted. By September 18, the CRP level had decreased to 22.9 mg/L (Figure 2C), and blood tests showed a WBC count of $8.31 \times 10^9/L$, NEU% of 57.5% (Figure 2A), red blood cell (RBC) count of $5.55 \times 10^{12}/L$, and hemoglobin (HGB) level of 161 g/L. Liver function tests indicated elevated alanine aminotransferase (ALT) at 100.3 U/L and AST at 58.2 U/L (Figure 2B), with other liver

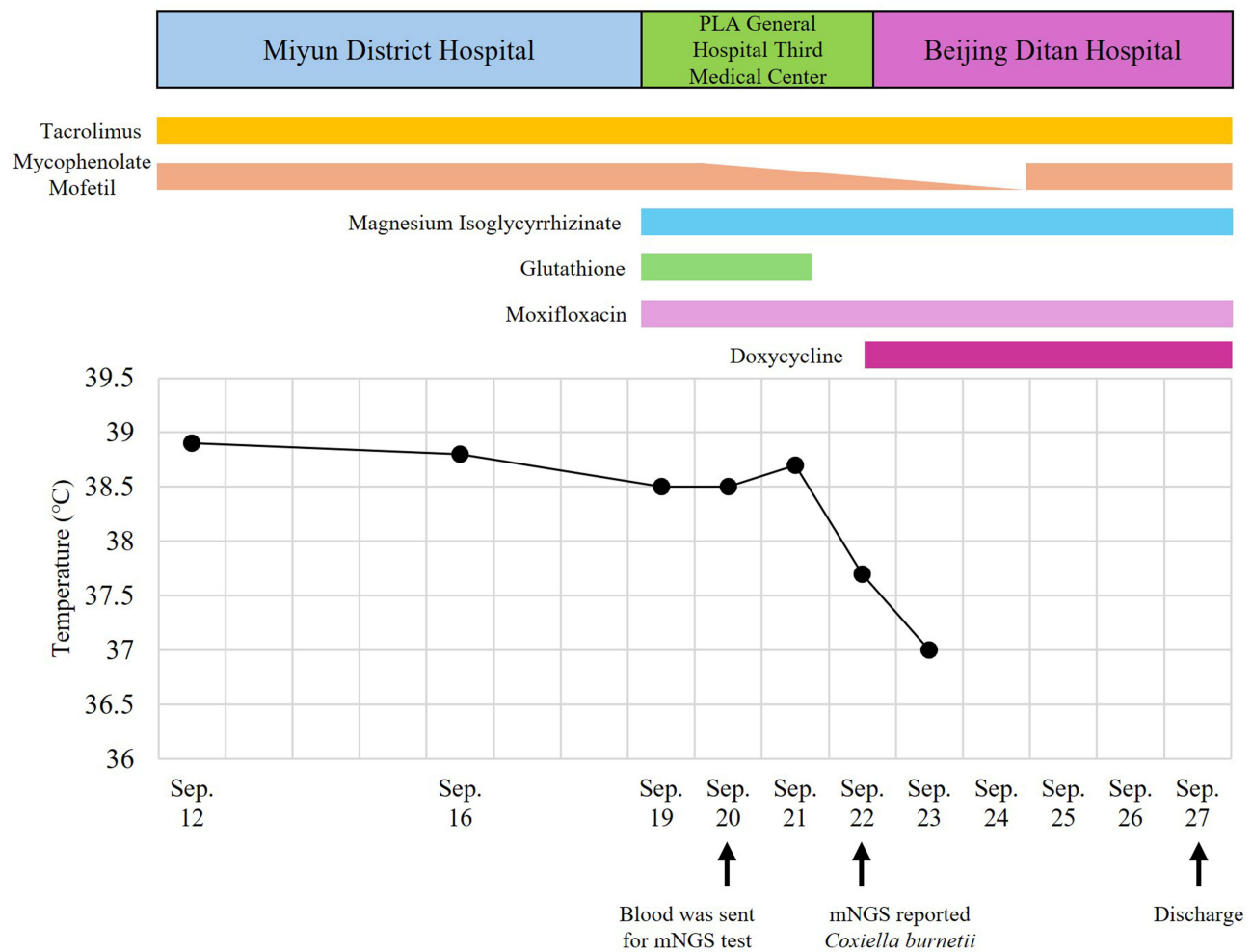


Figure 1 Longitudinal analysis of temperature change and therapeutic drug. The patient initially received examinations and treatment at Miyun District Hospital during his illness and was subsequently transferred to PLA General Hospital Third Medical Center for inpatient care. Upon the detection of *Coxiella burnetii* through mNGS, the patient was transferred to Beijing Ditan Hospital. Anti-rejection treatment encompassed the administration of Tacrolimus and Mycophenolate mofetil as drugs. A reduction in the dosage of Mycophenolate mofetil occurred during the treatment. The patient underwent liver protection therapy involving the use of Magnesium Isoglycyrrhizinate and Glutathione. Anti-infection treatment consisted of the administration of Moxifloxacin and Doxycycline. The line graph depicted the changes in the patient’s body temperature.

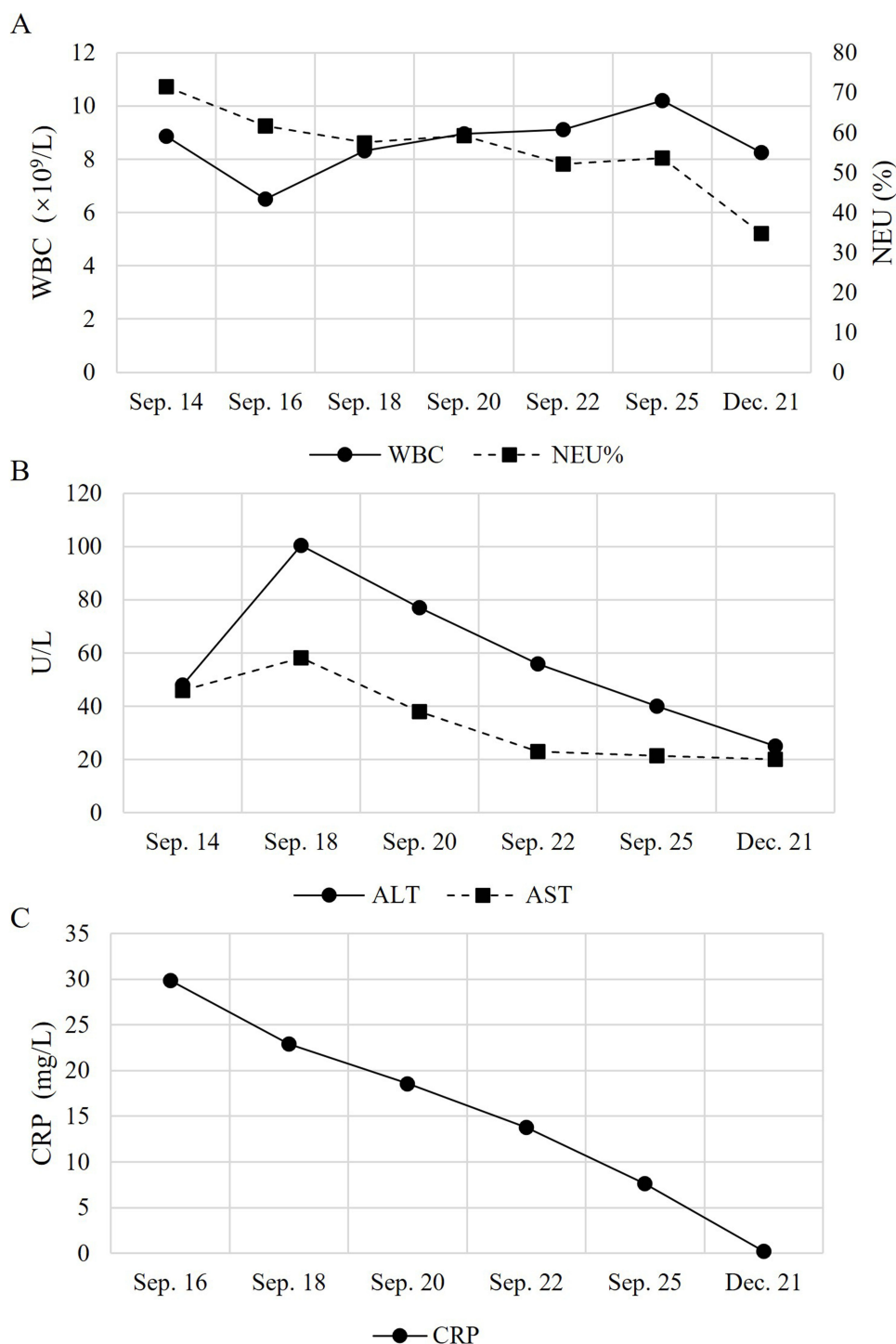


Figure 2 The patient's laboratory dynamic monitoring indicators. **(A)** The dynamic monitoring of patient's white blood cells (WBC)(left y-axis) and percentage of neutrophil (NEU%) (right y-axis). **(B)** The dynamic monitoring of patient's alanine transaminase (ALT) and aspartate aminotransferase (AST). **(C)** The dynamic monitoring of patient's C-reactive protein (CRP).

function parameters remained normal. On September 19, the patient was admitted to the Third Medical Center of Organ Transplantation at the Chinese PLA General Hospital.

The patient had a history of decompensated liver cirrhosis secondary to hepatitis B and underwent orthotopic liver transplantation in 2017. He denied any history of tuberculosis, malaria, or other infectious diseases, as well as diabetes, heart disease, and cerebrovascular disease. Upon admission, he was treated with intravenous moxifloxacin for anti-

infection therapy, along with glutathione and magnesium for liver protection. However, on the second day, his peak temperature rose to 38.5°C, accompanied by headache and neck and shoulder pain. Pathogen screenings were negative for *Mycoplasma pneumoniae*, *Chlamydia pneumoniae*, *Respiratory syncytial virus*, *Adenovirus*, *Coxsackie virus*, and SARS-Cov-2. Additionally, tests for autoantibodies and tuberculin gamma interferon were all negative. Cancer antigen tumor markers were within normal ranges, and viral panel tests for *Rubella virus*, cytomegalovirus, and herpes simplex virus showed no abnormalities.

Due to the patient's persistent fever lasting over a week and negative pathogen screening results, mNGS was performed on a blood sample on the second day of admission. mNGS identified *Coxiella burnetii* in the plasma (Supplementary Table 1). Based on the patient's symptoms, physical examination findings, and response to anti-infective treatment, a preliminary diagnosis of Q fever was established. Considering the short duration of illness, the Q fever was classified as acute. Subsequently, the patient was transferred to a specialized infectious disease hospital for further management. Treatment included oral doxycycline hydrochloride (100 mg twice daily), intravenous moxifloxacin (400mg once daily), and liver protection therapy with magnesium isoglycyrrhizinate injection (100 mg once daily). The patient's fever resolved on the second day of admission and did not recur thereafter (Figure 1). After 6 days of hospitalization, the patient recovered and was discharged. Post-discharge, the patient continued taking doxycycline hydrochloride tablets for 12 days, completing a total of 18 days of treatment. At a follow-up visit two months later, laboratory tests revealed a CRP level of 0.23 mg/L, WBC count of $8.26 \times 10^9/L$, NEU% of 34.8%, ALT of 25 U/L, and AST of 20 U/L (Figure 2).

Discussion

In this case, a 41-year-old liver transplant recipient presented with persistent fever and nonspecific symptoms such as myalgia and headache, leading to initial diagnostic uncertainty. Conventional diagnostic methods, including serological and PCR testing for common pathogens, yielded negative results. Given the diagnostic challenges, mNGS was employed on the second day of hospitalization, promptly identifying *C. burnetii* in the patient's plasma. This facilitated the diagnosis of acute Q fever and allowed for the immediate initiation of doxycycline therapy, leading to fever resolution within two days and recovery after 18 days of treatment.

Q fever, a zoonotic disease caused by *C. burnetii*, exhibits substantial epidemiological variability. In 2021, its incidence rate was estimated at 0.11 per 100,000 individuals by the European Food Safety Authority and the European Centre for Disease Prevention and Control.⁴ An outbreak of Q fever occurred in the Netherlands from 2007 to 2010.⁵ Since then, preventative measures have been implemented, reducing the annual incidence to preoutbreak levels. During the period from 2009 to 2019, the average annual incidence rate was reported as 171.2 cases per 10 million people, which decreased to 10.8 cases per 10 million people from 2015 to 2019.⁵ Chronic Q fever can manifest years post initial infection, primarily as vascular infection or endocarditis, potentially leading to life-threatening complications like acute aortic aneurysm and heart failure, with a high mortality rate.^{6,7} Hence, prompt diagnosis and treatment of acute Q fever are crucial.

Epidemiological studies have identified age, gender, and occupation as key risk factors for Q fever, with a higher prevalence observed in individuals aged 15 and above, and a male-to-female ratio of 2.5:1.⁸ High-risk occupational groups encompass individuals in contact with animals (such as farmers, slaughterhouse workers, and veterinarians) and laboratory personnel handling bacteria cultures.⁸ Prolonged use of immunosuppressants following solid organ transplant also increases the risk of Q fever. In this case, the patient was a dentist who had undergone orthotopic liver transplantation five years ago, suggesting a potential occupational risk. However, he had neither direct contact with animals nor consumed unpasteurized dairy products, and the exact mode of transmission remains unclear.

The incubation period of acute Q fever typically spans 2–3 weeks before the onset of symptoms, with up to 50% of hosts being asymptomatic.^{9,10} Symptomatic individuals often exhibit nonspecific symptoms, including fever, muscle pain, headache, chills, cough, abdominal pain, nausea, vomiting, and diarrhea. Traditional diagnostic methods, including serological testing, culture, and PCR, often require specialized laboratory facilities and are unavailable in many hospitals, creating diagnostic gaps in clinical practice. The nonspecific symptoms of Q fever, combined with inadequate awareness among healthcare professionals, can result in misdiagnosis or delayed diagnosis. These limitations were effectively

overcome in our case using mNGS, which enabled rapid and accurate identification of *C. burnetii* and facilitated timely treatment. Plasma cell-free DNA testing has been used in diagnosing various infectious diseases, including bloodstream infections, pulmonary and extrapulmonary tuberculosis, invasive fungal infections, endocarditis, urinary tract infections, and secondary infections post-solid organ transplantation.¹¹ mNGS has demonstrated high value in detecting clinically rare pathogens. Nevertheless, there are no reports on the use of mNGS for diagnosing Q fever in solid organ transplant recipients.

The standard treatment for acute Q fever involves a two-week course of doxycycline. If treatment is incomplete, chronic Q fever may develop. Chronic Q fever requires prolonged combination antibiotic therapy, such as doxycycline with hydroxychloroquine or a quinolone. The optimal treatment duration for Q fever after solid organ transplantation remains uncertain, often requiring prolonged treatment in immunocompromised individuals. In our scenario, the patient developed acute Q fever. Prompt mNGS-based diagnosis allowed targeted doxycycline therapy, leading to rapid symptom resolution, and normalization of inflammatory markers. Moreover, no signs of chronic Q fever were observed during follow-up, underscoring the importance of early intervention.

This study reviewed 8 literature articles on Q fever infection in solid organ transplant recipients ([Supplementary Table 2](#)). Unlike the general population, transplant recipients often exhibit nonspecific symptoms of Q fever, increasing the likelihood of misdiagnosis. Diagnosis often relies on serological testing, with definitive diagnosis typically taking 5 days to 6 weeks ([Supplementary Table 2](#)), potentially resulting in chronic Q fever or suspected chronic Q fever. While most patients respond well to active treatment, a case involving a female child who underwent liver-thymus transplant showed improvement in serological markers post-Q fever treatment but unfortunately succumbed to leukemia bone marrow relapse.¹² Early detection and treatment of Q fever may facilitate continued anti-leukemia treatment and potentially prevent fatalities. Lindsay and Petty¹³ documented a case of Q fever in a liver transplant recipient where serological markers remained abnormal after treatment. A year later, there was a possible development of chronic Q fever, which responded positively to combination therapy. Similarly, in our case, both liver transplant recipients infected with Q fever had no history of animal contact or consumption of unpasteurized dairy products. Prompt diagnosis using mNGS followed by timely doxycycline treatment resulted in rapid normalization of temperature and clinical symptoms, and no signs of potential chronic Q fever infection later.

This case underscores the importance of considering Q fever in solid organ transplant recipients with unexplained fever. The rapid identification of *C. burnetii* using mNGS and prompt initiation of targeted therapy were pivotal to achieving a favorable clinical outcome. This case highlights mNGS as an essential diagnostic tool in managing rare infections in immunocompromised patients, offering significant benefits in terms of speed, accuracy, and patient outcomes.

Data Sharing Statement

Data is not publicly available. Further inquiries can be directed to the corresponding authors.

Ethical Approval Statement

The studies involving human participants were reviewed and approved by the research ethics board of the Third Medical Center of Chinese PLA General Hospital (approval no. 2023-182). Written informed consent was obtained from the individual for the publication of any potentially identifiable images or data included in this article. The liver was voluntarily donated with written informed consent, and this was conducted in accordance with the Declaration of Istanbul.

Author Contributions

All authors made a significant contribution to the work reported, whether that is in the conception, study design, execution, acquisition of data, analysis and interpretation, or in all these areas; took part in drafting, revising or critically reviewing the article; gave final approval of the version to be published; have agreed on the journal to which the article has been submitted; and agree to be accountable for all aspects of the work.

Funding

The authors declare that no financial support was received for the research, authorship, and/or publication of this article.

Disclosure

All authors declare that they have no conflicts of interest in this work.

References

1. Anderson A, Bijlmer H, Fournier P-E, et al. Diagnosis and management of Q fever--United States, 2013: recommendations from CDC and the Q Fever Working Group. *MMWR Recomm Rep*. 2013;62:1–30.
2. Guzman RM, Voth DE. Embracing multiple infection models to tackle Q fever: a review of in vitro, in vivo, and lung ex vivo models. *Cell Immunol*. 2024;405–406:104880. doi:10.1016/j.cellimm.2024.104880
3. Gu W, Miller S, Chiu CY. Clinical metagenomic next-generation sequencing for pathogen detection. *Annu Rev Pathol*. 2019;14:319–338. doi:10.1146/annurev-pathmechdis-012418-012751
4. European Food Safety Authority, European Centre for Disease Prevention and Control. The European Union One Health 2021 zoonoses report. *EFSA J*. 2022;20:e07666. doi:10.2903/j.efsa.2022.7666
5. Broertjes J, Franz E, Friesema IH, et al. Epidemiology of pathogens listed as potential bioterrorism agents, the Netherlands, 2009–2019. *Emerg Infect Dis*. 2023;29:1–9. doi:10.3201/eid2907.221769
6. van Roeden SE, Wever PC, Kampschreur LM, et al. Chronic Q fever-related complications and mortality: data from a nationwide cohort. *Clin Microbiol Infect*. 2019;25:1390–1398. doi:10.1016/j.cmi.2018.11.023
7. Reukers DFM, de Boer PT, Loohuis AO, et al. Targeted screening for chronic Q fever, the Netherlands. *Emerg Infect Dis*. 2022;28:1403–1409. doi:10.3201/eid2807.212273
8. Eldin C, Mélenotte C, Mediannikov O, et al. From Q fever to *Coxiella burnetii* infection: a paradigm change. *Clin Microbiol Rev*. 2017;30:115–190. doi:10.1128/CMR.00045-16
9. España PP, Uranga A, Cillóniz C, Torres A. Q Fever (*Coxiella Burnetii*). *Semin Respir Crit Care Med*. 2020;41:509–521. doi:10.1055/s-0040-1710594
10. Jandhyala D, Farid S, Mahmood M, et al. Unrecognized pre-transplant disseminated *Coxiella burnetii* infection diagnosed in a post-transplant heart-kidney recipient. *Transpl Infect Dis*. 2018;20:e12962. doi:10.1111/tid.12962
11. Han D, Li R, Shi J, Tan P, Zhang R, Li J. Liquid biopsy for infectious diseases: a focus on microbial cell-free DNA sequencing. *Theranostics*. 2020;10:5501–5513. doi:10.7150/thno.45554
12. Loudon MM, Thompson EN. Severe combined immunodeficiency syndrome, tissue transplant, leukaemia, and Q fever. *Arch Dis Child*. 1988;63:207–209. doi:10.1136/adc.63.2.207
13. Petty LA, Te HS, Pursell K. A case of Q fever after liver transplantation. *Transpl Infect Dis*. 2017;19. doi:10.1111/tid.12737

Infection and Drug Resistance

Publish your work in this journal

Infection and Drug Resistance is an international, peer-reviewed open-access journal that focuses on the optimal treatment of infection (bacterial, fungal and viral) and the development and institution of preventive strategies to minimize the development and spread of resistance. The journal is specifically concerned with the epidemiology of antibiotic resistance and the mechanisms of resistance development and diffusion in both hospitals and the community. The manuscript management system is completely online and includes a very quick and fair peer-review system, which is all easy to use. Visit <http://www.dovepress.com/testimonials.php> to read real quotes from published authors.

Submit your manuscript here: <https://www.dovepress.com/infection-and-drug-resistance-journal>

Dovepress
Taylor & Francis Group