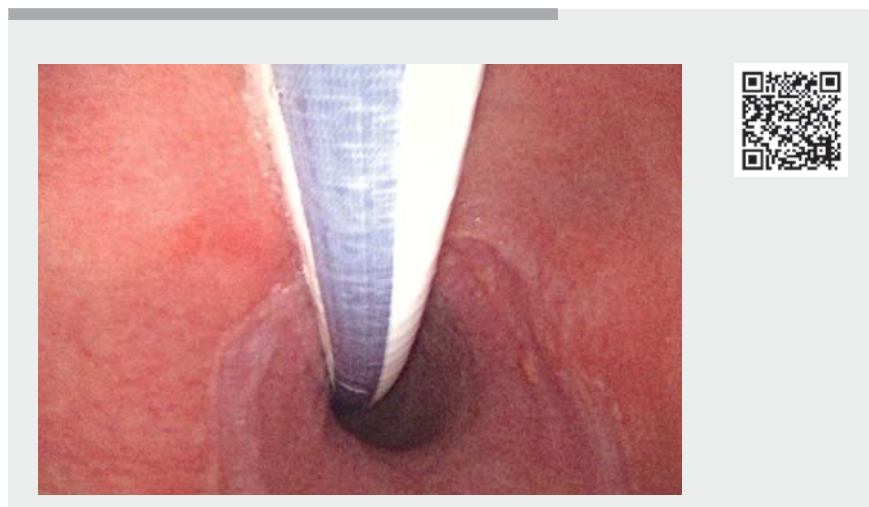
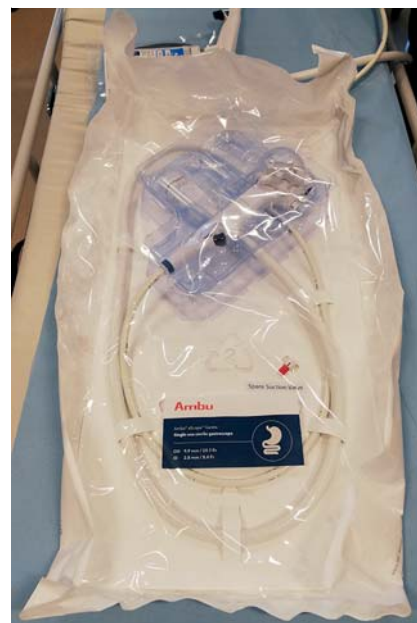

Diagnostic esophagogastroduodenoscopy performed using a novel sterile single-use disposable endoscope

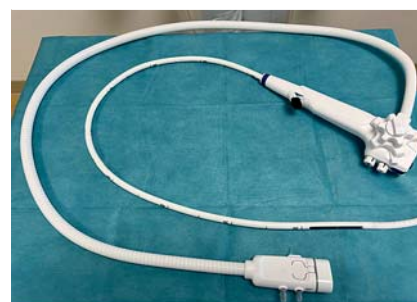
OPEN
ACCESS



▶ Video 1 Diagnostic esophagogastroduodenoscopy performed using the aScope Gastro. Use of the gastroscope is demonstrated. Biopsies are taken from the duodenum and antrum ventriculi. A hiatal hernia is visualized when looping in the stomach.



▶ Fig. 1 The aScope Gastro before unpacking.



▶ Fig. 2 The aScope Gastro after unpacking.

Growth of biofilm in the channels of endoscopes is common [1]. Damage to the channels, followed by formation of biofilm, may occur during both endoscopic procedures and the cleaning process. Biofilm is difficult to remove, and microbial contamination increases with the age of the endoscope [2]. The quality of reprocessing of endoscopes is believed to be associated with the contamination rate [3]. These aspects are not relevant for single-use endoscopes.

A 60-year-old woman with osteoporosis was referred for a diagnostic esophagogastroduodenoscopy (EGD) due to iron deficiency anemia. The patient had no gastrointestinal symptoms or symptoms of anemia. A colonoscopy with normal findings had been performed prior to referral. EGD was performed using a novel sterile single-use endoscope (Ambu aScope Gastro; Ambu, Ballerup, Denmark). The procedure was performed in our endoscopy unit by a junior medical doctor (▶ **Video 1**). The endoscope was

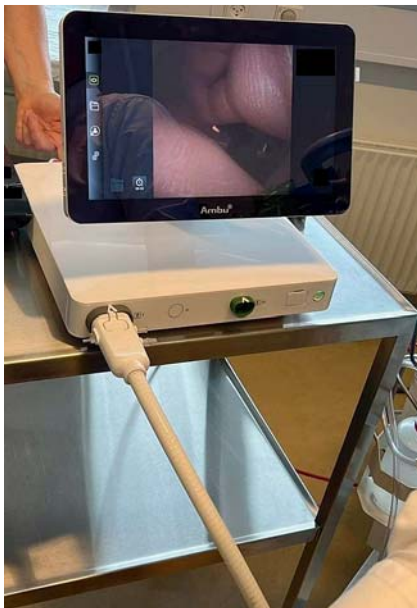unpacked in the endoscopy room (▶ **Fig. 1**, ▶ **Fig. 2**) and connected to the aBox (▶ **Fig. 3**). The patient was given a *local anesthetic* throat spray prior to intubation. No sedation was needed. Except for a hiatal hernia, there were no abnormal findings in the duodenum, stomach, or esophagus. Duodenal and gastric antral biopsies were taken.

The EGD was performed uneventfully and using the endoscope was feasible in terms of image quality and maneuverability. The complete single-use endoscope setup is more portable than the conventional setup because the aBox replaces existing endoscopic platforms. This enables the endoscopist to perform some procedures without moving the patient to the endoscopy unit or the operating room. Furthermore, there is no need for cleaning and repairs, which saves additional resources [4].

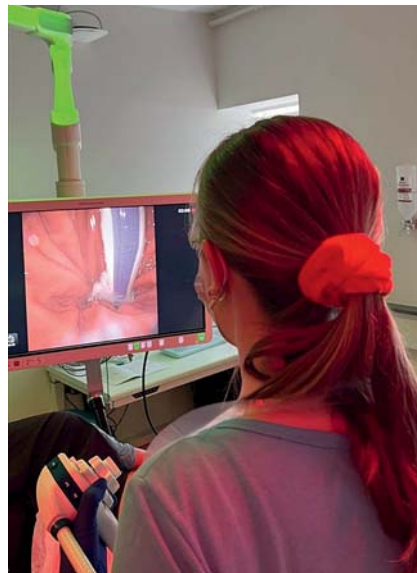Our case demonstrates a successful diagnostic EGD using the novel single-use disposable gastroscope (▶ **Fig. 4**). Sin-

gle-use endoscopes should be considered as an alternative when time and availability are essential.

Endoscopy_UCTN_Code_CCL_1AB_2AC_3AH



► **Fig. 3** The aBox 2 unit with the single-use gastroscop connected to it.



► **Fig. 4** A diagnostic esophagogastro-duodenoscopy performed using the aScope Gastro.

Competing interests

The authors declare that they have no conflict of interest.

The authors

Ronja Lagström¹, Trine Stigaard¹, Svend Knuhtsen¹, Mustafa Bulut^{1,2}

- 1 Department of Surgery, Zealand University Hospital, Koege, Denmark
- 2 Department of Clinical Medicine, University of Copenhagen, Copenhagen, Denmark

Corresponding author

Ronja Lagström, MD
 Zealand University Hospital, Lykkebækvej 1,
 4600 Koege, Denmark
 lagstromronja@gmail.com

References

- [1] Ren-Pei W, Hui-Jun X, Ke Q et al. Correlation between the growth of bacterial biofilm in flexible endoscopes and endoscope reprocessing methods. *Am J Infect Control* 2014; 42: 1203–1206
- [2] Saliou P, Le Bars H, Payan C et al. Measures to improve microbial quality surveillance of gastrointestinal endoscopes. *Endoscopy* 2016; 48: 704–710
- [3] Decristoforo P, Kaltseis J, Fritz A et al. High-quality endoscope reprocessing decreases endoscope contamination. *Clin Microbiol Infect* 2018; 24: 1101.e1–1101.e6
- [4] Scotland K, Wong VKF, Chan JYH et al. Evaluation of a single-use flexible cystoscope: a multi-institutional international study. *J Endourol* 2020; 34: 981–986

Bibliography

Endoscopy 2022; 54: E1034–E1035

DOI 10.1055/a-1915-5025

ISSN 0013-726X

published online 25.8.2022

© 2022. The Author(s).

This is an open access article published by Thieme under the terms of the Creative Commons Attribution-NonDerivative-NonCommercial License, permitting copying and reproduction so long as the original work is given appropriate credit. Contents may not be used for commercial purposes, or adapted, remixed, transformed or built upon. (<https://creativecommons.org/licenses/by-nc-nd/4.0/>)

Georg Thieme Verlag KG, Rüdigerstraße 14,
 70469 Stuttgart, Germany



ENDOSCOPY E-VIDEOS

<https://eref.thieme.de/e-videos>



Endoscopy E-Videos is an open access online section, reporting on interesting cases and new techniques in gastroenterological endoscopy. All papers include a high quality video and all contributions are freely accessible online. Processing charges apply (currently EUR 375), discounts and waivers acc. to HINARI are available.

This section has its own submission website at
<https://mc.manuscriptcentral.com/e-videos>