



Elsevier has created a [Monkeypox Information Center](#) in response to the declared public health emergency of international concern, with free information in English on the monkeypox virus. The Monkeypox Information Center is hosted on Elsevier Connect, the company's public news and information website.

Elsevier hereby grants permission to make all its monkeypox related research that is available on the Monkeypox Information Center - including this research content - immediately available in publicly funded repositories, with rights for unrestricted research re-use and analyses in any form or by any means with acknowledgement of the original source. These permissions are granted for free by Elsevier for as long as the Monkeypox Information Center remains active.



Monkeypox: A focused narrative review for emergency medicine clinicians

Brit Long, MD^a, Alex Koefman, MD^b, Michael Gottlieb, MD^c, Stephen Y. Liang, MD; MPH^d, Brandon M. Carius, DSc, MPAS, PA-C^e, Summer Chavez, DO, MPH, MPM^f, William J. Brady, MD^{g,*}

^a SAUSHEC Emergency Medicine, Brooke Army Medical Center, Fort Sam Houston, San Antonio, TX, United States of America

^b Department of Emergency Medicine, University of Texas Southwestern Medical Center, Dallas, TX, United States of America

^c Department of Emergency Medicine, Rush University Medical Center, Chicago, IL, United States of America

^d Divisions of Emergency Medicine and Infectious Diseases, Washington University School of Medicine, St. Louis, MO, United States of America

^e 121 Field Hospital, Camp Humphreys, US Army, Republic of Korea

^f Department of Health Systems and Population Sciences, University of Houston, Houston, TX, United States of America

^g Departments of Emergency Medicine and Medicine (Cardiovascular), University of Virginia School of Medicine, Charlottesville, VA, United States of America

ARTICLE INFO

Article history:

Received 2 August 2022

Received in revised form 10 August 2022

Accepted 14 August 2022

Keywords:

Monkeypox

Virus

Viral infection

Rash

Orthopoxvirus

Infectious disease

ABSTRACT

Introduction: Monkeypox is an emerging viral disease that has been declared a global health emergency. While this disease has been present for over 50 years, the recent surge in cases and expanding knowledge of this has prompted a need for a focused review for practicing clinicians.

Objective: This narrative review provides a focused overview of the epidemiology, presentation, evaluation, and management of monkeypox for emergency clinicians.

Discussion: Monkeypox is an orthopoxvirus endemic to central and western Africa. An outbreak in May and June 2022 across Asia, Europe, North America, and South America was declared a global health emergency in July 2022. The disease can be transmitted via contact with an infected animal or human, as well as contact with a contaminated material. The disease presents with a prodromal flu-like illness and lymphadenopathy. A rash spreading in a centrifugal manner involving the oral mucosa, face, palms, and soles is typical. Lesions progress along various stages. Complications such as bacterial skin infection, pneumonitis, ocular conditions, and encephalitis are uncommon. Confirmation typically includes polymerase chain reaction testing. The majority of patients improve with symptomatic therapy, and as of July 2022, there are no United States Food and Drug Administration-approved treatments specifically for monkeypox. However, antiviral treatment should be considered for several patient populations at risk for severe outcomes.

Conclusion: An understanding of the presentation, evaluation, and management of monkeypox is essential for emergency clinicians to ensure appropriate diagnosis and treatment of this emerging disease.

© 2022 Elsevier Inc. All rights reserved.

1. Introduction

Monkeypox is a viral zoonosis endemic to central and western Africa with the initial cases diagnosed over 50 years in the region; a zoonosis is an infectious disease that can be transmitted from animals to humans. On May 6, 2022, several cases of Monkeypox were confirmed in the United Kingdom (UK), originating from a UK resident who had traveled to Nigeria [1–3]. Additional clusters of cases have occurred in Asia, Europe, North America, and South America, with a rapid rise in cases leading the World Health Organization (WHO) to declare the current

monkeypox outbreak in non-endemic countries a global health emergency in July 2022; in early August 2022, the federal government of the United States made a similar declaration, noting that Monkeypox is a national health emergency. The majority of cases currently are not associated with travel to an endemic region [3,4]. Monkeypox classically presents with a rash that develops on the face and even oral mucosa and then spreads centrifugally. It may involve the palms and soles [5–9]. However, atypical presentations have been common in the present outbreak, including oral, perianal, and genital lesions as well as pharyngitis and proctitis [10,11]. The majority of cases improve with symptomatic therapy; complications are uncommon and can include encephalitis, ophthalmologic sequelae, pneumonitis, bacterial skin infections, and death. [5–7,12,13] During the recent past, the case fatality ratio has been approximately 3–6% [3]. As of August 2, 2022, there have been

* Corresponding author.

E-mail addresses: wb4z@uvahealth.org, wb4z@virginia.edu (W.J. Brady).

23,620 cases worldwide in over 80 countries [14]. Patients with signs and symptoms concerning for monkeypox will present to the emergency department (ED), so it is critical for the emergency medicine clinician to be aware of the current literature on this disease. This review will summarize the current information concerning the presentation, diagnosis, and management of monkeypox for the emergency medicine clinician.

2. Methods

The authors searched PubMed and Google Scholar for articles using the keyword “monkeypox”. Authors included case reports, case series, retrospective studies, prospective studies, systematic reviews and meta-analyses, clinical guidelines, narrative reviews, and online resources. The literature search was restricted to studies and resources published in English. Emergency physicians with experience in critical appraisal of the literature reviewed all of the resources and decided which resources to include for the review by consensus, with a focus on emergency medicine-relevant articles. A total of 90 resources were selected for inclusion in this review. Refer to [Flowchart 1](#) for methodology used in reference selection for this narrative review.

3. Discussion

3.1. Epidemiology

Monkeypox was originally discovered in 1958 as a vesicular rash present in monkeys transported to Denmark from Singapore for research, resulting in the name “monkeypox” [15,16]. The first human case was detected in 1970 in a 9-month-old in the Democratic Republic of the Congo (DRC) [15,17,18]. Since then, the virus has become endemic in 11 countries in central and western Africa, with most cases occurring in the DRC, followed by the Central African Republic, Nigeria, and Liberia [3,8,17,19–22].

Prior to the current outbreak, monkeypox had rarely been documented outside of central and western Africa. From 1970 to 1999, approximately 900 suspected cases were reported in Africa, with less than half being confirmed with testing [21]. An outbreak of 79 patients discovered in the midwestern United States in 2003 was attributed to ill rodents imported from Ghana that infected co-located pet prairie dogs distributed to the community [5,12,23,24]. Two patients from this outbreak had severe disease. One patient had encephalitis, and the other patient experienced airway compromise due to a retropharyngeal abscess with lymphadenopathy; neither patient died [5,12,13,23,24].

Since that time, sporadic, isolated cases have occurred in patients with connections to western Africa, primarily those returning from Nigeria, as well as direct contact with healthcare workers [25–30].

The current outbreak, however, does not reflect this previous pattern of transmission. The majority of patients affected by the virus in May through July 2022 have not traveled to endemic regions [19]. The epidemiology of this current outbreak initially focused on cases predominantly in the men who have sex with men (MSM) community between the ages of 20-to-50 years, and is suspected to stem from close skin-to-skin contact within sexual networks [19,31–35]. However, there are other routes of transmission, and contact with any lesion is the most likely form of transmission [1,6].

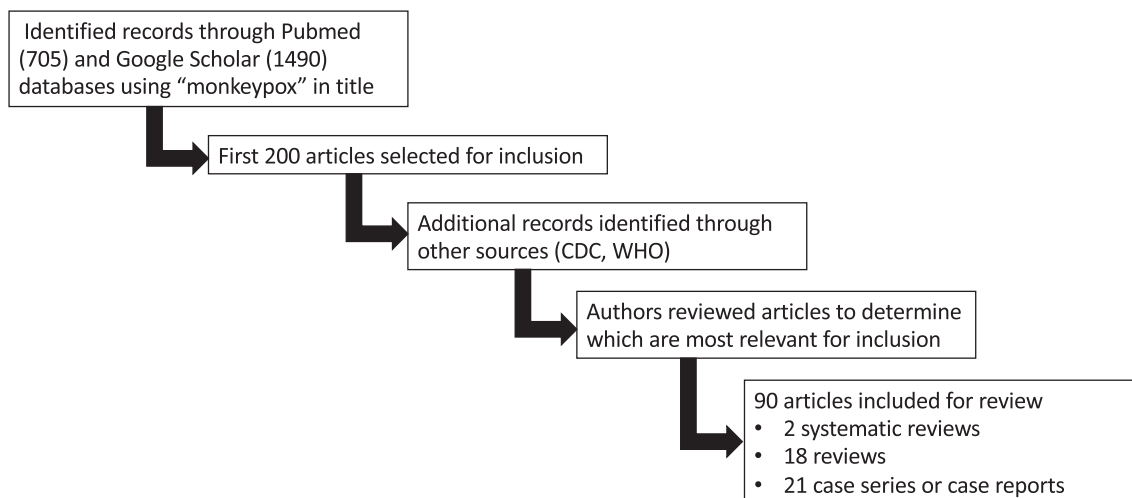
Of note, smallpox vaccination may be up to 85% effective for protecting against monkeypox, although data is limited to a single study published in 1988 [3]. Routine smallpox vaccination ended in the United States in 1972, with global eradication confirmed in 1980 [22,36–38]. The discontinuation of the smallpox vaccine may have allowed monkeypox to resurge and become endemic, with an increase in incidence in the DRC from 0.64 cases per 100,000 to 2.82 cases per 100,000 from 2001 to 2013 [3,36,39]. Similarly, many studies note disproportionate disease burden among younger patients, most born after smallpox eradication efforts were stopped, with the median age of patients ranging from 11 to 29 years of age [40–42].

3.2. Virology and pathophysiology

Monkeypox is a member of the genus Orthopoxvirus, which belongs to the Poxviridae family. The orthopoxvirus genus also contains smallpox and cowpox [1,3,20,21]. Monkeypox is a large virus measuring approximately 200–250 nm in size with an ovoid or “brick-like” appearance ([Fig. 1](#)) [1,8,25]. It has a lipoprotein membrane and is a double-stranded DNA virus [1,3,8,20].

Prior studies identified two distinct groups, or ‘clades’, of monkeypox: the Central African clade (commonly referred to as the “Congo Basin clade”) and the West African clade [8,21,22,43–45]. The Central African clade demonstrates higher virulence and infectivity, while the West African clade tends to be less severe [43,44]. The West African clade is suspected to be responsible for this current outbreak, as well as the 2003 outbreak [3]. Several mammalian species are susceptible to the virus including humans, primates, rope and tree squirrels, dormice, and Gambian pouched rats [3,8,20–22,45]. The most likely host reservoir is a rodent species rather than a monkey [3,8,20,45].

Human transmission occurs via animal-human or human-human spread. Indirect and direct contact with live or dead animals such as



Flowchart 1. Methodology used in reference selection for this narrative review.

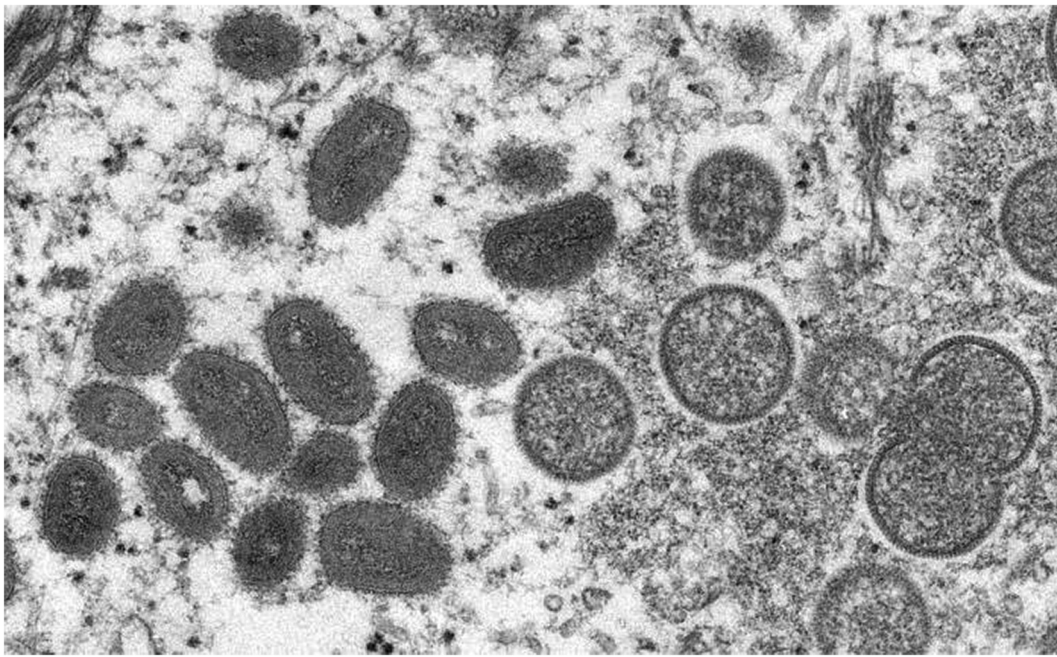


Fig. 1. Electron microscopy of Monkeypox virus. Available at https://phil.cdc.gov/PHIL/Images/22664/22664_lores.jpg.

from a bite or scratch, handling wild game, or contact with fluids or lesions from an infected animal can result in viral transmission [6,12,42,46,47]. Human-human transmission can occur through contact with an infected person's respiratory droplets, lesions, body fluids (including semen), or contaminated personal objects such as bedding or clothing [6,28,46,48]. The virus may also be aerosolized [3,6,20,46]. Contact with genital lesions and body fluids appears to play a significant role in the current outbreak with the largest number of cases occurring among the MSM community [6,43,46,49–51]. Secondary attack rates (i.e., the number of new cases among contacts divided by total number of contacts) range between 0.3 and 10.2%, but this may approach 50% among household contacts [39,52].

3.3. Clinical presentation

The time course of Monkeypox disease can be quite long with an incubation period that ranges from several days to three weeks and a period of active viral infection from 2 to 5 weeks. Refer to Fig. 2 for the natural history of the illness, including incubation and infection.

During the incubation phase, the virus replicates and spreads from the original inoculation site to the lymphatic system, followed by viremia, and eventual spread to other organ systems [6,46,53]. Symptoms can last 2 to 5 weeks [1,3]. Initial symptoms develop over the first five days of illness and are often nonspecific, including fever, myalgias, malaise, headache, sore throat, and cough (Table 1) [35,41,45,54–56].

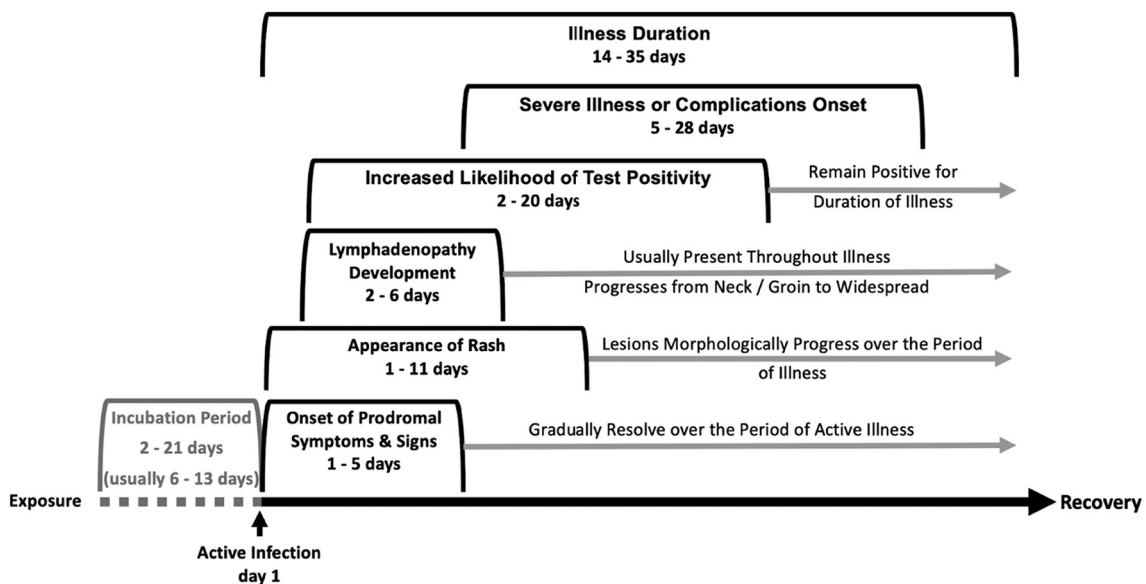


Fig. 2. Development and progression of various features of monkeypox infection, from exposure to recovery [63–65].

Table 1
The frequency of occurrence of the symptoms and signs seen in the monkeypox patient [9,63–65].

Symptom or Sign	Frequency (%)	Time of Development	Comment
Fever	62–85	1–5 days	prodromal presentation
Myalgias / body aches	31		
Malaise / weakness / lethargy	41		
Sore throat / pharyngitis	21		
Cough / dyspnea	20–60		
Nausea / vomiting	20–60		
Headache	27–65		
Rash – any distribution	95	2–11 days; pruritic / painful, macular lesions with progression to papules (day 3) & vesicles (days 4–5), then to pustules (days 6–7) with scabbing (days 7–14)	initially on face (95%) with spread to arms & legs then to hands & feet (75%); lesions in successive crops
Rash – mucous membrane	41–70	3–8 days	oral 70% / conjunctiva 20% rectal 14% / genitalia 30%
Lymphadenopathy	56–90	2–6 days; usually with fever onset & 1–2 days before rash	distinguishing feature; widespread or localized to neck & groin
Secondary infection of skin lesions	19	5–28 days	
Complications	<1–12	5–28 days	Encephalitis <1% / pneumonitis 12% / ophthalmologic 5%

Lymphadenopathy is common and most frequently occurs in the neck, groin, and submandibular region with the first six days of illness, which can help distinguish this monkeypox from smallpox [35,41,45,54–56]. It is important to understand the presentation of the illness over its various stages (Fig. 2).

The rash (Table 2 and Figs. 3, 4, 5) is the most characteristic feature of the disease and can present with all lesions at the same stage (similar to smallpox) or with lesions at various phases of development (similar to chickenpox) [1,57]. The rash typically begins on days 1–3 as pruritic or painful, indurated, umbilicated lesions most commonly on the face [5,40,41]. It can appear as late as the 11th day of illness [5,40,41]. Lesions most commonly spread in a centrifugal manner to involve the chest, arms, and legs, followed by the hands and feet [5,20,40,41]. Involvement

of the whole body is common within 24 h of the first lesion, and may involve the oral mucosa, genitalia, and conjunctivae as well [1,3,6,51]. Current data suggest the face is involved in 95%, the upper extremities in 81.3%, palms and soles in 75%, the lower extremities in 65.6%, the oral mucosa in 70%, the genitalia in 30%, and conjunctivae in 20% [1,5–7]. Lesions are generally 2–5 mm in diameter, though they may reach 1 cm [54,58,59]. They usually begin as macules and uniformly progress every 1–2 days to papules (day 3), then to vesicles containing clear liquid (days 4–5), and finally to pustules filled with yellow fluid (days 6–7), which then crust over and form scabs (days 7–14) [6,7]. The sequential nature of the rash helps distinguish monkeypox from its closest differential, chickenpox, in which all four stages of the rash appear concomitantly. While the monkeypox rash usually progresses as described, successive crops can appear over the first period of illness, allowing for the simultaneous appearance of various stages of lesions. The patient is considered contagious until all scabs have fallen off [1,58]. Refer to Table 1 for a summary of the frequency of occurrence of the symptoms and signs seen in monkeypox.

Severe illness may occur, including secondary skin infections in 19%, pneumonitis in 12%, ophthalmologic complications in up to 5%, and encephalitis in <1% [6,20,56,58,59]. Mortality rates can reach 10% and most commonly occur within the second week of infection [20,40,56]. There are several risk factors for greater disease severity and complications. These include patients with over 100 skin lesions and patients with mucosal lesions causing dysphagia, leading to decreased oral

Table 2
Features of the monkeypox rash [63–65].

Feature	Descriptor	Comment
lesion morphology with evolution	initially macular lesions with progression to papules (day 3 of rash), to vesicles (days 4–5), & to pustules (days 6–7) with eventual scabbing (days 7–14)	lesions can appear in successive crops over the first 1–2 weeks of illness
lesion distribution	initially on face (95%) with spread to arms & legs (80–85%) & subsequently to hands & feet (75%) upper extremities (80%) are more often involved than lower extremities (65%)	trunk also involved in cases with widespread distribution in cases involving focal inoculation, lesions appear at inoculum site initially
lesion number (rash burden)	mild disease – < 10 lesion moderate disease – 10 to 100 lesions severe disease – > 100 lesions mucosal lesions indicate severe disease	overall disease severity is related to lesion number with severe illness encountered in patients with extensive rash
mucous membrane involvement associated dermatologic symptoms	oral 70%, genitalia 30%, conjunctiva / cornea 20%, & rectal 14% skin: pain & pruritis mucous membranes: painful swallowing, difficulty with defecation, dysuria, foreign body sensation in eyes	specific mucous membrane (s) involvement follows general rash distribution skin & mucosal lesions can be very painful
complications	secondary bacterial infection of lesions dehydration desquamation of skin with fluid & electrolyte losses visual impairment	complications are more common in moderate to severe disease

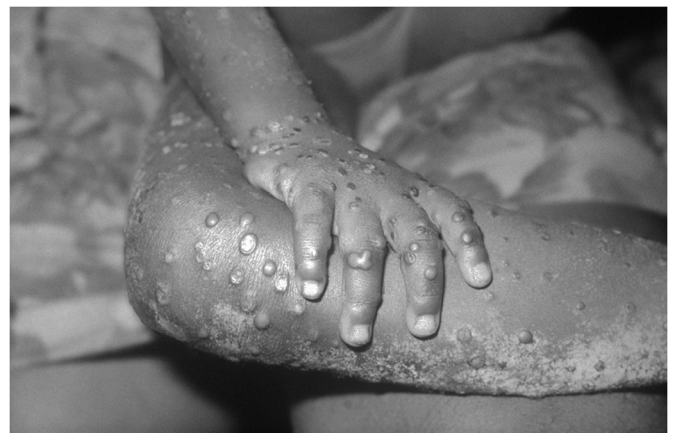

Fig. 3. 4-year-old female with monkeypox, 1971. Available at <https://upload.wikimedia.org/wikipedia/commons/e/ef/Monkeypox.jpg>.

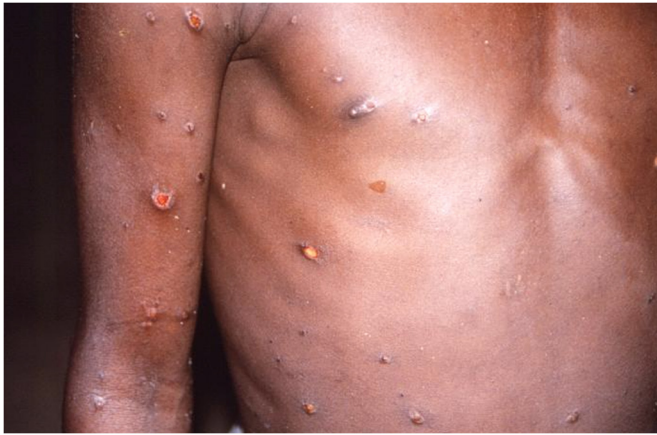

Fig. 4. Patient with monkeypox, 1997. Available at https://upload.wikimedia.org/wikipedia/commons/9/9a/12779_lores.jpg.

intake and volume depletion [56,58]. Alternatively, patients with <25 lesions tend to have a less severe course [5]. Children, young adults, and patients not immunized against smallpox are at greater risk for severe disease, as are patients with cancer, diabetes mellitus, heart failure, emphysema, and those with immunodeficiencies (e.g., HIV/AIDS, undergoing treatment with cytotoxic chemotherapy, anti-rejection medications, radiation, or chronic steroids) [6,20,43,60]. Patients with HIV can have longer duration of illness and greater likelihood of genital ulcers, larger sized lesions, and secondary skin infections [61,62]. HIV infection is also associated with a higher mortality risk [40].

3.3.1. Current outbreak with differing presentation characteristics

Much of the knowledge regarding the clinical presentation of monkeypox is based on prior sporadic cases as well as smaller outbreaks [1,3]. The current outbreak, as noted above, has been especially prominent in the MSM community, with a distinct presentation pattern. First, the patients are predominantly male in the 30 to 50 year age period. The classic prodromal symptoms are encountered somewhat less frequently in the current outbreak, ranging from 27 to 62% of those recently infected compared to past experience with approximately 70–80% presenting with weakness, myalgias, etc.; fever is seen commonly in both the recent outbreak (60%) and the historical comparison groups (80%) [63–65].

The rash typical of monkeypox also appears to have a different distribution and density in the current outbreak. Recent reports note that the

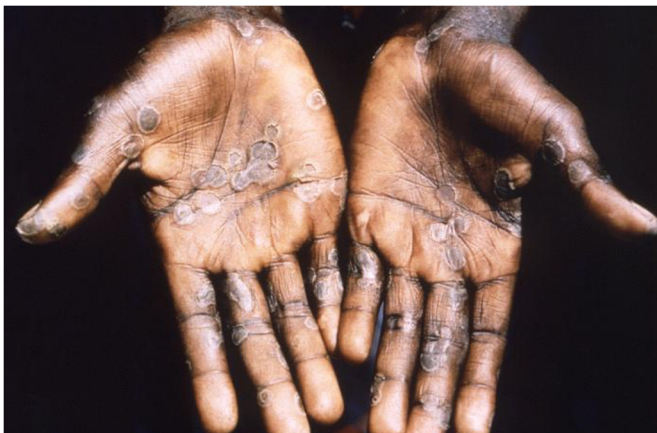

Fig. 5. Patient with monkeypox lesions along the palms. Available at https://upload.wikimedia.org/wikipedia/commons/2/20/Monkeypox_12761.jpg.

Table 3

Comparison of demographic and clinical presentation features between current (“atypical”) and past (“traditional”) monkeypox outbreaks [63–65].

Feature	Current Outbreak	Past Outbreaks
Gender	predominantly male	equal gender distribution
Age	30–50 years	variable range
Sexual orientation	predominantly gay male & bisexual male	primarily heterosexual (male & female)
Mode of virus transmission	skin-skin contact during sexual activity	large droplet aerosol & contact with skin lesions
Prodromal symptoms	25–60%	70–80%
Fever	60%	80–85%
Rash as initial manifestation (before prodromal symptoms & fever)	60%	10%
Lymphadenopathy	55–60%	90%
Rash-cutaneous	90–100%	95%
Rash-mucous membranes	100%	15–70%
Muco-cutaneous rash only without systemic features	15%	uncommon

current rash, involving both skin and mucous membranes, can be the initial manifestation of illness in more than half of infected patients. In other words, these patients do not present with current or recent prodromal symptoms and signs, such as fever and the reportedly characteristic lymphadenopathy. In a small subset of these patients, the mucocutaneous rash is the only manifestation of monkeypox infection. The number of monkeypox lesions on the skin or mucous membranes is also lower in the current outbreak; more than half of patients had 10 or fewer lesions, frequently noted in the perineal region (genital and ano-rectal areas) – importantly, a very large percentage of these these patients with fewer genital lesions presented with 1 single monkeypox sore. In the current outbreak, penile, ano-rectal, and oral-pharyngeal lesions are seen with significant frequency [63–65]. Refer to Table 3 for a comparison of past with current outbreak presenting characteristics.

3.4. Differential diagnosis

Several other conditions can be mistaken for monkeypox, including chickenpox (*Varicella-zoster*) and smallpox (*Variola major* or *minor*) (Table 4). These are unlikely to produce lymphadenopathy, and chickenpox lesions more commonly are superficial and rapidly progress, reaching the crust stage within 24 h [7,57,66,67]. Smallpox has not been documented since 1977, but bioterrorism remains a possibility [68]. Smallpox has lesions all at the same stage, but this is not present in all cases of monkeypox. Other conditions to consider include anthrax, cowpox, drug reactions, erythema multiforme, hand-foot-mouth disease, measles, molluscum contagiosum, Rocky Mountain Spotted Fever, scabies, syphilis, staphylococcal skin infections, Stevens-Johnson Syndrome / Toxic Epidermal Necrolysis, and tinea species.

3.5. Isolation precautions & personal protective equipemnt

Patients with suspected monkeypox should be isolated in a room with a closed door. Clinicians entering the patient's room should wear personal protective equipment (PPE) with standard, contact, and airborne precautions. This form of PPE will typically include a disposable gown, gloves, eye protection, and an N95 respirator or equivalent [66].

3.6. Establishing the diagnosis

Clinical history is essential in the initial evaluation of the patient with suspected monkeypox, including travel to an endemic area, contact with other infected patients, previous and current symptoms, onset of symptoms, sexual history, and whether they have previously received smallpox vaccination. Clinicians should perform a full skin examination, along with the oral mucosa and the eyes, viewing the location and the stage of the lesions. Examination of the cardiopulmonary,

Table 4
Comparison of the clinical characteristics of chickenpox, monkeypox, and smallpox.

Characteristic	Chickenpox	Monkeypox	Smallpox
Incubation period (days)	12–14	2–21	7–17
Length of prodromal phase (days)	0–2	1–5	2–4
Stages of lesion development	Lesions at different stages of development	Usually at the same stage of development but can also be at different stages	Lesions at the same stage of development
Rash distribution	Centripetal	Centrifugal	Centrifugal
Frequency of lesions on palms or soles	Rare	Common	Common
Lesion depth (mm)	Superficial, 2–3	Superficial to deep, up to 6	Deep, 4–6
Length of time until crusting of pustules (days)	Within 24 h	5–7	5–8
Length of time from rash onset to desquamation (days)	6–14	14–21	1
Lymphadenopathy	Usually absent	Significant	Usually absent

abdominal, and neurologic systems is also recommended for evaluating any complications of monkeypox or other conditions.

3.6.1. Laboratory testing

Laboratory testing including complete blood cell count (CBC), electrolytes, and renal and liver function should be obtained. In the 2003 outbreak, abnormal findings included elevated blood urea nitrogen in 61%, hypoalbuminemia and elevated liver function tests in 50%, leukocytosis in 45% and thrombocytopenia in 35% [5]. However, these findings are not necessarily associated with greater disease severity [5].

To diagnose monkeypox, samples should be obtained from the lesion (roofs or contents) or exudates, but preferably an open lesion, if testing capability is available [3,69,70]. The clinician should obtain two swabs from at least three lesions [70]. A nylon, polyester, or Dacron swab should be used for sampling. The swab should then be placed in a dry, sterile container and remain refrigerated or frozen until testing can be performed [1,70]. The currently preferred test is nucleic acid amplification testing with real time polymerase chain reaction (RT-PCR). Sensitivity and specificities reach 100% for RT-PCR, but this is not available in all institutions [3,69–74]. Immunologic serum testing for antigens or antibodies is available. However, there is cross-reactivity with other orthopoxviruses, and immunologic testing is not sufficiently sensitive or specific for diagnosis of monkeypox [71,72]. The CDC has provided a case definition based on clinical characteristics and testing (Table 5) [75].

3.7. Management

Current treatment of monkeypox is primarily supportive with pain control, hydration, and managing any complications. Intravenous fluid resuscitation may be required in patients with hypovolemia. Antibiotics may be necessary in patients with a secondary bacterial skin infection, pneumonia, or conjunctivitis but should not be given prophylactically to prevent infection. High-risk patient populations should be considered in treatment decisions (Table 6).

There are no medications specifically approved for monkeypox as of July 28, 2022, but the United States Food and Drug Administration (FDA) has approved several medications for the management of smallpox [6,76]. These medications may be helpful for monkeypox, as it is also an orthopoxvirus, and the CDC recommends their use in several populations listed in Table 3. Medications that may be used from the Strategic National Stockpile include brincidofovir, cidofovir, tecovirimat and vaccinia immune globulin intravenous (VGIV) (Table 7) [76–79]. There are no clinical studies evaluating these medications in humans with monkeypox, but animal studies do demonstrate efficacy.

3.8. Disposition

Disposition is based on the ability to tolerate oral intake, adequate pain control, and associated complications. Patients unable to tolerate oral intake, those with uncontrolled pain, and those with major organ

complications may require inpatient admission. If the patient does not require admission, they should strictly quarantine from others around them, as well as other mammals (e.g., pet dogs or cats). Patients require isolation until all scabs have fallen off and there is a new layer of skin [6,60,80]. Local and state health authorities should also be involved in the decision to discontinue quarantine. If the patient must break quarantine, they should wear long sleeves and pants and a surgical mask in order to reduce contact with any lesions and protect others from respiratory droplets [6,80]. If they live with others, they should isolate themselves in a separate room. If this is not possible, the patient should cover the lesions and maintain as much distance from others as possible. A surgical mask at minimum should be worn [6,80]. The dirty laundry, including bedding, from infected patients should be washed in warm to hot water in a laundry machine. Soiled dishes and utensils can be cleaned in a dishwasher or by hand with warm/hot water and soap. Any contaminated surfaces in the living area should be disinfected with cleaning products [6,80]. Dried matter from lesions may be resuspended in the air with certain activities such as sweeping or vacuuming, so this should be avoided [80].

3.9. Vaccination

At the present time, there are no data available regarding the effectiveness of the two existing vaccines in the current Monkeypox viral outbreak [90]. Two different vaccines exist and can be considered for prevention of Monkeypox infection: the JYNNEOS vaccine and the ACAM2000 vaccine.

The JYNNEOS vaccine (also known as Imvamune or Imvanex) is FDA licensed and approved for the prevention of Monkeypox infection. JYNNEOS contains a live *Vaccinia virus* that does not replicate efficiently in human cells. This vaccine is administered as two subcutaneous injections 28 days apart with immunity reaching its peak 14 days after the second injection. JYNNEOS is FDA approved for use in the prevention of smallpox or monkeypox in people ages 18 years and older. Use in younger populations currently requires a single patient emergency use authorization from FDA for each person under 18 years. The CDC is developing an Expanded Access Investigational New Drug protocol to allow broader use of JYNNEOS in the pediatric population. In contrast to the ACAM2000 vaccine, JYNNEOS is safe to administer to people with HIV and exfoliative skin conditions. While there are no human data, animal studies do not demonstrate evidence of reproductive harm; at the present time, both pregnancy and breastfeeding are not considered contraindications to receiving the JYNNEOS vaccine. Currently, the JYNNEOS vaccine is in short supply in the United States, though production is increasing with an anticipated augmented stock within the next one to three months [90].

ACAM2000, is licensed and approved by the FDA only for the prevention of smallpox virus infection; however, its use has been approved for the prevention of Monkeypox infection via an Expanded Access Investigational New Drug application. The ACAM2000 vaccine contains a live *Vaccinia virus* that is replication-competent, meaning that the

Table 5
CDC Case Definition (CDC Case definition) [1].

<p>Suspect Case:</p> <ul style="list-style-type: none"> - New characteristic rash* OR - Meets one of the epidemiologic criteria and has a high clinical suspicion** for monkeypox** <p>Probable Case:</p> <ul style="list-style-type: none"> - No suspicion of other recent <i>Orthopoxvirus</i> exposure (e.g., <i>Vaccinia virus</i> in ACAM2000 vaccination) AND demonstration of the presence of <ul style="list-style-type: none"> o <i>Orthopoxvirus</i> DNA by polymerase chain reaction of a clinical specimen OR o <i>Orthopoxvirus</i> using immunohistochemical or electron microscopy testing methods OR o Demonstration of detectable levels of anti-orthopoxvirus IgM antibody during the period of 4 to 56 days after rash onset <p>Confirmed Case:</p> <ul style="list-style-type: none"> - Demonstration of the presence of <i>Monkeypox virus</i> DNA by polymerase chain reaction testing or Next-Generation sequencing of a clinical specimen OR isolation of <i>Monkeypox virus</i> in culture from a clinical specimen <p>Epidemiologic Criteria:</p> <p>Within 21 days of illness onset:</p> <ul style="list-style-type: none"> - Reports having contact with a person or people with a similar appearing rash or who received a diagnosis of confirmed or probable monkeypox OR - Had close or intimate in-person contact with individuals in a social network experiencing monkeypox activity, this includes men who have sex with men (MSM) who meet partners through an online website, digital application ("app"), or social event (e.g., a bar or party) OR - Traveled outside the US to a country with confirmed cases of monkeypox or where <i>Monkeypox virus</i> is endemic OR - Had contact with a dead or live wild animal or exotic pet that is an African endemic species or used a product derived from such animals (e.g., game meat, creams, lotions, powders, etc.) <p>Exclusion Criteria:</p> <p>A case may be excluded as a suspect, probable, or confirmed case if:</p> <ul style="list-style-type: none"> - An alternative diagnosis* can fully explain the illness OR - An individual with symptoms consistent with monkeypox does not develop a rash within 5 days of illness onset OR - A case where high-quality specimens do not demonstrate the presence of <i>Orthopoxvirus</i> or <i>Monkeypox virus</i> or antibodies to orthopoxvirus
--

* Deep-seated and well-circumscribed lesions, often with central umbilication; also lesion progression through specific sequential stages—macules, papules, vesicles, pustules, and scabs. This can sometimes be confused with other diseases that are more commonly encountered in clinical practice (e.g., herpes, secondary syphilis, and varicella zoster). Historically, sporadic accounts of patients co-infected with *Monkeypox virus* and other infectious agents (e.g., varicella zoster, syphilis) have been reported, thus patients with a characteristic rash should be considered for testing, even if other tests are positive.

** Clinical suspicion may exist if presentation is consistent with illnesses that may be confused with monkeypox (e.g., herpes, secondary syphilis, and varicella zoster).

virus particles are capable of infecting cells and replicating to produce additional infectious particles. Due to it being replication competent, this vaccine should not be given to patients with moderate to severe immunosuppression, chronic skin conditions such as eczema or other exfoliative disorders, or pregnancy. Importantly, the ACAM2000 vaccine has been associated with both myocarditis and pericarditis. The effectiveness of ACAM2000 in the prevention of the smallpox viral infection is supported by human clinical trials and animal studies; at the present time, there are no data regarding its effectiveness in the prevention of Monkeypox viral infection in the current outbreak. The ACAM2000 vaccine is administered as one subcutaneous dose via multiple puncture technique with a special, or bifurcated, needle. Maximal immune boosting does not occur for 28 days after ACAM2000 administration. This vaccine is more readily available in the United States [90].

During widespread viral illness outbreaks, vaccines are used in four strategic approaches, including general vaccination of the population (general prophylaxis), pre-exposure prophylaxis (PrEP, targeted at individuals at high risk for acquiring monkeypox infection, such as

Table 6
CDC recommended on identification of high-risk populations – those individuals at increased risk for adverse outcome due to monkeypox viral infection.

<p>High-risk Populations – Those Individuals at Increased Risk for Adverse Outcome due to Monkeypox Viral Infection</p> <ul style="list-style-type: none"> • Patients with Monkeypox viral infection complications <ul style="list-style-type: none"> ·secondary bacterial skin infection ·dehydration ·pneumonia ·concurrent disease ·significant comorbidities • Patients with severe disease <ul style="list-style-type: none"> ·sepsis ·pneumonitis ·encephalitis ·hemorrhagic disease ·extensive rash with confluent lesions • Immunocompromised patients <ul style="list-style-type: none"> ·HIV/AIDS ·Leukemia / lymphoma ·generalized malignancy ·solid organ transplantation ·recipient with hematopoietic stem cell transplant <24 months post-transplant or ≥ 24 months but with GVHD or disease relapse ·therapy with alkylating agents, antimetabolites, radiation, TNF inhibitors, or high-dose steroids ·autoimmune disease with immunodeficiency • Pediatric patients (particularly <8 years of age) • Patients with history or presence of atopic dermatitis or other active exfoliative skin conditions <ul style="list-style-type: none"> ·eczema or psoriasis (extensive) ·burns ·impetigo ·varicella/extensive HSV infection ·severe acne ·severe diaper dermatitis with extensive areas of denuded skin • Pregnant or breastfeeding women • Patients with infections in the following anatomic regions: conjunctival/corneal, oral cavity, oropharyngeal, genital, ano-rectal areas
--

Abbreviations: HIV - human immunodeficiency virus; AIDS - acquired immune deficiency syndrome infection; TNF - tumor necrosis factor; GVHD - graft-versus-host disease; VZV - varicella zoster virus; HSV - herpes simplex virus.

healthcare or laboratory workers), post-exposure prophylaxis (PEP, used in individuals who have been directly exposed to a patient with suspected or confirmed Monkeypox infection), and outbreak-response post-exposure prophylaxis (PEP++ , an expanded form of PEP aimed at larger groups of individuals who may have been exposed to Monkeypox viral infection).

While emergency medicine clinicians can be involved in all four vaccine strategies, during periods of heightened Monkeypox contagion, the emergency medicine clinician is most likely to deliver PEP to patients only in the post-exposure prophylaxis strategy (i.e., considering the use of the vaccine in patients who have been exposed to a suspected or confirmed case). The PEP strategy is most effective in preventing infection if the vaccine is administered within four days of exposure. If given between 4 and 14 days post-exposure, the likelihood of preventing infection is much lower but can still reduce the severity of the illness should it develop. It is also recommended to consider administering the vaccine from a PEP strategic perspective beyond 14 days exposure to those individuals at higher risk of adverse outcome, such as those patients with significant immunosuppression [90].

4. Conclusion

Monkeypox was declared a global health emergency in July 2022; in early August 2022, the federal government of the United States made a similar declaration, noting that Monkeypox is a national health emergency. This review seeks to provide emergency medicine clinicians with a focused overview of this virus, based upon extrapolated

Table 7
Potential Treatment Options for Monkeypox [81-89].

Name	Dose	Treatment Length	Adverse Effects	Contraindications
Brincidofovir (CMX001 or Tembexa)	<ul style="list-style-type: none"> <10 kg: 6 mg/kg oral suspension once weekly 10 to 47 kg: 4 mg/kg oral suspension once weekly ≥48 kg: 200 mg tablet once weekly 	Two weeks	<ul style="list-style-type: none"> Nausea, vomiting, diarrhea Abdominal pain Transaminitis Male fertility impairment Fetal toxicity 	None
Cidofovir (Vistide)	<ul style="list-style-type: none"> 3 to 5 mg/kg IV Administer 1 L normal saline before and after the infusion Administer probenecid 2 g 3 h prior to infusion, followed by 1 g at 2 h and 1 g at 8 h post-infusion 	Single dose	<ul style="list-style-type: none"> Fever Nausea & vomiting Nephrotoxicity Neutropenia Decreased intraocular pressure Anterior uveitis or iritis Fanconi syndrome Headache Nausea & vomiting Abdominal pain Anemia ECG changes 	Absolute: <ul style="list-style-type: none"> Serum creatinine >1.5 mg/dL ≥ 2+ proteinuria Relative: <ul style="list-style-type: none"> Renal impairment with creatinine ≤1.5 mg/dL
Tecovirimat (TPOXX, ST-246)	Capsule: <ul style="list-style-type: none"> 13 to 24 kg: 200 mg BID 25 to 39 kg: 400 mg BID 40 to 119 kg: 600 mg BID ≥120 kg: 600 mg TID Must be taken with full, fatty meal Injection: <ul style="list-style-type: none"> 3 to 34 kg: 6 mg/kg BID 35 to 119 kg: 200 mg BID ≥120 kg: 300 mg BID Injections are administered over 6 h Injections are limited to oral intolerance (transition to oral dosing once able to tolerate) 	14 days	<ul style="list-style-type: none"> Headache Nausea & vomiting Abdominal pain Anemia ECG changes 	Capsule: None Parenteral: creatinine clearance <30 mL/min
Vaccinia Immunoglobulin (VIGIV)	<ul style="list-style-type: none"> 6000 units/kg IV 9000 to 24,000 units/kg IV may be considered if the patient does not respond to the initial dose 	Single dose; may repeat based on patient condition (specific data are lacking)		<ul style="list-style-type: none"> Isolated vaccinia keratitis History of anaphylaxis or prior severe systemic reaction associated with parenteral administration of VIGIV or other human immune globulin preparations IgA-deficient patients with antibodies against IgA & history of IgA hypersensitivity

IV, intravenous; ECG, electrocardiogram.

knowledge from past outbreaks as well as from related infectious illnesses, such as smallpox. The virus is transmitted by contact with an infected animal or human or contaminated material. Patients present with a prodromal flu-like illness and lymphadenopathy. A rash spreading in a centrifugal manner involving the oral mucosa, face, palms, and soles is typical, with lesions progressing along various stages. Confirmation includes PCR testing, if locally available. Most patients improve with symptomatic therapy, and as of August 2022, there are no approved treatments specifically for monkeypox. There are several high-risk patient populations for whom antiviral treatment should be considered, if it is locally available.

Conflict of interest

None.

CRediT authorship contribution statement

Brit Long: Writing – review & editing, Writing – original draft, Validation, Supervision, Resources, Project administration, Methodology, Formal analysis, Data curation, Conceptualization. **Alex Koyfman:** Writing – review & editing, Writing – original draft, Resources, Methodology, Investigation, Conceptualization. **Michael Gottlieb:** Writing – review & editing, Writing – original draft, Validation, Methodology, Formal

analysis, Conceptualization. **Stephen Y. Liang:** Writing – review & editing, Writing – original draft, Methodology, Formal analysis, Conceptualization. **Brandon M. Carius:** Writing – review & editing, Writing – original draft, Methodology, Formal analysis, Conceptualization. **Summer Chavez:** Writing – review & editing, Writing – original draft, Methodology, Formal analysis, Conceptualization. **William J. Brady:** Writing – review & editing, Writing – original draft, Supervision, Resources, Project administration, Methodology, Formal analysis, Data curation, Conceptualization.

References

- [1] About Monkeypox. Centers for Disease Control and Prevention. Updated June 17. Accessed July 8, 2022. <https://www.cdc.gov/poxvirus/monkeypox/about.html>; 2021.
- [2] Monkeypox – United Kingdom of Great Britain and Northern Ireland. (nd) World Health Organization Retrieved May 22, 2022, from <https://www.who.int/emergencies/disease-outbreak-news/item/2022-DON383>. 2022
- [3] Monkeypox. World Health Organization. <https://www.who.int/news-room/fact-sheets/detail/monkeypox>; 19 May 2022. Accessed July 21, 2022.
- [4] Monkeypox. Centers for Disease Control and Prevention. <https://www.cdc.gov/poxvirus/monkeypox/index.html>. Accessed July 24, 2022.
- [5] Huhn G, Bauer A, Yorita K, et al. Clinical characteristics of human Monkeypox, and risk factors for severe disease. *Clin Infect Dis*. 2005;41(12):1742–51.
- [6] ACEP Monkeypox Field Guide. American College of Emergency Physicians. <https://www.acep.org/monkeypox-field-guide/cover-page/>; 2022. Accessed July 8, 2022.
- [7] Clinical Recognition. Centers for Disease Control and Prevention. Updated June 24, 2022. <https://www.cdc.gov/poxvirus/monkeypox/clinicians/clinical-recognition.html>. Accessed July 8, 2022.

- [8] Alakunle E, Moens U, Nchinda G, Okeke MI. Monkeypox virus in Nigeria: infection biology, epidemiology, and evolution. *Viruses*. 2020;12(11):1257.
- [9] MacNeil A, Reynolds MG, Carroll DS, Karem K, Braden Z, Lash R, et al. Monkeypox or varicella? Lessons from a rash outbreak investigation in the Republic of the Congo. *Am J Trop Med Hyg*. 2009 Apr;80(4):503–7.
- [10] de Nicolas-Ruanes B, Vivancos MJ, Azcarraga-Llobet C, Moreno AM, Rodríguez-Dominguez M, Berna-Rico ED, et al. Monkeypox virus case with maculopapular exanthem and proctitis during the Spanish outbreak in 2022. *J Eur Acad Dermatol Venereol*. 2022 Aug;36(8):e658–60.
- [11] Martín-Delgado MC, Martín Sánchez FJ, Martínez-Sellés M, Molero García JM, Moreno Guillén S, Rodríguez-Artalejo FJ, et al. Monkeypox in humans: a new outbreak. *Rev Esp Quimioter*. 2022 Jul 6. <https://doi.org/10.37201/req/059.2022.martin06jul2022>.
- [12] Kile JC, Fleischauer AT, Beard B, Kuehnert MJ, Kanwal RS, Pontones P, et al. Transmission of monkeypox among persons exposed to infected prairie dogs in Indiana in 2003. *Arch Pediatr Adolesc Med*. 2005 Nov;159(11):1022–5.
- [13] Saxena SK, Ansari S, Maurya VK, Kumar S, Jain A, Paweska JT, et al. Re-emerging human monkeypox: a major public-health debacle. *J Med Virol*. 2022 Jun 1. <https://doi.org/10.1002/jmv.27902>. Epub ahead of print.
- [14] 2022 Monkeypox and Orthopoxvirus Outbreak Global Map. Centers for Disease Control and Prevention. Updated June 21, 2022. <https://www.cdc.gov/poxvirus/monkeypox/response/2022/world-map.html>. Accessed July 26, 2022.
- [15] Ladnyk I, Ziegler P, Kima E. A human infection caused by monkeypox virus in Basankusu Territory, Democratic Republic of the Congo. *Bull World Health Organ*. 1972;46(5):593–7.
- [16] Von Magnus P, Anderson EK, Peterson KB. A pox-like disease in cynomolgus monkeys. *Acta Pathol Microbiol Scand*. 1959;46:156–76.
- [17] Marennikova SS, Seluhina EM, Malceva NN, et al. Isolation and properties of the causal agent of a new variola-like disease (monkeypox) in man. *Bull World Health Organ*. 1972;46:599–611.
- [18] Foster SO, Brink EW, Hutchins DL, Pifer JM, Lourie B, Moser CR, et al. Human monkeypox. *Bull World Health Organ*. 1972;46(5):569–76.
- [19] Multi-country monkeypox outbreak in non-endemic countries. World Health Organization; 2022. <https://www.who.int/emergencies/disease-outbreak-news/item/2022-DON385> Published May 21, 2022. Accessed May 23.
- [20] Peterson E, Kantele A, Koopmans M, et al. Human Monkeypox: epidemiological and clinical characteristics, diagnosis, and prevention. *Infect Dis Clin North Am*. 2019;33(4):1027–43.
- [21] Silva NIO, de Oliveira JS, Kroon EG, Trindade GS, Drumond BP. Here, there, and everywhere: the wide host range and geographic distribution of zoonotic orthopoxviruses. *Viruses*. 2020 Dec 30;13(1):43.
- [22] Durski KN, McCollum AM, Nakazawa Y, Petersen BW, Reynolds MG, Briand S, et al. Emergence of Monkeypox – west and Central Africa, 1970–2017. *MMWR Morb Mortal Wkly Rep*. 2018 Mar 16;67(10):306–10.
- [23] Reed K, Melski J, Graham M, et al. The detection of monkeypox in humans in the Western hemisphere. *N Engl J Med*. 2004;350(4):342–50.
- [24] Monkeypox. State of New Jersey Department of Agriculture. Published 2003. <https://www.nj.gov/agriculture/divisions/ah/diseases/monkeypox.html>. Accessed May 23, 2022.
- [25] Erez M, Achdout H, Milrot E, et al. Diagnosis of imported Monkeypox, Israel, 2018. *Emerg Infect Dis*. 2019;25(5):980–3.
- [26] Vaughan A, Aarons E, Astbury J, et al. Human-to-human transmission of Monkeypox virus, United Kingdom, October 2018. *Emerg Infect Dis*. 2020;26(4):782–5.
- [27] Yong S, Ng O, Ho Z, et al. Imported Monkeypox, Singapore. *Emerg Infect Dis*. 2020;26(8):1826–30. <https://doi.org/10.3201/eid2608.191387>.
- [28] Hobson G, Adamson J, Adler H, Firth R, Gould S, Houlihan C, et al. Family cluster of three cases of monkeypox imported from Nigeria to the United Kingdom, May 2021. *Euro Surveill*. 2021 Aug;26(32):2100745.
- [29] Rao AK, Schulte J, Chen TH, Hughes CM, Davidson W, Neff JM, et al. Monkeypox in a traveler returning from Nigeria – Dallas, Texas, July 2021. *MMWR Morb Mortal Wkly Rep*. 2022 Apr 8;71(14):509–16.
- [30] Costello V, Sowash M, Gaur A, Cardis M, Pasioka H, Wortmann G, et al. Imported Monkeypox from international traveler, Maryland, USA, 2021. *Emerg Infect Dis*. 2022 May;28(5):1002–5.
- [31] Kozlov M. Monkeypox goes global: why scientists are on alert, May 20. *Nature*. 2022. <https://doi.org/10.1038/d41586-022-01421-8>. Epub ahead of print.
- [32] Centers for Disease Control and Prevention Cdc. Secondary and tertiary transmission of vaccinia virus after sexual contact with a smallpox vaccinee—san Diego, California, 2013 Mar 1. *MMWR Morb Mortal Wkly Rep*. 2012;62(8):145–7.
- [33] Rodríguez BS, BRG Herrador, Franco AD, MPS Fariñas, Del Amo Valero J, AHA Llorente, et al. Epidemiologic features and control measures during Monkeypox outbreak, Spain, June 2022. *Emerg Infect Dis*. 2022 Jul 12;28(9).
- [34] Alpalhão M, Frade JV, Sousa D, Patrocínio J, Garrido PM, Correia C, et al. Monkeypox: a new (sexually transmissible) epidemic? *J Eur Acad Dermatol Venereol*. 2022 Jul 16. <https://doi.org/10.1111/jdv.18424>. Epub ahead of print. PMID: 35841292.
- [35] Bosworth A, Wakerley D, Houlihan CF, Atabani SF. Monkeypox: an old foe, with new challenges. *Infect Prev Pract*. 2022 Jun 30;4(3):100229.
- [36] Simpson K, Heymann D, Brown C, et al. Human monkeypox – after 40 years, an unintended consequence of smallpox eradication. *Vaccine*. 2020;38(33):5077–81. <https://doi.org/10.1016/j.vaccine.2020.04.062>.
- [37] Smallpox questions and answers: the disease and the vaccine. New York State Department of Health; 2022. Updated April 2003. <https://www.health.ny.gov/publications/7004/> Accessed June 16.
- [38] Rimoin AW, Mulembakani PM, Johnston SC, Lloyd Smith JO, Kisalu NK, Kinkela TL, et al. Major increase in human monkeypox incidence 30 years after smallpox vaccination campaigns cease in the Democratic Republic of Congo. *Proc Natl Acad Sci U S A*. 2010 Sep 14;107(37):16262–7.
- [39] Bunge E, Hoet B, Chen L, et al. The changing epidemiology of human monkeypox—a potential threat? A systematic review. *PLoS Negl Trop Dis*. 2022;16(2):e0010141.
- [40] Yinka-Ogunleye A, Aruna O, Dalhat M, Ogoina D, McCollum A, Disu Y, et al. CDC Monkeypox outbreak team. Outbreak of human monkeypox in Nigeria in 2017–18: a clinical and epidemiological report. *Lancet Infect Dis*. 2019 Aug;19(8):872–9.
- [41] Osadebe L, Hughes CM, Shongo Lushima R, Kabamba J, Nguete B, Malekani J, et al. Enhancing case definitions for surveillance of human monkeypox in the Democratic Republic of Congo. *PLoS Negl Trop Dis*. 2017 Sep 11;11(9):e0005857.
- [42] Doshi RH, Guagliardo SAJ, Doty JB, Babeaux AD, Matheny A, Burgado J, et al. Epidemiologic and ecologic investigations of Monkeypox, Likouala department, Republic of the Congo, 2017. *Emerg Infect Dis*. 2019 Feb;25(2):281–9.
- [43] Epidemiological update: Monkeypox outbreak. European Centre for Disease Prevention and Control; 2022. Published May 20, 2022. <https://www.ecdc.europa.eu/en/news-events/epidemiological-update-monkeypox-outbreak> Accessed May 23.
- [44] Likos A, Sammons S, Olson V, et al. A tale of two clades: monkeypox viruses. *J Gen Virol*. 2005;86(Pt 10):2661–72.
- [45] Reynolds Mary G, Doty Jeffrey B, McCollum Andrea M, Olson Victoria A, Nakazawa Yoshinori. Monkeypox re-emergence in Africa: a call to expand the concept and practice of one health; 2019. <https://doi.org/10.1080/14787210.2019.1567330>.
- [46] How it spreads. Centers for Disease Control and Prevention; 2022. Updated June 24, 2022. <https://www.cdc.gov/poxvirus/monkeypox/transmission.html> Accessed July 8.
- [47] Nolen LD, Osadebe L, Katomba J, Likofata J, Mukadi D, Monroe B, et al. Introduction of Monkeypox into a community and household: risk factors and zoonotic reservoirs in the Democratic Republic of the Congo. *Am J Trop Med Hyg*. 2015 Aug;93(2):410–5.
- [48] Besombes C, Gonofio E, Konamna X, Selekon B, Grant R, Gessain A, et al. Intrafamily transmission of Monkeypox virus, Central African Republic, 2018. *Emerg Infect Dis*. 2019 Aug;25(8):1602–4.
- [49] Antinori A, Mazzotta V, Vita S, Carletti F, Tacconi D, Lapini LE, et al. Epidemiological, clinical and virological characteristics of four cases of monkeypox support transmission through sexual contact, Italy, May 2022. *Euro Surveill*. 2022 Jun;27(22)2200421.
- [50] Peiró-Mestres A, Fuentes I, Camprubi-Ferrer D, Marcos MÁ, Vilella A, Navarro M, et al. Frequent detection of monkeypox virus DNA in saliva, semen, and other clinical samples from 12 patients, Barcelona, Spain, May to June 2022. *Euro Surveill*. 2022 Jul;27(28)2200503.
- [51] Noe S, Zange S, Seilmaier M, Antwerpen MH, Fenzl T, Schneider J, et al. Clinical and virological features of first human monkeypox cases in Germany. *Infection*. 2022 Jul 11:1–6.
- [52] Beer EM, Rao VB. A systematic review of the epidemiology of human monkeypox outbreaks and implications for outbreak strategy. *PLoS Negl Trop Dis*. 2019 Oct 16;13(10):e0007791.
- [53] Hutson CL, Carroll DS, Gallardo-Romero N, et al. Comparison of Monkeypox virus clade kinetics and pathology within the prairie dog animal model using a serial sacrifice study design. *Biomed Res Int*. 2015;2015:1–19.
- [54] Breman JG, Kalisa-Ruti MV Steniowski, Zanutto E, Gromyko AI, Arita I. Human monkeypox, 1970–79. *Bull World Health Organ*. 1980;58(2):165–82.
- [55] Hraib M, Jouni S, Albitar MM, Alaidi S, Alshehaby Z. The outbreak of monkeypox 2022: an overview. *Ann Med Surg (Lond)*. 2022 Jun 24;79:104069.
- [56] Weinstein W, Nalca A, Rimoin A, et al. Reemergence of Monkeypox: prevalence, diagnostics, and countermeasures. *Clin Infect Dis*. 2005;41(12):1765–71.
- [57] Jezek Z, Szczeniowski M, Paluku, et al. Human monkeypox: clinical features of 282 patients. *J Infect Dis*. 1987;156(2):293–8.
- [58] Nalca A, Rimoin AW, Bavari S, Whitehouse CA. Reemergence of monkeypox: prevalence, diagnostics, and countermeasures. *Clin Infect Dis*. 2005 Dec 15;41(12):1765–71.
- [59] Di Giulio DB, Eckburg PB. Human monkeypox: an emerging zoonosis. *Lancet Infect Dis*. 2004 Jan;4(1):15–25. [https://doi.org/10.1016/s1473-3099\(03\)00856-9](https://doi.org/10.1016/s1473-3099(03)00856-9). Erratum in: *Lancet Infect Dis*. 2004 Apr;4(4):251.
- [60] Duration of isolation procedures. Centers for Disease Control and Prevention; 2022. Updated May 31, 2022. <https://www.cdc.gov/poxvirus/monkeypox/clinicians/isolation-procedures.html> Accessed July 8.
- [61] Ogoina D, Iroezindu James H, et al. Clinical course and outcome of human Monkeypox in Nigeria. *Clin Infect Dis*. 2020;71(8):e210–4.
- [62] Ogoina D, Izibewule J, Ogunleye A, et al. The 2017 human monkeypox outbreak in Nigeria—report of outbreak experience and response in the Niger Delta University teaching hospital, Bayelsa state, Nigeria. *PLoS One*. 2019;14(4):e0214229.
- [63] Patel A, Bilinska J, Tam JCH, et al. Clinical features and novel presentations of human monkeypox in a central London centre during the 2022 outbreak: descriptive case series. *BMJ*. 2022;378:e072410. Published 2022 Jul 28.
- [64] Thornhill JP, Barkati S, Walmsley S, et al. Monkeypox virus infection in humans across 16 countries – April–June 2022 [published online ahead of print, 2022 Jul 21]. *N Engl J Med*. 2022. <https://doi.org/10.1056/NEJMoa2207323>.
- [65] Orviz E, Negrodo A, Ayerdi O, et al. Monkeypox outbreak in Madrid (Spain): clinical and virological aspects [published online ahead of print, 2022 Jul 10]. *J Infect*. 2022. <https://doi.org/10.1016/j.jinf.2022.07.005>. S0163-4453(22)00415-7.
- [66] Infection prevention and control of Monkeypox in healthcare settings. Centers for Disease Control and Prevention; 2022. Updated July 5, 2022. Accessed July 10, 2022. <https://www.cdc.gov/poxvirus/monkeypox/clinicians/infection-control-healthcare.html>.
- [67] Jezek Z, Szczeniowski M, Palku K, et al. Human monkeypox: confusion with chickenpox. *Acta Trop*. 1988;45(4):297–307.
- [68] Smallpox. World Health Organization; 2022. Published 2022. <https://www.who.int/health-topics/smallpox> Accessed May 23, 2022.

- [69] Li D, Wilkins K, McCollum A, et al. Evaluation of the GeneXpert for human Monkeypox diagnosis. *Am J Trop Med Hyg*. 2017;96(2):405–10.
- [70] Preparation and collection of specimens. Centers for Disease Control and Prevention; 2022. Updated June 29, 2022. <https://www.cdc.gov/poxvirus/monkeypox/clinicians/prep-collection-specimens.html> Accessed July 8, 2022.
- [71] Karem K, Reynolds M, Braden Z, et al. Characterization of acute-phase humoral immunity to monkeypox: use of immunoglobulin M enzyme-linked immunosorbent assay for detection of monkeypox infection during the 2003 North American outbreak. *Clin Diagn Lab Immunol*. 2005;12:867–72.
- [72] Esposito J, Objieski J, Nakano J. Serological relatedness of monkeypox, variola, and vaccinia viruses. *J Med Virol*. 1977;1(1):35–47. <https://doi.org/10.1002/jmv.1890010107>.
- [73] Laboratory procedures and biosafety guidelines. Centers for Disease Control and Prevention; 2022. Updated June 29, 2022. Accessed July 8, 2022. <https://www.cdc.gov/poxvirus/monkeypox/lab-personnel/lab-procedures.html>.
- [74] Monkeypox lab process. Centers for Disease Control and Prevention; 2022. Updated June 29. Accessed July 8, 2022.
- [75] Case definitions for use in the 2022 Monkeypox response. Updated June 8, 2022. <https://www.cdc.gov/poxvirus/monkeypox/clinicians/case-definition.html>.
- [76] Treatment information for healthcare professionals. Centers for Disease Control and Prevention; 2022. Updated June 22, 2022. Accessed July 8, 2022. <https://www.cdc.gov/poxvirus/monkeypox/clinicians/treatment.html>.
- [77] Catalent Pharma Solutions. TPOXX (tecovirimat) [package insert]. U.S. Food and Drug Administration Website; 2022. Updated May 23, 2022. www.accessdata.fda.gov/drugsatfda_docs/label/2022/214518s000lbl.pdf.
- [78] Chimerix, Inc. Tembexa (brincidofovir) [package insert]. U.S. Food and Drug Administration Website; 2022. Updated June 2021. https://www.accessdata.fda.gov/drugsatfda_docs/label/2022/214518s000lbl.pdf Accessed May 23, 2022.
- [79] Gilead Sciences, Inc. Vistide (cidofovir injection) [package insert]. U.S. Food and Drug Administration Website; 2022. Updated September 2000. https://www.accessdata.fda.gov/drugsatfda_docs/label/1999/020638s003lbl.pdf Accessed May 23, 2022.
- [80] Infection control: home. Centers for Disease Control and Prevention; 2022. Updated June 16, 2022. <https://www.cdc.gov/poxvirus/monkeypox/clinicians/infection-control-home.html> Accessed July 8, 2022.
- [81] Treatment information for healthcare professionals. Centers for Disease Control and Prevention; 2022. Updated June 22, 2022. Accessed July 31, 2022. <https://www.cdc.gov/poxvirus/monkeypox/clinicians/treatment.html>.
- [82] Chimerix, Inc. Tembexa (brincidofovir) [package insert]. U.S. Food and Drug Administration Website; 2022. Updated June 2021. Accessed July 31, 2022. https://www.accessdata.fda.gov/drugsatfda_docs/label/2022/214518s000lbl.pdf.
- [83] Brincidofovir. Lexi-Drugs. Hudson, OH: Lexicomp; 2022. Updated April 19, 2022. Accessed July 31, 2022. <https://online.lexi.com/lco/action/home>.
- [84] Tembexa. Chimerix; 2022. Updated September 2021. Accessed July 31, 2022. <https://www.chimerix.com/products/tembexa/>.
- [85] Catalent Pharma Solutions. TPOXX (tecovirimat) [package insert]. U.S. Food and Drug Administration Website; 2022. Updated May 2022. Accessed July 31, 2022. www.accessdata.fda.gov/drugsatfda_docs/label/2022/214518s000lbl.pdf.
- [86] Smallpox prevention and treatment. Centers for Disease Control and Prevention; 2022. Updated October 18, 2021. Accessed July 31, 2022. <https://www.cdc.gov/smallpox/prevention-treatment/index.html>.
- [87] Tecovirimat. Lexi-Drugs. Hudson, OH: Lexicomp; 2022. Updated May 27, 2022. Accessed July 31, 2022. <https://online.lexi.com/lco/action/home>.
- [88] Cangene Corp. CNJ-106 (vaccinia immune globulin intravenous (human)) [package insert]. U.S. Food and Drug Administration Website; 2022. Updated January 2010. Accessed July 31, 2022. <https://www.fda.gov/media/77004/download>.
- [89] Vaccinia immune globulin. Lexi-Drugs. Hudson, OH: Lexicomp; 2022. Updated April 19, 2022. Accessed July 31, 2022. <https://online.lexi.com/lco/action/home>.
- [90] Monkeypox and smallpox vaccine guidance. Centers for Disease Control and Prevention; 2022. Updated June 2, 2022. Accessed Aug 2, 2022. <https://www.cdc.gov/poxvirus/monkeypox/clinicians/index.html>.