

# A Reproducible Ex Vivo Model for Transanal Minimally Invasive Surgery

Michael Larone Campbell, MD, Kimberly J. Vadas, Sowsan H. Rasheid, MD,  
Jorge E. Marcet, MD, Jaime E. Sanchez, MD

## ABSTRACT

**Background:** Rectal tumors can be excised through a number of minimally invasive transanal techniques including transanal excision, transanal endoscopic microsurgery, and transanal minimally invasive surgery (TAMIS). Specialty training is often required to master the nuances of these approaches. This study aimed to create a reproducible transanal excision training model that is suited for laparoendoscopic techniques.

**Methods:** Frozen porcine rectum and anus with intact perianal skin were commercially obtained. Thawed specimens were then cut to approximately 20 cm in length. The proximal end of the rectum was then everted and suction applied to the mucosa to create pseudopolyps of various sizes (sessile and pedunculated). Larger pedunculated lesions were made by tying the base of the pseudopolyps with 5–0 monofilament sutures to gather more tissue. Methylene blue dye was injected submucosally into the lesions to simulate tattoos. The proximal rectum was then closed with sutures. The model was suspended in a trainer box by clamping the distal end in a ringed clamp and the proximal end to the box. Transanal excisions using TAMIS were then performed. The procedures were done by trained community colorectal surgeons attending courses on transanal minimally invasive surgery.

**Results:** Both partial- and full-thickness excisions of sessile and pedunculated rectal lesions were successfully performed during simulated TAMIS by trained community surgeons learning this laparoendoscopic technique.

**Conclusion:** Transanal laparoendoscopic procedures to excise rectal tumors can be successfully and reproducibly performed in an ex vivo porcine anorectal model.

**Key Words:** Rectal neoplasm, Rectal surgery specialty, Minimally invasive surgical procedures, Colon and rectal surgery specialty, Animal model.

## INTRODUCTION

Transanal endoscopic microsurgery (TEM) for removal of benign rectal tumors and some select malignancies has been a mainstay surgical approach that offers advantages over traditional transanal surgical approaches. It provides improved visibility and resection margins, has been shown to reduce local tumor recurrence, and is associated with decreased morbidity in tumors located within the mid and proximal rectum.<sup>1</sup> However, TEM has limitations that have resulted in slow adoption by the medical community. It requires a very specialized set of instruments, which contributes to a steep learning curve.<sup>2</sup> Postsurgical anorectal function after TEM is also a concern depending on the extent or depth of tumor excision, which influences rectal compliance and rectoanal coordination. Resting anal pressures can also be lowered owing to sphincter defects.<sup>3</sup> More recently, transanal minimally invasive surgery (TAMIS), also known as *transanal single-port microsurgery* (TSPM), has emerged as a safe and feasible alternative to TEM.<sup>4–6</sup> The single-incision laparoscopic surgery ports (SILS port, Covidien, Mansfield, Massachusetts) used in abdominal laparoscopic surgery have properties that make them suitable for transanal excisions, including their flexibility of materials and multiple working channels. This technique involves introducing a SILS port into the anal canal, which allows for endoscopic access. A pneumorectum is achieved with insufflation, and standard laparoscopes and instruments are then used to perform transanal excisions. Our objective was to develop a realistic, reproducible, and cost-effective model to train surgeons in laparoendo

Department of Surgery, Division of Colon and Rectal Surgery, University of South Florida, Tampa, FL, USA (Drs. Campbell, Rasheid, Marcet, Sanchez).

Center for Advanced Medical Learning and Simulation, University of South Florida, Tampa, FL, USA (Dr. Vadas).

Address correspondence to: Michael Larone Campbell, MD, Department of Surgery, Division of Colon and Rectal Surgery, University of South Florida, Tampa, FL 33606. Telephone: (813) 844-4545, Fax: (813) 844-3976, E-mail: mcampbe1@health.usf.edu.

DOI: 10.4293/108680813X13693422518911

© 2014 by JSLS, *Journal of the Society of Laparoendoscopic Surgeons*. Published by the Society of Laparoendoscopic Surgeons, Inc.

scopic transanal excision according to the principles of TAMIS.

## MATERIALS AND METHODS

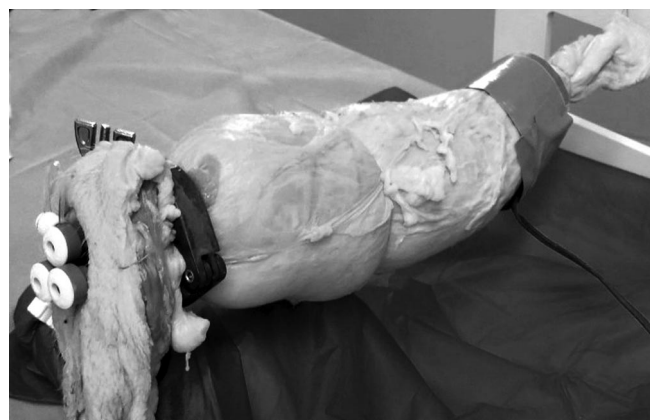### Training Model

Frozen porcine rectum and anus with intact perianal skin were commercially obtained. The specimens were thawed and cut to an ~20-cm length from the anal verge. The proximal end of the rectum was then everted, and suction was applied to the mucosa using a Yankauer-type suction tip to create pseudopolyps of various sizes (sessile and pedunculated). Larger pedunculated lesions were created by tying the base of the pseudopolyps with 5-0 monofilament sutures to gather more tissue. Methylene blue dye was injected submucosally into the lesions to simulate tattoos. The proximal rectum was then closed with sutures. Any defects in the rectal wall were repaired with 2-0 monofilament sutures.

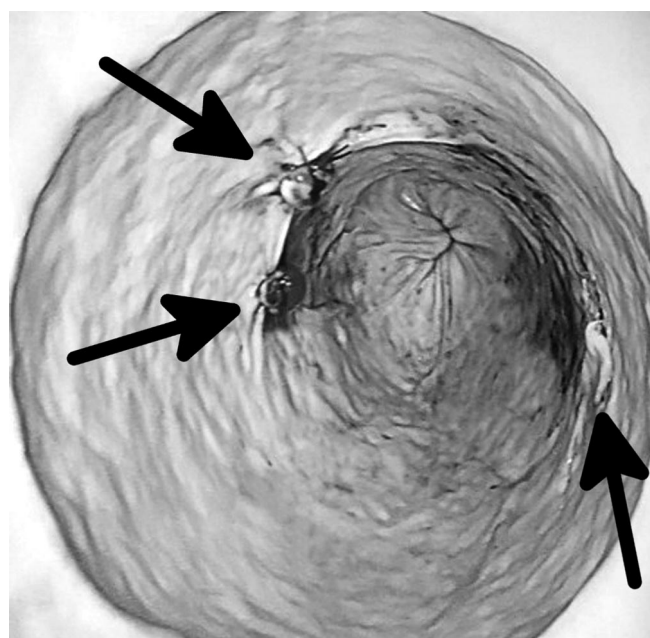
An O-ring clamp and trainer box were used to house the model. The O-ring clamp was used to mount the anus distally, and the ringed clamp was then placed inside a trainer box and the specimen suspended by using sutures to loosely attach the proximal end of the specimen to the trainer box. Care was taken to avoid tension in the suspended specimen to simulate the *in vivo* rectum. An adhesive pediatric electrocautery grounding pad was attached to the specimen and then secured with duct tape. Table salt was added to the pad before placement to improve conductivity in this *ex vivo* model (**Figure 1**). The SILS port was then lubricated and inserted transanally. A pneumorectum was achieved up to a pressure of 12 mm Hg for training purposes. Suturing was then tied around the insufflated rectum in 3 locations to simulate rectal valves.

### Simulation Training

Twenty community colorectal surgeons participated in the TAMIS training: no participants had prior training or experience in TAMIS. Participants were asked to perform various transanal excisions using the laparoendoscopic technique using the SILS port. They were required to lubricate and insert the SILS port transanally using gentle, manual pressure; achieve a pneumorectum; perform an endoluminal exploration; and finally excise various pseudopolyps using sheers, laparoscopic electrocautery, and laparoscopic harmonic devices.



**Figure 1.** Completed porcine TAMIS model with the single-incision port in place.



**Figure 2.** Simulated pedunculated and sessile polyps.

Full-thickness resections and laparoendoscopic suturing of the defects with Endo Stitch (Covidien) and laparoscopic needle drivers were also required. Lesions were tactically placed distally, proximally, and in the midrectum to emphasize challenges inherent to each particular resection including that of polyps located behind the rectal valves (**Figure 2**). Each participant had one assistant to operate the laparoscopic camera (**Figure 3**). Expert colorectal surgeons who were experienced with TAMIS, and who had all previously vali-



**Figure 3.** Simulated operative setup for TAMIS training.

dated the model, were available for proctoring participants until each task was completed successfully.

### Evaluation

Participants were provided with a questionnaire that asked whether the simulation model is useful in learning TAMIS, whether training increased confidence in performing TAMIS, and whether they were likely to incorporate TAMIS into their practice. The cost of producing each model was also calculated.

### RESULTS

All 20 participants were able to successfully complete all assigned tasks. This was determined by observing each surgeon excise the polyps and suture the defects using the TAMIS model. Ten of 12 (83%) survey responders reported that the simulation model was useful in learning TAMIS, that training increased confidence in performing TAMIS, and that they were likely to incorporate TAMIS into their practice.

The total parts cost per model was approximately \$50 (suction mount, ringed clamp, pig rectum). Standard and reusable surgical hardware and permanent equipment typical of a training lab were not included in the calculated cost (eg, laparoscopic instruments, SILS port, hemostats, scissors, sutures).

### DISCUSSION

Benign and early-stage malignant neoplasms in the lower rectum can typically be excised transanally using standard surgical instruments. Limited visibility and access have made these procedures challenging, and they are usually restricted to excising very low rectal tumors. Higher lesions are not amenable to conventional transanal excision owing to a narrow anal canal, which limits the surgical field. TEM was introduced in the 1980s by Buess et al and has made transanal excision of lesions in the middle and proximal rectum possible.<sup>7</sup> However, TEM remains a tedious procedure that requires specialized equipment. The advantages of TAMIS over TEM are well documented. By using a standard single-incision laparoscopic port in the anus, standard laparoscopic insufflation, instruments, and energy devices can be used, thus providing access to the middle and proximal rectum.<sup>4–6,8</sup> Laparoscopic magnification enables a more precise dissection compared with the open technique as well. Compared with the rigid TEM rectoscope, the single-incision laparoscopic port also exerts less tension on the anal sphincters and may reduce postoperative anorectal dysfunction. There are some limitations with TAMIS, however. Because the port is not rigidly fixed, to prevent the port from completely disengaging, suturing it to the perianal skin may be required. Suturing and knot-tying in TAMIS may also be challenging because all instruments are working in-line as other single-incision applications. Our model allows the surgeon to practice knot-tying using single-port techniques.

All trainees were able to successfully complete all tasks using our model. These included preparing the model by inserting the single-incision laparoscopic surgery port, achieving a pneumorectum, resecting lesions in the middle and proximal rectum, and performing closure of all defects. Most participants indicated that the simulation made them more confident in TAMIS and that they were likely to incorporate it into their practice. All parts for developing this model are commercially available at minimum cost. We plan on further using our model in validation studies.

### CONCLUSION

This simple and cost-effective ex vivo porcine model can be used reliably to train surgeons in TAMIS. Community surgeons found this to be a useful tool for acquiring the basic skills needed to perform TAMIS before embarking on attempting the procedure in their patients.

**References:**

1. Guillem JG, Chessin DB, Jeong SY, et al. Contemporary applications of transanal endoscopic microsurgery: technical innovations and limitations. *Clin Colorectal Cancer*. 2005;5:268–273.
2. Middleton PF, Sutherland LM, Maddern GJ. Transanal endoscopic microsurgery: a systematic review. *Dis Colon Rectum*. 2005;48:270–284.
3. Herman RM, Richter P, Walega P, Popiela T. Anorectal sphincter function and rectal barostat study in patients following transanal endoscopic microsurgery. *Int J Colorectal Dis*. 2001;16:370–376.
4. Atallah S, Albert M, Larach S. Transanal minimally invasive surgery: a giant leap forward. *Surg Endosc*. 2010;24(9):2200–2205.
5. Lorenz C, Nimmesgern T, Back M, Langwieler TE. Transanal single port microsurgery (TSPM) as a modified technique of transanal endoscopic microsurgery (TEM). *Surg Innov*. 2010; 17(2):160–163.
6. Lim SB, Seo SI, Lee JL, et al. Feasibility of transanal minimally invasive surgery for mid-rectal lesions. *Surg Endosc*. 2012;26(11): 3127–3132.
7. Buess G, Theiss R, Gunther M, et al. Endoscopic surgery in the rectum. *Endoscopy*. 1985;17:31–35.
8. van den Boezem PB, Kruyt PM, Stommel MW, et al. Transanal single-port surgery for the resection of large polyps. *Dig Surg*. 2011;28(5–6):412–416.