



Contents lists available at ScienceDirect

Indian Pacing and Electrophysiology Journal

journal homepage: www.elsevier.com/locate/IPEJ

Un-LINQed: Spontaneous extrusion of newer generation implantable loop recorders

Joseph Zakhar^a, Thomas J. Blount^b, Anil K. Gehi^c, Sunita J. Ferns^{d,*}^a Department of Pediatrics, University of Colorado, Denver, 13123 E 16th Ave, Aurora, CO, 80045, USA^b Department of Pediatrics, Washington University School of Medicine, St Louis, 1Brooklings Drive, St Louis, MO, 63130, USA^c Department of Medicine, UNC Chapel Hill, 101 Manning Drive, Chapel Hill, NC, 27514, USA^d Department of Pediatrics, University of Florida at Jacksonville, 841 Prudential Drive, Jacksonville, FL, 32207, USA

ARTICLE INFO

Article history:

Received 29 March 2020

Accepted 8 April 2020

Available online 13 April 2020

Keywords:

Implantable loop recorder (ILR)

Insertable cardiac monitor (ICM)

Arrhythmia monitoring

Device extrusion

Pediatric electrophysiology

ABSTRACT

Background: Insertable cardiac monitors (ICMs) are often used for long-term monitoring of cardiac rhythm. The Medtronic's LINQ Reveal™ is a new generation wireless, automated, and patient responsive subcutaneous ECG monitoring device. Despite several advantages to its small size we have noted an unusually high incidence of extrusion at our center.

Methods: & **Results:** We conducted a retrospective case analysis to review Reveal LINQs implanted at our center. All devices were inserted using the provided insertion tools. Patients with extruded devices were identified and details regarding the site and technique of insertion, incision closure, use of peri-operative antibiotics, and follow-up details were collected. 81 patients underwent 85 Reveal LINQ implants at a tertiary care University Hospital referral center. The most common reason for implant was suspected arrhythmia with or without structural heart disease or unexplained syncope. There were 4 spontaneous extrusions occurring within 7–24 days after insertion with an incidence rate of 4.7%. One extruded device was anchored to subcutaneous tissue, and no pocket/device infections or hematomas were noted. **Conclusions:** Device migration and erosion through skin are important potential adverse events for the Reveal LINQ implantable loop recorder. This study reports an unexpectedly high rate of extrusion without infection. The authors suggest that the depth of the incision is the main factor impacting extrusions. Larger studies are recommended, however, and a proposed measure to avoid spontaneous extrusion is the design of a longer manufacturer's blade in order to increase the depth of the incision and insertion.

Copyright © 2020, Indian Heart Rhythm Society. Production and hosting by Elsevier B.V. This is an open access article under the CC BY-NC-ND license (<http://creativecommons.org/licenses/by-nc-nd/4.0/>).

1. Introduction

Implantable cardiac monitors (ICMs) have been used for years for long-term monitoring of cardiac rhythm in patients with or without known arrhythmias or structural heart disease [1]. The Medtronic's LINQ Reveal™ is a new generation wireless, automated, and patient responsive subcutaneous ECG monitoring device 87% smaller than its predecessor measuring 1 cc in size. It is placed in the subcutaneous plane utilizing the manufacturer's tool [2] As compared to its predecessor, its minimally invasive technique of implantation allows for the potential of implant in an outpatient setting, improved patient comfort, speedy recovery, and

reduction in implantation costs. Despite several advantages to a small size, the authors have noted an unusually high incidence of extrusion. This study seeks to evaluate the extrusion rate and factors contributing to extrusion in this population of patients.

2. Method

2.1. Study design

Single center retrospective observational study on patients undergoing new generation Reveal LINQ implant at a tertiary care university hospital.

Patient demographics, indication for implant, medications, peri-procedural data including site of insertion, duration of implant, technique utilized for insertion, wound closure, use of peri or post-operative antibiotics and follow up details were noted. The study was approved by the Institutional Review Board.

* Corresponding author. 841 Prudential Drive, Jacksonville, FL, 32207, USA.

E-mail address: Sunita.ferns@jax.ufl.edu (S.J. Ferns).

Peer review under responsibility of Indian Heart Rhythm Society.

2.2. Device implantation

All devices were implanted in the EP lab and not in an outpatient setting. In all cases implants were performed by electrophysiologists trained in the technique. The implant was performed using the provided insertion and incision tools and in accordance with the recommendations in the manufactures guidelines [2]. Local anesthesia was administered in most cases with the use of conscious sedation in a very small subgroup. Standard aseptic precautions were utilized in accord with hospital policies for device implants. These included use of a cap, mask, sterile gown and glove use by all staff members involved in the procedure. Skin preparation included the use of a chlorhexidine swab and a sterile drape. The LINQ tool was used to make the incision at a 45° angle to the subcutaneous plane (Fig. 1). The device was then injected into the pocket using the preloaded tool. Limitations in the length of the insertion tool made a deep incision difficult and therefore we used a size 11 blade to deepen the pocket in our teenage and adult patients. The tool was removed and the pocket was closed using an absorbable subcutaneous suture as well as a variety of superficial incision closure techniques noted in the results below. Peri-procedural antibiotics, were administered on a case by case basis. In patients that received post-operative prophylaxis, oral antibiotics were administered for 3 days.

2.3. Follow up

All patients underwent a routine wound check at our device clinic or with their primary care physician within 10–14 days of insertion. Patients were advised to keep the wound dry for at least 5

days post implantation. Wound non-closure was deemed to have occurred if the incision reopened with the device protruding through Fig. 2. Device hematoma was diagnosed if there was blood accumulation in the pocket leading to swelling, pain and discoloration. Device infection was diagnosed if the patient had purulent discharge, pain, or fever and signs of infection such as non-approximation of the wound, redness, or tenderness. Wound cultures were sent as indicated.

2.4. Statistical analysis

All data is expressed as mean (SD) for continuous variables. Categorical variables are represented as proportions. Continuous variables were analyzed using a student t-test when normally distributed and a Mann Whitney *U* test for non-normal distributions. Categorical variables were analyzed with a chi-square test. Analytical conclusions were limited by small numbers in the group with the spontaneous extrusion.

3. Results

81 patients underwent 85 Reveal LINQ implants at a tertiary care University Hospital referral center during a two year period. Patient demographics and study characteristics are detailed in Table 1. The most common reason for implant was suspected arrhythmia with or without structural heart disease or unexplained syncope (Table 1). There were 4 spontaneous extrusions of devices in three patients occurring within 7–24 days after insertion with an incidence rate of 4.7%. There was slight variability in the technique of pocket closure noted in each case. In every case the skin edges were opposed with an absorbable subcutaneous suture as well as superficial closure using either topical skin adhesive, steri strips, or staples. In one case with a device extrusion the device was physically anchored to the subcutaneous tissue in the pocket with absorbable suture material. Two patients were on chronic anticoagulation, however, the wound was noted to be hemostatic despite the extrusion. All extrusions were reported to be pain free. There were no device or pocket infections noted in any case (Table 2).

4. Discussion

Implantable cardiac monitors are important tools for the detection of arrhythmias in patients with infrequent symptoms [1]. In addition to being a useful diagnostic tool, implantable devices also play an important role in monitoring activity of known and

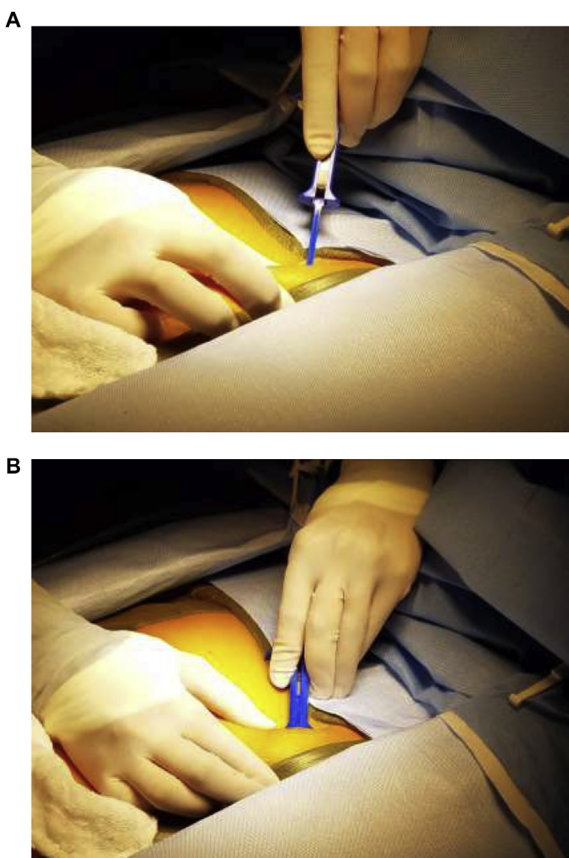


Fig. 1. a,b: Technique of implantation.

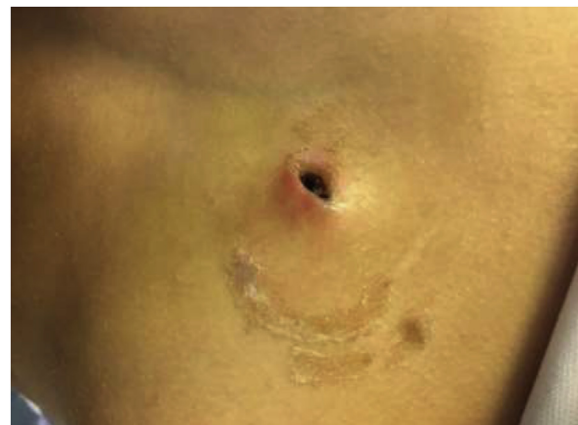

Fig. 2. Extrusion, view from patient's left.

Table 1
Study population characteristics.

Patient Characteristics	Non extruded	Extruded	P value
Age	54 (49.4–58.4)	39.6 (17.6–97)	0.18
Sex(F:M)	33:48	2:2	–
Weight	90.7 (84.7–96.5)	68.2 (13.8–150.2)	0.12
Height	173.2 (170–176.3)	154.5 (91.9–217.1)	0.4
BMI	29.98 (28.21–31.75)	24.14 (10.4–37.9)	0.27
Race			
• Caucasian	66	4	–
• Hispanic	4	0	
• African-American	9	0	
• Other	1	0	
Comorbid conditions			
• Diabetic	16	1	–
• Renal failure	3	1	
• Other chronic illness	38	0	
Hospitalization	18	0	
Anticoagulants			
• NOACS	19	1	–
• Coumadin	10	1	
Blood thinners			
• Aspirin	17	0	
• Plavix	2	0	
INR on warfarin	1.3 (1.1–1.4)	–	–
Use of antibiotics			
• Pre and post procedure	3	0	–
• Pre procedure	35	3	
• Post procedure	5	0	
• None	37	1	
Indication for implant			
• Palpitations	41	3	–
• Syncope	35	1	
• Pre-syncope	1	0	
• Cryptogenic stroke	3	0	
Procedure Time(mins)	7.41 (6.29–8.53)	7.5 (1.5–15)	0.97
Superficial closure technique			
• Sutures	28	1	–
• Dermabond glue	30	3	
• Steristrips	20	0	
• Staples	1	0	

medically managed arrhythmias. They are useful for tailoring therapy in patients with atrial fibrillation or for risk stratification after a myocardial infarction [3–6]. Because of the ease of subcutaneous implantation and their ability to monitor continuously for long periods of time, they have become an important tool for the electrophysiologist. An implied imperative to the effectiveness of ICMs are that they remain a stable and reliable method of cardiac rhythm monitoring – namely, they need to stay inside the patient.

Though the Reveal LINQ has been used widely in the last three years since its availability, data regarding complications in the LINQ are relatively few. The three large multicenter trials on Reveal LINQ usability do not report spontaneous extrusion as a complication [7,8]. Our study highlights a relatively high incidence of spontaneous extrusion of the Reveal LINQ compared to the investigator

trials. Two of the extrusions occurred in a pediatric patient with scant subcutaneous tissue and two adult patients were on chronic anti-coagulation. The number of extrusions, however, were too small to draw any meaningful statistical conclusions. We also highlight the differences in technique with closure and peri-procedural antibiotic use within our institution but note that these do not seem to impact device extrusion.

All of our cases were performed using the Medtronic preferred location and tool [2]. Lakkireddy et al. have shown a higher incidence of overall complications and infection rate when using the manufacturer’s method of insertion. They hypothesize that the wide mouth large beveled edge created by the relatively shallow and wide manufacturers tool, if not sutured, can open up leading to spontaneous extrusion and have recommended a suture placement in order to minimize this risk [9]. The device manual recommends using a suture to secure the device to underlying tissue, if deemed necessary, and recommends site closure using any method preferred by the provider [2]. Unlike the older generation device, the small size of the skin incision with the device in a subcutaneous location can make a suture placement challenging. There is currently wide variability in reported methods used to secure the device and close the pocket for the LINQ. Two prospective trials report the use of either sutures, staples, surgical glue, or adhesive strips or some combination of these methods [7,8]. The authors in this study have not noted a difference in extrusions based on type of closure used. In fact, two of four devices that were extruded in the study were sutured down.

All patients in the current study had the device implanted in the manufacturers preferred location. In the Usability and Investigator trial the manufacturer’s preferred location was used by 77.2 and 92.1% providers, respectively [7]. Different device insertion locations may be chosen depending on the patient’s body habitus and amount of subcutaneous or breast tissue. Based on the limited available data, however, there has been no identified difference in outcomes based on chosen site for insertion [7,8].

The authors do feel that the depth of the incision makes a difference to the extrusion rate. The tool provided does not allow for a sufficiently deep incision and one way to overcome this limitation is the use of size 11 blade. Moreover the thickness of skin that an operator can pinch before deploying the tool may also affect placement and help with device deployment in a deeper plane.

Chaouki et al. have reported the only other instance of spontaneous device extrusion in a child [10]. They hypothesized that the device migrated due to a smaller subcutaneous pocket in a young child. Two of the extrusions in the current study occurred in a pediatric patient with relatively scant subcutaneous tissue as compared to other pediatric patients in the study.

A recent study by Gundaa et al. compared infection rates in Reveal LINQ as compared to the Reveal XT and found a higher rate of infection at 12% in the LINQ group. The Reveal LINQ investigator trials report an infection rate ranging from 0.8 to 3% and no extrusions [7,8,11]. Despite a high spontaneous extrusion rate in the current study, there were no infections. The authors feel that their

Table 2
Characteristics of patients with spontaneous device extrusion.

Explant	Age (yrs)	Sex	BSA (m ²)	Indication for implant	Procedure time (min)	Antibiotic	Blood thinner	Superficial Closure technique	Comorbid condition
1	74	M	2.2	Syncope	3	No	Yes	Dermabond	Coronary artery disease, hypertension, hyperlipidemia, hypothyroidism
2	67	M	2.6	Palpitation	10	Yes	Yes	Suture and Dermabond	No
3	8	F	0.9	Palpitation	4	Yes	No	Dermabond	Genetic arrhythmic syndrome
4	8.5	F	0.9	Palpitation	13	Yes	No	Suture and Dermabond	Genetic arrhythmic syndrome

utilization of similar aseptic techniques for the implantable loop recorders as those for transvenous devices have contributed to their low infection rate. The use of prophylactic antibiotics during implantable loop procedures is a carryover of the common practice used with therapeutic cardiac implantable electronic devices. As such, the manufacturer's guidelines for the Reveal LINQ do not specifically recommend a practice and it is often left to the clinical judgement of the operator. One of the larger multicenter registry studies report that two-thirds of patients do not receive pre-procedural antibiotics and yet have an extremely low infection rate of 0.8% [9]. The use of prophylactic antibiotics with the Reveal LINQ has been reported at about 50% in both the investigator trial group and Gundaa et al. [7,8]. The current study shows a similar figure with the use of antibiotics in 54% of patients with no infections noted irrespective of whether antibiotics were used. The data so far would suggest that it may be safe to not administer antibiotics prophylactically in loop implants.

5. Conclusion

Device migration and erosion through the skin are important potential adverse events for the reveal LINQ implantable loop recorder. The current study reports an unexpectedly high rate of extrusion without infection in this study. They authors do feel that the depth of the incision is the main factor impacting extrusions. Proposed measures to avoid spontaneous extrusion in this population includes design of a longer manufacturer's blade in order to increase the depth of the incision.

Author contributions

Joseph Zakhar MD – Concept/design, data analysis/interpretation, drafting and critical revision of article.

Thomas J Blount MD – Chart review data collection and analysis.

Anil K Gehi MD – Clinical data collection.

Sunita J Ferns MD – Concept/design, data analysis/interpretation, drafting and critical revision of article, approval of article, statistics.

Declaration of competing interest

Joseph Zakhar MD – None.

Thomas J Blount MD – None.

Anil K Gehi MD – Speakers' Honoraria (St Jude Medical, Biotronik).

Sunita J Ferns MD –None.

CRedit authorship contribution statement

Joseph Zakhar: Conceptualization, Formal analysis, Writing - original draft, Writing - review & editing. **Thomas J. Blount:** Formal analysis, Data curation. **Anil K. Gehi:** Data curation. **Sunita J. Ferns:** Conceptualization, Formal analysis, Writing - original draft, Writing - review & editing.

References

- [1] Bloemers BL, Sreeram N. Implantable loop recorders in pediatric practice. *J Electrocardiol* 2002;35(Suppl):131–5.
- [2] Medtronic. Reveal linq LNQ11 insertable cardiac monitor. Clin. Manual 2015. http://manuals.medtronic.com/wcm/groups/mdtcom_sg/@emanuals/@era/@crdm/documents/documents/contrib_185856.pdf. Accessed 11/1/2016, 2016.
- [3] Hanke T, Charitos EI, Stierle U, Karluss A, Kraatz E, Graf B, Hagemann A, Misfeld M, Sievers HH. Twenty-four-hour Holter monitor follow-up does not provide accurate heart rhythm status after surgical atrial fibrillation ablation therapy—up to 12 months experience with a novel permanently implantable heart rhythm monitor device. *Circulation* 2009;120(suppl 1):S177–84.
- [4] Hindricks G, Pokushalov E, Urban L, Taborsky M, Kuck KH, Lebedev D, Rieger G, Pürerfellner H. Performance of a new leadless implantable cardiac monitor in detecting and quantifying atrial fibrillation: results of the XPECT trial. *Circ Arrhythm Electrophysiol* 2010;3(2):141–7.
- [5] Bloch Thomsen PE, Jons C, Pekka Raatikainen MJ, Moerch Joergensen R, Hartikainen J, Virtanen V, Boland J, Anttonen O, Uj Gang, Hoest N, Boersma LV, Platou ES, Becker D, Messier MD, Huikuri HV. Long-term recording of cardiac arrhythmias with an implantable cardiac monitor in patients with reduced ejection fraction after acute myocardial infarction. The Cardiac Arrhythmias and Risk Stratification after Acute Myocardial Infarction (CARISMA) Study. *Circulation* 2010;122(13):1258–64.
- [6] Uj Gang, Jøns C, Jørgensen RM, Abildstrøm SZ, Messier MD, Haarbo J, Huikuri HV, Thomsen PE. Risk markers of late high degree atrioventricular block in patients with left ventricular dysfunction after an acute myocardial infarction: a CARISMA substudy. *Europace* 2011;13(10):1471–7.
- [7] Mittal S, Sanders P, Pokushalov E, Dekker L, Kereiakes D, Schloss EJ, Poullet E, Franco N, Zhong Y, Di Bacco M, Pürerfellner H. Safety profile of a miniaturized insertable cardiac monitor: results from two prospective trials. *Pacing Clin Electrophysiol : PACE (Pacing Clin Electrophysiol)* 2015;38(12):1464–9.
- [8] Pürerfellner H, Sanders P, Pokushalov E, Di Bacco M, Bergemann T, Dekker LR. Reveal LINQ usability study investigators.. Miniaturized reveal LINQ insertable cardiac monitoring system: first-in-human experience. *Heart Rhythm* 2015 Jun;12(6):1113–9.
- [9] Gundaa S, Reddy YM, Pillarisetti J, Koripalli S, Jeffery C, Swope J, Atkins D, Bommana S, Emert MP, Pimentel R, Dendi R, Berenbom LD, DiBiase L, Natale A, Lakkireddy D. Initial real world experience with a novel insertable (Reveal LinQ@Medtronic) compared to the conventional (Reveal XT@Medtronic) implantable loop recorder at a tertiary care center - points to ponder! *Int J Cardiol* 2015 Jul 15;191:58–63.
- [10] Chaouki AS, Czosek RJ, Spar DS. Missing LINQ: extrusion of a new-generation implantable loop recorder in a child. *Cardiol Young* 2016;1–3.
- [11] Beinart SC, Natale A, Verma A, Amin A, Kasner S, Diener HC, Poullet E, Franco N, Mittal S. Real-World use of prophylactic antibiotics in insertable cardiac monitor procedures. *Pacing Clin Electrophysiol : PACE (Pacing Clin Electrophysiol)* 2016;39(8):837–42.