

Safety of besifloxacin ophthalmic suspension 0.6% as a prophylactic antibiotic following routine cataract surgery: results of a prospective, parallel-group, investigator-masked study

Ranjan Malhotra¹
Joseph Gira²
Gregg J Berdy¹
Robert Brusatti¹

¹Ophthalmology Associates,
²Ophthalmology Consultants,
St Louis, MO, USA

Background: The purpose of this study was to evaluate the safety and tolerability of besifloxacin ophthalmic suspension 0.6% compared with moxifloxacin ophthalmic solution 0.5%, when used for infection prophylaxis following uncomplicated phacoemulsification clear cornea surgery using sutureless corneal incision.

Methods: This prospective, two-site, parallel-group, investigator-masked clinical study included patients aged ≥ 18 years scheduled to undergo phacoemulsification with intraocular lens implantation. Patients received one drop of either besifloxacin ophthalmic suspension or moxifloxacin ophthalmic solution four times daily, beginning 3 days prior to surgery, which was continued for 7 days postoperatively. The primary endpoint was the rate of adverse events. Secondary endpoints included endothelial cell count, central corneal thickness, and overall and central corneal staining measured on days 7 (± 1 day) and 28 (± 2 days) following surgery, and intraocular pressure and best-corrected visual acuity measured on days 1, 7 (± 1 day), and 28 (± 2 days) following surgery.

Results: Of the 60 patients enrolled, 58 (29 per treatment group) completed the study. No adverse events were reported in either treatment group. Changes in the central corneal thickness, endothelial cell count, and corneal staining were small and similar between treatments at follow-up visits ($P \geq 0.1549$). Intraocular pressure was similar between treatment groups at each visit, as was the distribution of best-corrected visual acuity. The final best-corrected visual acuity was 20/30 or better in 85% of the patients.

Conclusion: In this study, besifloxacin ophthalmic suspension 0.6% was well tolerated when used prophylactically to prevent postoperative endophthalmitis following sutureless cataract surgery.

Keywords: besifloxacin, moxifloxacin, corneal integrity, DuraSite[®], phacoemulsification, endophthalmitis

Introduction

Cataracts are prevalent, particularly in the elderly population. Recent estimates indicate that nearly 17.2% of Americans aged older than 40 years have a cataract in either eye, and this percentage is expected to rise to about 50% in the next 10 years.¹ According to National Eye Institute estimates, more than 50% of Americans have a cataract or have undergone cataract surgery by the age of 80 years.² Apart from being associated with age, cataract development is associated with certain chronic diseases such as diabetes, chronic renal failure, mitral valve prolapse, and bific aortic valve.³

Correspondence: Ranjan Malhotra
12990 Manchester Road, Suite 200,
St Louis, MO 63131, USA
Tel +1 314 966 5000
Fax +1 314 909 6666
Email ranjan.malhotra@youreyedoc.com

Of the methods available for cataract surgery, phacoemulsification is preferred over extracapsular cataract extraction because of its clinical superiority and cost-effectiveness.⁴ Although cataract extraction is relatively safe and patients return to normal activity quickly, one of the biggest concerns associated with cataract surgery is the occurrence of postoperative infection, particularly endophthalmitis.⁵ Endophthalmitis includes a broad range of bacterial and fungal eye infections that can have deleterious outcomes such as reduced visual acuity, high intraocular pressure,⁶ and permanent vision loss.⁷ Studies have revealed that the normal ocular and periocular flora of the patient represent the biggest source of bacteria causing infection.^{8,9} Occasionally, nosocomial factors and/or colonized health care professionals may increase the risk of endophthalmitis.³ Apart from various external factors, the surgical procedure itself may contribute to the risk of endophthalmitis. For example, the type, size, and location of the incision in cataract surgery have been associated with the occurrence of endophthalmitis.¹⁰

Prophylactic treatments aimed at minimizing microbes causing endophthalmitis include using topical antibiotic eye drops before surgery, applying 5% povidone iodine to the conjunctival sac, preparing the periocular skin with 10% povidone iodine, careful sterile draping of the eyelid margins and eyelashes, adding antibiotics to the irrigating solution, instilling intracameral antibiotics at the close of surgery, injecting subconjunctival antibiotics, and applying topical antibiotic eye drops after surgery.¹¹ Research has shown that topical quinolones, specifically gatifloxacin and moxifloxacin,^{12,13} when administered perioperatively can significantly reduce the risk of endophthalmitis following cataract surgery. A recent online survey reported that a majority of the members of the American Society of Cataract and Refractive Surgery also preferred topical antibiotic prophylaxis prior to and after cataract surgery.¹⁴

Emerging bacterial resistance is an important consideration when choosing a topical antibiotic for infection prophylaxis in the surgical setting.¹³ In a recent study, it was reported that the majority of bacteria present in the periocular flora belong to the *Staphylococcus* family and mainly include *Staphylococcus epidermidis* (about 62%) and *Staphylococcus aureus* (about 14%).¹⁵ Of the bacterial cultures that were isolated in the study, about 47% of *S. epidermidis* and 29% of *S. aureus* exhibited methicillin resistance.¹⁵ Results from the Antibiotic Resistance Monitoring in Ocular Microorganisms (ARMOR) surveillance study indicate that methicillin-resistant staphylococci are also likely to be resistant to a number of other antibiotics, including aminoglycosides,

macrolides, and some fluoroquinolones.¹⁶ Moreover, a study of bacterial isolates from patients with endophthalmitis reported that among Gram-positive bacteria, resistance to fluoroquinolones was common, with a significant number of isolates resistant to gatifloxacin and moxifloxacin.¹⁷ Thus, there is a constant need for the development of broad-spectrum antibiotics that are effective against drug-resistant staphylococci.

Besifloxacin ophthalmic suspension 0.6% (Besivance[®]; Bausch and Lomb Inc, Rochester, NY) was approved in 2009 by the US Food and Drug Administration for ophthalmic use, and has been shown to be effective for the treatment of bacterial conjunctivitis.^{18–22} It is a topical chlorofluoroquinolone that targets both DNA gyrase and topoisomerase IV,²³ and has been indicated for use against a broad range of bacteria, including *Staphylococcus*, *Streptococcus*, and *Corynebacterium* species.²⁴ In addition to the Gram-positive bacteria, besifloxacin has also shown efficacy in treating infections caused by Gram-negative bacteria, such as *Moraxella* species and *Haemophilus influenzae*.²⁵ The besifloxacin formulation includes DuraSite[®] (InSite Vision Inc, Alameda, CA), a mucoadhesive vehicle designed to increase the ocular surface residence time of a drug. The main component of DuraSite is polycarbophil, a mucoadhesive polymer consisting of polyacrylic acid molecules cross-linked with divinyl glycol that does not degrade or breakdown in the body.²⁶ The use of polycarbophil for sustained release of drugs was suggested in the 1980s,²⁷ and has subsequently been extensively validated for ocular antibiotic drug delivery.^{28–30} On coming into contact with tears on the ocular surface, the polycarbophil expands, forming large, stable, gel-like particles that exhibit increased viscosity and are less likely to get washed away with lacrimal discharge.²⁶ This increases the overall residence time of the drug on the ocular surface and, therefore, its bactericidal activity. Although the efficacy and safety of the DuraSite vehicle for ophthalmic drug delivery has been previously demonstrated,³⁰ authors of a recent preclinical study in rabbits, in which DuraSite-containing antibiotic formulations were injected directly into the anterior chamber, suggested that such formulations should be used with caution in cataract surgery with clear corneal incisions.³¹

The objective of this study was to evaluate the safety and tolerability of besifloxacin ophthalmic suspension 0.6% as compared with a non-DuraSite-based antibiotic formulation, moxifloxacin ophthalmic solution 0.5% (Vigamox[®], Alcon Laboratories Inc, Fort Worth, TX), when used prophylactically for infections associated with uncomplicated sutureless cataract extraction by phacoemulsification.

Materials and methods

Study design

This prospective, parallel-group, investigator-masked study (ClinicalTrials.gov identifier: NCT01455233) was carried out at two clinical sites in the US following approval by Schulman Associates Institutional Review Board Incorporated (Cincinnati, OH), and was conducted in accordance with the International Conference on Harmonisation of Good Clinical Practices guidelines and the Declaration of Helsinki (1996). Informed consent was obtained from all patients prior to study initiation. Consecutive patients undergoing cataract surgery were alternately assigned to treatment with besifloxacin ophthalmic suspension 0.6% or moxifloxacin ophthalmic solution 0.5% used prophylactically to prevent postoperative endophthalmitis. The primary objective of the study was to compare the adverse event rates of besifloxacin ophthalmic suspension and moxifloxacin ophthalmic solution.

Participants

Patients included in the study were ≥ 18 years of age and scheduled to undergo cataract extraction by phacoemulsification with posterior chamber intraocular lens implantation. Patients were excluded from the study if they were scheduled to undergo other procedures during cataract surgery, with the exception of a limbal relaxing incision for astigmatism correction. Patients were also excluded from the study if any of the following were noted: topical ocular or systemic antibiotic usage within 14 days prior to the surgery; history of Fuch's corneal endothelial dystrophy; ocular inflammation, ocular pain, or aqueous flare greater than grade 0 in the study eye at baseline; recent ocular trauma or surgery in the study eye within the previous 6 months; history of chronic or recurrent inflammatory eye disease or uncontrolled glaucoma in the operative eye; congenital ocular anomaly; a nonfunctional fellow eye defined as an eye with best-corrected visual acuity < 35 ETDRS letters (20/200 Snellen equivalent); participation in any drug or device study within 30 days before cataract surgery; or known or suspected allergy/hypersensitivity to any component of either of the study treatments. Women of childbearing age were excluded from the study if they were pregnant, breastfeeding, intended to become pregnant, or did not agree to use adequate, approved birth control measures during the study. In addition, a patient could be considered ineligible because of a valid medical reason based on the investigator's discretion.

Interventions and assessments

At each clinical site, eligible patients undergoing cataract surgery were alternately assigned to treatment with either

besifloxacin ophthalmic suspension 0.6% or moxifloxacin ophthalmic solution 0.5% as they enrolled in the study. To mask the investigators to treatments, treatment assignments were made by the clinical study coordinator at each site. Baseline measurements were recorded any time between week 4 and day 4 before the surgery. Patients were instructed to instill one drop of the assigned study treatment topically four times per day, starting 3 days prior to the surgery. Patients were not masked to the study treatment.

On the day of surgery (day 0), clinical study coordinators reviewed the dosing regimen with patients, following which all patients underwent cataract extraction with a Stellaris™ phacoemulsification machine (Bausch and Lomb Inc., Rochester, NY) by one of three surgeons via a clear corneal incision accompanied by stromal hydration. No sutures were necessary in any cases included in this study. The following parameters indicative of safety and tolerability were measured on the day of surgery (day 0) and on days 7 (± 1 day) and 28 (± 2 days) following surgery: corneal thickness measured using the DGH-55 Pachmate (DGH Technologies, Exton, PA) or Pachette 3 pachymeters (DGH Technologies, Exton, PA); endothelial cell count, using a Konan NonCon Specular microscope; overall and central corneal staining, using the 0–3 National Eye Institute scale; best-corrected visual acuity; and intraocular pressure measured using Goldmann applanation tonometry. Best-corrected visual acuity and intraocular pressure were also measured on day 1 after the surgery. In addition to the assigned study treatment, all patients instilled prednisolone acetate (Omnipred®, Alcon Laboratories Inc, Fort Worth, TX) four times per day, and bromfenac (Xibrom®, Ista Pharmaceuticals, Irvine, CA) two times per day for 4 weeks.

Outcome measures

The primary outcome measure of the study was the rate of occurrence of treatment-emergent adverse events in the 28-day period following surgery. Secondary endpoints included changes in corneal thickness and endothelial cell count as assessments of corneal integrity, overall corneal staining and central corneal staining as tolerability assessments, and intraocular pressure and best-corrected visual acuity as additional safety assessments.

Statistical analysis

Statistical analysis was performed using SAS software (v 9.1.3; SAS Institute Inc, Cary, NC). The statistical model tested the effect of treatment. The difference between the least squares mean of besifloxacin ophthalmic suspension

0.6% and least squares mean of moxifloxacin ophthalmic solution 0.5% was tested at a significance level of 5% and was considered significantly different if the observed *P* value was <0.05.

Results

Patient disposition and demographics

A total of 60 patients were enrolled at the two study sites. The demographics of patients in both the groups were comparable (Table 1). The mean (\pm standard deviation) age was 68.5 ± 11.1 years in the besifloxacin group and 69.0 ± 8.4 years in the moxifloxacin group. The groups were similar in distribution of the operated eye (OD/OS) and distribution of preoperative visual acuity. The majority of patients had medical and ocular histories consistent with those of the seventh decade of life. Two thirds of the patients in each group had a history of cardiovascular disorders, and approximately one third of eyes in each group had a history of glaucoma. Eight of the 11 diabetic patients were assigned to besifloxacin treatment. One patient in the besifloxacin treatment group withdrew consent prior to the final exit visit, and one patient in the moxifloxacin treatment group had a nonevaluable endothelial cell image at screening. Therefore, 58 patients (29 per treatment group) were included in the per protocol analysis. The mean baseline values for endothelial cell count, overall and central corneal staining, and intraocular pressure were similar between the treatment groups ($P \geq 0.1323$). The mean (\pm standard deviation) central corneal thickness was slightly greater in the moxifloxacin treatment group than in the besifloxacin treatment group at baseline ($569.6 \pm 33.9 \mu\text{m}$ versus $547.6 \pm 41.5 \mu\text{m}$, respectively; $P = 0.0312$). The most commonly implanted

intraocular lens in both groups was the SoftPort aspheric silicone lens (Bausch and Lomb Inc., Rochester, NY). A slightly higher number of eyes in the moxifloxacin group ($n = 10$) were implanted with the hydrophobic acrylic lenses as compared with the besifloxacin group ($n = 4$).

Primary endpoint

The primary outcome of the study was the rate of occurrence of adverse events. There were no adverse events observed in either the besifloxacin or the moxifloxacin treatment group. An adverse event was defined as any patient complaint such as burning, stinging, pain, and vision changes.

Secondary endpoints

Table 2 presents mean values for central corneal thickness, endothelial cell count, overall and central corneal staining, and intraocular pressure at baseline, day 7, and day 28, along with *P* values for differences in the least squares means between treatments in these outcomes. The potential for corneal edema and toxicity were assessed by measuring the central corneal thickness and endothelial cell count. As shown in Figure 1A, mean central corneal thickness in the besifloxacin and moxifloxacin treatment groups were comparable on day 7 and day 28 ($P \geq 0.1403$). Likewise, the change from baseline in

Table 1 Demographic characteristics and medical history

Parameter	Besifloxacin ophthalmic suspension (n = 30)	Moxifloxacin ophthalmic solution (n = 30)
Age, years		
Mean (SD)	68.5 (11.1)	69.0 (8.4)
Range	36–87	53–88
Gender, n (%)		
Male	7 (23%)	16 (53%)
Female	23 (77%)	14 (47%)
Race, n (%)		
Caucasian	30 (100%)	28 (93%)
Black	0	1 (3.3%)
Asian	0	1 (3.3%)
History of diabetes, n (%)	8 (27%)	3 (10%)
History of glaucoma or ocular hypertension, n (%)	8 (27%)	9 (30%)

Abbreviation: SD, standard deviation.

Table 2 Summary of secondary endpoints

Outcome	Mean (SD)		<i>P</i> value [†]
	Besifloxacin ophthalmic suspension (n = 29)	Moxifloxacin ophthalmic solution (n = 29)	
Central corneal thickness (μm)			
Baseline	547.6 (41.5)	569.6 (33.9)	0.0312
Day 7	568.0 (43.1)	581.3 (38.9)	0.2219
Day 28	564.8 (41.8)	580.0 (34.9)	0.1403
Overall corneal staining			
Baseline	0.655 (0.77)	0.621 (0.73)	0.8614
Day 7	1.38 (0.98)	1.07 (0.84)	0.2009
Day 28	1.17 (1.04)	0.86 (0.95)	0.2406
Central corneal staining			
Baseline	0.21 (0.41)	0.07 (0.26)	0.1323
Day 7	0.83 (1.14)	0.55 (0.78)	0.2863
Day 28	0.93 (1.13)	0.45 (0.83)	0.0690
Endothelial cell count (cells/mm ²)			
Baseline	2571.0 (381.3)	2561.0 (351.8)	0.9188
Day 7	2443.8 (397.9)	2460.5 (398.1)	0.8742
Day 28	2454.4 (473.5)	2398.0 (382.3)	0.6200
Intraocular pressure (mm Hg)			
Baseline	15.5 (2.4)	15.2 (1.9)	0.5443
Day 7	16.8 (2.6)	15.8 (2.3)	0.1452
Day 28	15.7 (2.1)	14.9 (2.6)	0.2043

Note: [†]*P* value for difference between treatments in least squares means.

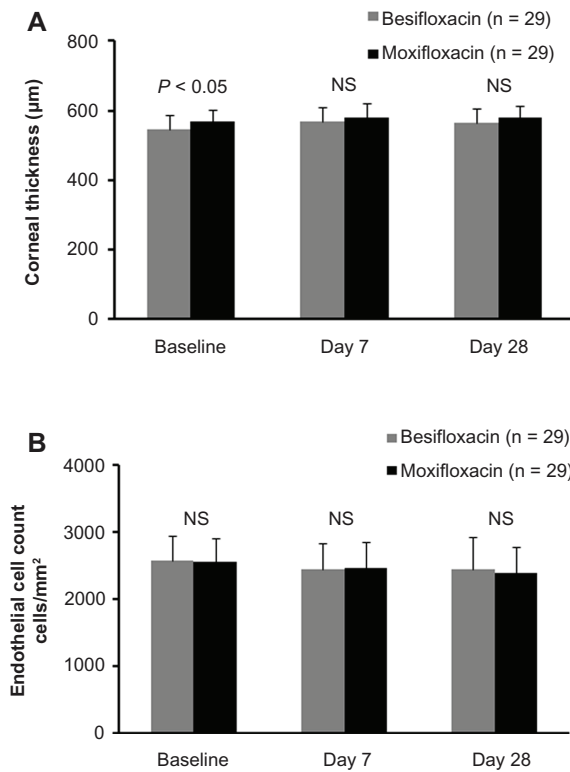


Figure 1 Mean (\pm standard deviation) central corneal thickness (**A**) and endothelial cell count (**B**) at baseline, day 7, and day 28.

Note: Light gray bars represent besifloxacin-treated patients and dark gray bars represent moxifloxacin-treated patients.

Abbreviation: NS, no significant difference between treatments.

corneal thickness was comparable between treatments at day 7 (20.5 ± 25.1 μm versus 11.8 ± 20.6 μm ; $P = 0.1549$) and day 28 (17.3 ± 24.6 μm versus 10.4 ± 20.7 μm ; $P = 0.2554$). Endothelial cell counts are presented in Figure 1B. The mean endothelial cell count in the besifloxacin and moxifloxacin treatment groups were similar at baseline, day 7, and day 28 ($P \geq 0.6200$), as was the change from baseline at day 7 (-127.3 ± 259.3 cells/ mm^2 versus -100.8 ± 237.3 cells/ mm^2 ; $P = 0.6865$) and day 28 (-116.7 ± 252.2 cells/ mm^2 versus -163.2 ± 230.0 cells/ mm^2 ; $P = 0.4664$).

The mean overall and central corneal staining, assessed as tolerability endpoints, increased in both treatment groups relative to baseline (Figure 2), but were similar between treatments at baseline and follow-up visits ($P \geq 0.0690$). The mean change from baseline in overall corneal staining was similar between treatments on day 7 (0.72 ± 1.07 versus 0.45 ± 1.12 ; $P = 0.3409$) and day 28 (0.52 ± 1.06 versus 0.24 ± 0.95 ; $P = 0.3004$), as was the mean change from baseline in central corneal staining at day 7 (0.62 ± 1.15 versus 0.48 ± 0.83 ; $P = 0.6017$) and day 28 (0.72 ± 1.03 versus 0.38 ± 0.82 ; $P = 0.1643$). Local tolerability was also assessed by recording the incidence of burning or stinging associated with the use of the study drugs. As indicated above, there were no subjective

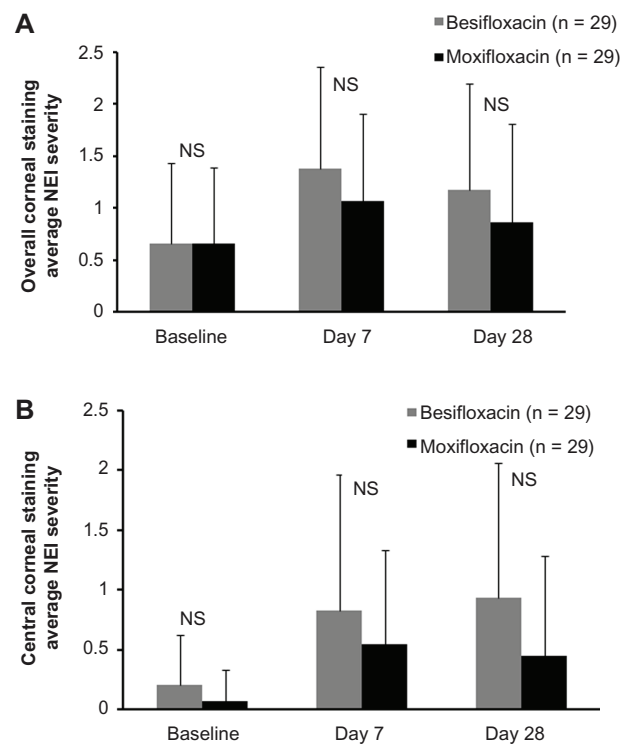


Figure 2 Mean (\pm standard deviation) overall corneal staining (**A**) and central corneal staining (**B**) for baseline, day 7, and day 28.

Note: Light gray bars represent besifloxacin-treated patients and dark gray bars represent moxifloxacin-treated patients.

Abbreviations: NS, no significant differences between treatments; NEI, National Eye Institute.

complaints reported by any patients in either the besifloxacin or moxifloxacin treatment groups throughout the study.

Additional safety endpoints included intraocular pressure and best-corrected visual acuity. Intraocular pressure was comparable between treatment groups at all follow-up visits (Figure 3). The intraocular pressure increased in both treatment groups immediately following surgery; the mean intraocular pressures at day 1 were 18.5 ± 3.7 mm Hg and

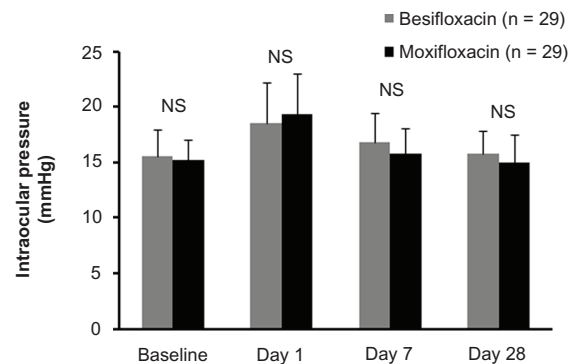


Figure 3 Mean (\pm standard deviation) intraocular pressure at baseline, day 1, day 7, and day 28.

Note: Light gray bars represent besifloxacin-treated patients, and dark gray bars represent moxifloxacin-treated patients.

Abbreviation: NS, no significant differences between treatments.

19.3 ± 3.6 mm Hg in the besifloxacin and moxifloxacin treatment groups, respectively, and two eyes in each treatment group experienced an intraocular pressure increase of ≥10 mm Hg above baseline. By day 7, the mean intraocular pressures returned to baseline values in both treatment groups and remained at baseline values at day 28. The difference between treatments in the change from baseline in intraocular pressure were similar at day 7 (1.3 ± 2.6 mm Hg versus 0.7 ± 2.6 mm Hg; $P = 0.3696$) and day 28 (0.2 ± 2.5 mm Hg versus -0.2 ± 2.6 mm Hg; $P = 0.5094$). As expected, visual acuity improved in all patients following cataract surgery (Figure 4). At the final visit, the distribution of best-corrected visual acuity was comparable between the two treatment groups (data not shown), and best-corrected visual acuity was 20/30 or better in 85% of the patients.

Discussion

The results of this prospective, parallel-group, investigator-masked study suggest that besifloxacin ophthalmic suspension 0.6%, a DuraSite-based formulation, is similar to moxifloxacin ophthalmic solution 0.5%, a non-DuraSite-based formulation, in terms of safety and tolerability when used prophylactically in patients undergoing routine, uncomplicated, sutureless cataract surgery. There were no adverse events reported in either the besifloxacin ophthalmic suspension or the moxifloxacin ophthalmic solution treatment groups during the 28-day period following surgery. The results for corneal thickness and endothelial cell count were comparable between the treatment groups at follow-up visits, demonstrating that neither drug compromised the corneal endothelium when used in the perioperative period of cataract surgery. The results for overall and central corneal

staining, in conjunction with a lack of reports of stinging and burning, indicated that the treatments have similar tolerability profiles. In addition, changes in intraocular pressure and best-corrected visual acuity were similar between treatment groups.

Besifloxacin is a broad-spectrum antibiotic that is not marketed in any form other than the topical ophthalmic preparation. This avoids any bacterial exposure resulting from systemic use of the drug and minimizes the overall selective pressure that can contribute to the emergence of resistant strains, potentially contributing to the potency of this drug against drug-resistant staphylococci, the pathogens most commonly associated with recent cases of endophthalmitis.^{15,17,32} In fact, in vitro studies have demonstrated that besifloxacin is more potent than gatifloxacin and moxifloxacin against multidrug resistant staphylococcal isolates,^{16,25,33,34} and similar in potency to vancomycin,^{16,35} a drug currently reserved for suspected methicillin-resistant *S. aureus* infections.^{36–38} The inclusion of DuraSite in the besifloxacin formulation increases the retention time of besifloxacin on the ocular surface, theoretically increasing ocular surface sterilizing efficiency, although studies are needed to confirm this.

A recent study raised a concern about the use of DuraSite-based antibiotic formulations in cataract surgery. An animal study showed that the DuraSite vehicle may block the trabecular meshwork and damage the corneal endothelium when introduced directly into the anterior chamber.³¹ Briefly, a 0.1 mL dose of various formulations, or the equivalent of three drops from a standard eye drop bottle, was injected into the anterior chamber of New Zealand rabbits through the anterior sclera and conjunctiva. After 48 hours, the rabbits were euthanized and their eyes were examined. Glaucomatous damage, presumably from the DuraSite vehicle blocking the trabecular meshwork, and corneal edema from endothelial cell morphological changes were observed in eyes injected with besifloxacin ophthalmic suspension 0.6% and those injected with azithromycin ophthalmic solution 0.1% (AzaSite®, Inspire Pharmaceuticals Inc, NC), also formulated with DuraSite. The study was characterized by the authors as simulating an extremely leaky wound, which would presumably allow topically used DuraSite-containing antibiotics to enter the anterior chamber. The researchers concluded that DuraSite was responsible for the results observed. As a safety precaution, they also recommended suturing of the incision following cataract surgery if DuraSite-based drug formulations were used for postoperative endophthalmitis prophylaxis. However, the clinical relevance of these rabbit studies is not known. In a follow-up

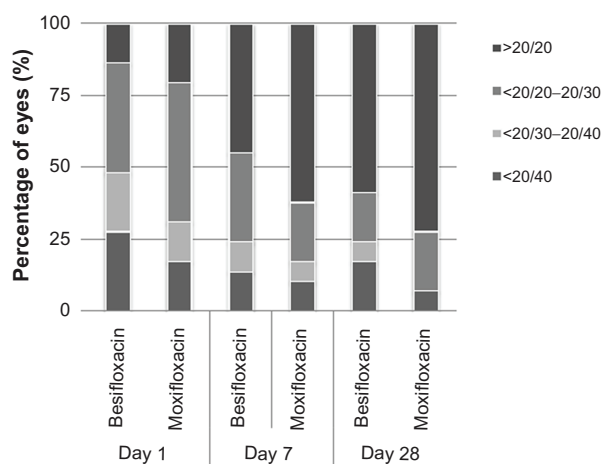


Figure 4 Distribution of best-corrected visual acuity at day 1, day 7, and day 28 in besifloxacin-treated patients and moxifloxacin-treated patients.

study, Goecks et al injected smaller volumes (12.5 μ L, 25 μ L, and 50 μ L) of azithromycin with or without DuraSite directly into the anterior chamber of rabbit eyes or applied several drops of these formulations directly to a 2.8 mm limbal incision followed by repeated opening of the wound with forceps.³⁹ Slit lamp examination and histopathology showed toxicity with the DuraSite-containing formulation relative to the exposure volume. We propose that it is unlikely that a topically administered drug would penetrate into aqueous humor at volumes approaching even the smallest volume tested in these studies through the leakiest of clear corneal incisions. Furthermore, the mucoadhesive polycarophil used in DuraSite has a very high molecular weight (in billions). Therefore, there is little possibility of the polymer gaining entry into the anterior chamber in the presence of a clear corneal incision created for cataract surgery.⁴⁰ Furthermore, a surgical wound that is severely compromised is more likely to be associated with vision-threatening complications (eg, infection, endophthalmitis, hypotony, choroidal effusion) than any possible toxicity from the drug vehicle.

In our study, the safety of besifloxacin ophthalmic suspension 0.6%, and by extension, the safety of the DuraSite vehicle, in uncomplicated post-cataract surgery was demonstrated by the fact that no adverse events were reported, and there was no evidence of compromised corneal endothelium (by cell counts and pachymetry) or unusual elevations in intraocular pressure, despite the use of sutureless clear corneal incisions. Outcomes were remarkably similar to those observed with moxifloxacin ophthalmic solution 0.5%, a non-DuraSite formulation. These results are also consistent with a previous preclinical study by Krenzer et al who examined the effects of topical administration of the DuraSite vehicle using two dosing schedules on surgically compromised rabbit eyes, including those with laser-assisted in situ keratomileusis (LASIK) flaps or a 3 mm clear corneal incision.⁴⁰ In the first dosing schedule, one drop of DuraSite (50 μ L) was instilled immediately after surgery, with the second dose instilled later in the day, followed by four times daily for 14 days. The second schedule involved instilling one drop of DuraSite four times daily on the day prior to surgery and 0.25 hours prior to surgery, and at hours 0.125, 4, and 8 postoperatively, followed by four times daily for 9 days. No adverse effects were observed in both the LASIK flap and corneal incision models with either dosing schedule. The wound and anterior chamber of the eye in the corneal incision model did not show the presence of the polymer at any time, and the corneal endothelium appeared normal as in the controls. The LASIK flap also did not show any presence of the DuraSite at the interface.

Histopathology examination did not indicate any unique safety concerns associated with the use of the DuraSite vehicle in these settings.⁴⁰ Taken together, these studies suggest that in routine, uncomplicated postoperative conditions, the use of Besivance for postoperative antibacterial prophylaxis does not appear to present safety concerns.

A slight increase from baseline in overall and central corneal staining was observed at day 7 and day 28 in both treatment groups in this study, but the change from baseline in overall and central corneal staining was similar between treatments. Increases in corneal staining are not unexpected following cataract surgery and may result from a combination of factors including the trauma of the surgical procedure itself, mechanical effects of the use of irrigating solutions, desiccation of the cornea, or any of the topical medications used perioperatively (steroids, nonsteroidal anti-inflammatory drugs, or antibiotics). Regardless of the cause, the lack of a difference in the change from baseline in corneal staining between treatments suggests that neither the DuraSite vehicle nor the benzalkonium chloride preservative used in besifloxacin ophthalmic suspension 0.6% had an adverse effect on the corneal epithelium. These results are consistent with those of a pooled safety analysis of besifloxacin ophthalmic suspension in the treatment of bacterial conjunctivitis that reported punctate keratitis at an incidence of 0.3%, which was considered insignificant as compared with an incidence of 0.5% for the preservative-free moxifloxacin ophthalmic solution.²¹

A limitation of our study was the single-masked design. While investigators were masked to treatment, patients were not. The lack of subjective adverse event reports in either of the treatment groups suggests that patients were not biased. The relatively small number of patients enrolled and the lack of a priori power calculations to define an appropriate sample size for rejection of a prestated null hypothesis for the primary and secondary outcomes was also a limitation. While large differences between treatments at follow-up visits would likely have been detected, small differences between treatments may not have been detectable. Despite these limitations, the results of our study suggest that besifloxacin 0.6% is safe when used as a prophylactic antibiotic to minimize the possibility of postoperative infections in patients undergoing uncomplicated sutureless cataract extraction surgery.

Conclusion

In this study, besifloxacin ophthalmic suspension 0.6% was safe and well tolerated when used as a prophylactic antibiotic during routine, uncomplicated, sutureless cataract surgery. The safety and tolerability profile of besifloxacin ophthalmic

suspension 0.6% was similar to that of moxifloxacin ophthalmic solution 0.5%, although larger studies are needed to confirm these findings.

Disclosure

This study was supported by a grant from Bausch and Lomb Inc. RM is a paid speaker for Bausch and Lomb Inc. JG is a paid speaker for Bausch and Lomb Inc. The other authors do not have any conflict of interest to declare. Writing support for this manuscript was provided by Cactus Communications and was funded by Bausch and Lomb Inc. The authors retained full control of the manuscript content.

References

- Congdon N, Vingerling JR, Klein BE, et al. Prevalence of cataract and pseudophakia/aphakia among adults in the United States. *Arch Ophthalmol*. 2004;122(4):487–494.
- Facts about cataract. Available from: http://www.nei.nih.gov/health/ataract/ataract_facts.asp. Accessed September 21, 2011.
- Kelkar A, Kelkar J, Amuaku W, Kelkar U, Shaikh A. How to prevent endophthalmitis in cataract surgeries? *Indian J Ophthalmol*. 2008;56(5):403–407.
- Minassian DC, Rosen P, Dart JK, et al. Extracapsular cataract extraction compared with small incision surgery by phacoemulsification: a randomised trial. *Br J Ophthalmol*. 2001;85(7):822–829.
- Aaberg TM Jr, Flynn HW Jr, Schiffman J, Newton J. Nosocomial acute-onset postoperative endophthalmitis survey. A 10-year review of incidence and outcomes. *Ophthalmology*. 1998;105(6):1004–1010.
- Jacobs DJ, Leng T, Flynn HW Jr, Shi W, Miller D, Gedde SJ. Delayed-onset bleb-associated endophthalmitis: presentation and outcome by culture result. *Clin Ophthalmol*. 2011;5:739–744.
- Novosad BD, Callegan MC. Severe bacterial endophthalmitis: towards improving clinical outcomes. *Expert Rev Ophthalmol*. 2010;5(5):689–698.
- Speaker MG, Milch FA, Shah MK, Eisner W, Kreiswirth BN. Role of external bacterial flora in the pathogenesis of acute postoperative endophthalmitis. *Ophthalmology*. 1991;98(5):639–649.
- Bannerman TL, Rhoden DL, McAllister SK, Miller JM, Wilson LA. The source of coagulase-negative staphylococci in the Endophthalmitis Vitrectomy Study. A comparison of eyelid and intraocular isolates using pulsed-field gel electrophoresis. *Arch Ophthalmol*. 1997;115(3):357–361.
- Nagaki Y, Hayasaka S, Kadoi C, et al. Bacterial endophthalmitis after small-incision cataract surgery. Effect of incision placement and intraocular lens type. *J Cataract Refract Surg*. 2003;29(1):20–26.
- Masket M, Chang DF, Lane DF, et al. Cataract in the adult eye: preferred practice pattern. San Francisco, CA: American Academy of Ophthalmology. 2006. Available from: http://one.aaao.org/CE/PracticeGuidelines/PPP_Content.aspx?cid=a80a87ce-9042-4677-85d7-4b876deed276. Accessed February 27, 2012.
- Barry P, Seal DV, Gettinby G, Lees F, Peterson M, Revie CW. ESCRS study of prophylaxis of postoperative endophthalmitis after cataract surgery: preliminary report of principal results from a European multicenter study. *J Cataract Refract Surg*. 2006;32(3):407–410.
- Jensen MK, Fiscella RG, Moshirfar M, Mooney B. Third- and fourth-generation fluoroquinolones: retrospective comparison of endophthalmitis after cataract surgery performed over 10 years. *J Cataract Refract Surg*. 2008;34(9):1460–1467.
- Chang DF, Braga-Mele R, Mamalis N, et al. Prophylaxis of postoperative endophthalmitis after cataract surgery: results of the 2007 ASCRS member survey. *J Cataract Refract Surg*. 2007;33(10):1801–1805.
- Olson R, Donnenfeld E, Bucci FA Jr, et al. Methicillin resistance of *Staphylococcus* species among health care and nonhealth care workers undergoing cataract surgery. *Clin Ophthalmol*. 2010;4:1505–1514.
- Haas W, Pillar CM, Torres M, Morris TW, Sahn DF. Monitoring antibiotic resistance in ocular microorganisms: results from the Antibiotic Resistance Monitoring in Ocular microorganisms (ARMOR) 2009 surveillance study. *Am J Ophthalmol*. 2011;152(4):567–574, e563.
- Deramo VA, Lai JC, Fastenberg DM, Udell IJ. Acute endophthalmitis in eyes treated prophylactically with gatifloxacin and moxifloxacin. *Am J Ophthalmol*. 2006;142(5):721–725.
- Karpecki P, Depaolis M, Hunter JA, et al. Besifloxacin ophthalmic suspension 0.6% in patients with bacterial conjunctivitis: a multicenter, prospective, randomized, double-masked, vehicle-controlled, 5-day efficacy and safety study. *Clin Ther*. 2009;31(3):514–526.
- Tepedino ME, Heller WH, Usner DW, et al. Phase III efficacy and safety study of besifloxacin ophthalmic suspension 0.6% in the treatment of bacterial conjunctivitis. *Curr Med Res Opin*. 2009;25(5):1159–1169.
- McDonald MB, Protzko EE, Brunner LS, et al. Efficacy and safety of besifloxacin ophthalmic suspension 0.6% compared with moxifloxacin ophthalmic solution 0.5% for treating bacterial conjunctivitis. *Ophthalmology*. 2009;116(9):1615–1623, e1611.
- Comstock TL, Paterno MR, Decory HH, Usner DW. Safety and tolerability of besifloxacin ophthalmic suspension 0.6% in the treatment of bacterial conjunctivitis: data from six clinical and phase I safety studies. *Clin Drug Investig*. 2010;30(10):675–685.
- Silverstein BE, Allaire C, Bateman KM, Gearinger LS, Morris TW, Comstock TL. Efficacy and tolerability of besifloxacin ophthalmic suspension 0.6% administered twice daily for 3 days in the treatment of bacterial conjunctivitis: a multicenter, randomized, double-masked, vehicle-controlled, parallel-group study in adults and children. *Clin Ther*. 2011;33(1):13–26.
- Cambau E, Matrat S, Pan XS, et al. Target specificity of the new fluoroquinolone besifloxacin in *Streptococcus pneumoniae*, *Staphylococcus aureus* and *Escherichia coli*. *J Antimicrob Chemother*. 2009;63(3):443–450.
- Besivance® package insert. Rochester, NY: Bausch and Lomb Inc; 2009.
- Haas W, Pillar CM, Zurenko GE, Lee JC, Brunner LS, Morris TW. Besifloxacin, a novel fluoroquinolone, has broad-spectrum in vitro activity against aerobic and anaerobic bacteria. *Antimicrob Agents Chemother*. 2009;53(8):3552–3560.
- Final report on the safety assessment of Carbomers-934, -910, -934P, -940, -941, and -962. *Int J Toxicol*. 1982;1(2):109–141.
- See NA, Russell J, Connors KA, Bass P. Adsorption of inorganic and organic ions to polycarbophil as a means of sustained-release dosage formulation. *Pharm Res*. 1987;4(3):244–247.
- Lehr CM, Lee YH, Lee VH. Improved ocular penetration of gentamicin by mucoadhesive polymer polycarbophil in the pigmented rabbit. *Invest Ophthalmol Vis Sci*. 1994;35(6):2809–2814.
- Bowman LM, Si E, Pang J, Archibald R, Friedlaender M. Development of a topical polymeric mucoadhesive ocular delivery system for azithromycin. *J Ocul Pharmacol Ther*. 2009;25(2):133–139.
- Abelson M, Protzko E, Shapiro A, Garces-Soldana A, Bowman L. A randomized trial assessing the clinical efficacy and microbial eradication of 1% azithromycin ophthalmic solution vs tobramycin in adult and pediatric subjects with bacterial conjunctivitis. *Clin Ophthalmol*. 2007;1(2):177–182.
- Ness PJ, Mamalis N, Werner L, et al. An anterior chamber toxicity study evaluating Besivance, AzaSite, and Ciprofloxacin. *Am J Ophthalmol*. 2010;150(4):498–504, e491.
- Miller D, Flynn PM, Scott IU, Alfonso EC, Flynn HW Jr. In vitro fluoroquinolone resistance in staphylococcal endophthalmitis isolates. *Arch Ophthalmol*. 2006;124(4):479–483.

33. Haas W, Pillar CM, Hesje CK, Sanfilippo CM, Morris TW. Bactericidal activity of besifloxacin against staphylococci, *Streptococcus pneumoniae* and *Haemophilus influenzae*. *J Antimicrob Chemother*. 2010;65(7):1441–1447.
34. Haas W, Gearing LS, Usner DW, Decory HH, Morris TW. Integrated analysis of three bacterial conjunctivitis trials of besifloxacin ophthalmic suspension, 0.6%: etiology of bacterial conjunctivitis and antibacterial susceptibility profile. *Clin Ophthalmol*. 2011;5:1369–1379.
35. Haas W, Pillar CM, Morris TW, Sahm DM. Antibiotic resistance trends in ocular pathogens – An update from the ARMOR 2009 and ARMOR 2010 surveillance studies. Paper presented at the Association for Research in Vision and Ophthalmology annual meeting, May 1–5, 2011, Ft Lauderdale, FL.
36. Adebayo A, Parikh JG, McCormick SA, et al. Shifting trends in in vitro antibiotic susceptibilities for common bacterial conjunctival isolates in the last decade at the New York Eye and Ear Infirmary. *Graefes Arch Clin Exp Ophthalmol*. 2011;249(1):111–119.
37. Freidlin J, Acharya N, Lietman TM, Cevallos V, Whitcher JP, Margolis TP. Spectrum of eye disease caused by methicillin-resistant *Staphylococcus aureus*. *Am J Ophthalmol*. 2007;144(2):313–315.
38. Blomquist PH. Methicillin-resistant *Staphylococcus aureus* infections of the eye and orbit (an American Ophthalmological Society thesis). *Trans Am Ophthalmol Soc*. 2006;104:322–345.
39. Goecks T, Werner L, Mamalis N, et al. Toxicity comparison of intraocular azithromycin with and without a bioadhesive delivery system in rabbit eyes. *J Cataract Refract Surg*. 2012;38:137–145
40. Krezner KL, Zhang JZ, Coffey MJ. Safety of repeated topical ocular administration of a polycarbophil-based formulation (DuraSite®) in several models of ocular surgery in rabbits. *J Cataract Refract Surg*. 2012;38(4):696–704.

Clinical Ophthalmology

Publish your work in this journal

Clinical Ophthalmology is an international, peer-reviewed journal covering all subspecialties within ophthalmology. Key topics include: Optometry; Visual science; Pharmacology and drug therapy in eye diseases; Basic Sciences; Primary and Secondary eye care; Patient Safety and Quality of Care Improvements. This journal is indexed on

Submit your manuscript here: <http://www.dovepress.com/clinical-ophthalmology-journal>

Dovepress

PubMed Central and CAS, and is the official journal of The Society of Clinical Ophthalmology (SCO). The manuscript management system is completely online and includes a very quick and fair peer-review system, which is all easy to use. Visit <http://www.dovepress.com/testimonials.php> to read real quotes from published authors.