



COVID-19 associated intracranial vasculopathy–MRI vessel wall imaging as adjunct to emergent CT angiography—a case report

David Raban¹ · Krystle Barhaghi¹ · Vincent Timpone¹ · William Jones² · Brian Sauer² · Rebecca Pollard² · Andrew Callen¹

Received: 21 April 2021 / Accepted: 18 May 2021 / Published online: 26 May 2021
© American Society of Emergency Radiology 2021

Abstract

COVID-19 was initially described as a pulmonary disease. Increasing attention is now directed to extrapulmonary disease manifestations mediated by viral tropism to the vascular endothelium. Here, we report a case of an adult patient with COVID-19 who presented to the emergency department with neurological signs disproportionate to pulmonary symptoms and was found to have a subacute ischemic stroke. Imaging studies suggested an active inflammatory vasculopathy. The case highlights the utility of vascular wall imaging studies when positive findings are present on emergent CT angiography. Current treatment algorithms should consider the addition of adjunct intracranial vessel wall imaging to assess for inflammatory vasculopathy when a patient with acute or recent COVID infection presents to the emergency department with stroke.

Keywords COVID-19 · Stroke · CT angiography · MRI vessel wall imaging

Background

Coronavirus disease 2019 (COVID-19), caused by severe acute respiratory syndrome coronavirus 2 (SARS-CoV-2), is a multisystem disease associated with multiple neurologic illnesses [1]. Viral pathology is thought to be mediated through angiotensin converting enzyme receptors in the endothelium, which are expressed throughout the systemic and neurologic vasculature [2]. Reported cerebrovascular complications include stroke precipitated through hypercoagulability, small vessel disease, and large vessel disease mechanisms [3, 4]. Recent studies have demonstrated abnormal findings on MRI vessel wall imaging (VWI) in hospitalized COVID-19 patients [3, 5]. In addition, there is evidence that VWI complements conventional luminal imaging by increasing the reader's sensitivity for the detection of abnormalities, as well as augment the characterization these abnormalities [6]. Here, we report a case of intracranial

inflammatory vasculopathy well demonstrated by vessel wall imaging (VWI), coincident with middle cerebral artery stroke, in a patient with COVID-19 and minimal pulmonary symptoms.

Case presentation

A 51-year-old woman with a history of diabetes mellitus and hypertension presented to the emergency department with a 1-day history of altered mentation and gait instability. The patient endorsed a sore throat and mild cough beginning 8 days prior to her presentation.

A mild encephalopathy, moderate right-sided hemiparesis and mild, diffuse rhonchi were noted on physical examination.

Initial laboratory testing revealed uncontrolled diabetes mellitus (hemoglobin A1c 12.5%; normal <6.0) and diabetic ketoacidosis (elevated beta-hydroxybutyrate 4.16 mmol/L; normal <0.27). SARS-CoV-2 RNA was detected by respiratory viral panel PCR testing. Chest radiography demonstrated bilateral peripheral airspace opacities (Fig. 1). The d-dimer and c-reactive protein were elevated at 1130 ng/ml FEU (normal <500) and 85 mg/L (normal <10.0), respectively. The patient was admitted for management of diabetic ketoacidosis and SARS-CoV-2 pneumonia.

✉ Andrew Callen
andrew.callen@cuanschutz.edu

¹ Neuroradiology Section, Department of Radiology, University of Colorado Anschutz Medical Campus, Leprino Building, 12401 East 17th Avenue, Aurora, CO 80045, USA

² Department of Neurology, University of Colorado Anschutz Medical Campus, Aurora, CO, USA

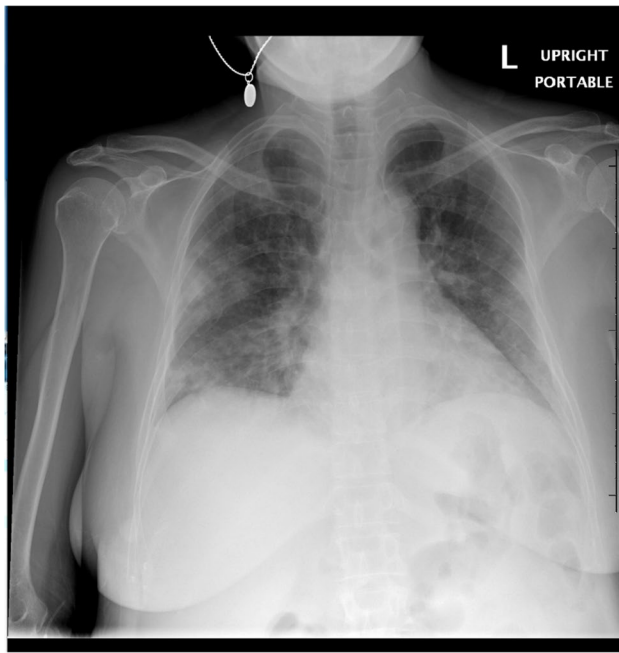


Fig. 1 Chest radiography demonstrating bilateral peripheral predominant airspace opacities consistent with SARS-CoV-2 infection

CT head imaging demonstrated hypodensities within the subcortical white matter compatible with microvascular disease. MRI brain revealed subacute infarctions within the left middle cerebral artery (MCA) vascular distribution (Fig. 2).

Long segment luminal narrowing of the M1 and M2 segments of the left MCA, disproportionate to the degree of intra- and extracranial atherosclerotic disease, was noted on CTA head and neck imaging, which prompted a concern for a vasculitic or vasculopathic process. Pre- and post-contrast MR intracranial vessel wall imaging (VWI) was performed using a 3D high resolution variable flip angle black blood post-contrast sequence (CUBE) on a GE 3 T Discovery scanner which demonstrated long segment concentric enhancement of the left MCA (Fig. 3). The appearance favors a vasculitis, such as COVID endotheliitis, with long segment inflammatory plaque not excluded.

Cerebrospinal fluid studies were notable for zero nucleated cells, normal glucose (55 mg/dL; normal < 70), normal protein (30 mg/dL; normal < 45), normal IgG index (1090 mg/dL; normal < 1632), and zero unique oligoclonal bands. SARS-CoV-2 RNA was not detected within the cerebrospinal fluid specimen.

Alternative etiologies of immune-mediated and infectious vasculitis were evaluated. P- and c-ANCA, C3 and C4 complement level, rheumatoid factor, lupus anticoagulant, anti-nuclear antibody screening, SSA and SSB antibody, HIV antigen and antibody, hepatitis C antibody,

and cryoglobulin serology studies were without pathological findings. Cerebrospinal fluid herpes simplex virus PCR, varicella zoster (VZV) PCR, and VZV IgM and IgG antibody studies were likewise unrevealing. No other respiratory viruses were detected by viral respiratory panel PCR testing.

The patient's hospitalization totaled 6 days. The presenting encephalopathy resolved with insulin-mediated diabetic ketoacidosis treatment and secondary lactic acidosis correction. Aspirin, statin, and antihypertensive therapies were prescribed for pharmacologic secondary stroke prophylaxis. Supplemental oxygen therapy was not required. Dexamethasone, remdesivir, and convalescent plasma were not prescribed, as the patient did not meet algorithm-established criteria for these therapies.

Discussion

COVID-19 is predominantly described as a respiratory illness with rare extrapulmonary manifestations. However, as the vascular tropism of SARS-CoV-2 is further recognized, systemic extrapulmonary complications are increasingly acknowledged as a common finding in this illness, rather than a rare exception.

Stroke mediated through large- and small-vessel inflammatory vasculopathies are reported neurovascular complications of COVID-19 [3, 4]. The putative mechanism of COVID-19-associated vasculitis is SARS-CoV-2 endothelial cell tropism leading to either primary virus- or secondary immune-mediated endothelial dysfunction, as opposed to direct central nervous system infection and dissemination [7]. In keeping with prior reports underpinning this purported mechanism, SARS-CoV-2 RNA was detected in the serum, but not the cerebrospinal fluid of the patient whose case is reported here within [8]. Additional work, including the interrogation of cerebral vaso-reactivity in patients at various stages of SARS-CoV-2 infection, is required in order to understand the temporality of SARS-CoV-2-mediated endothelial dysfunction and the corresponding chronicity of cerebrovascular disease risk [9].

This understanding is essential for shaping and redefining COVID-19 treatment algorithms, particularly in the emergent setting. Current treatment algorithms disproportionately center upon acute pulmonary disease manifestations while offering limited guidance in the diagnostic interrogation and treatment of extrapulmonary disease complications, including neurovascular complications [10]. The presented case exemplifies the utility of vessel wall imaging as adjunct to the emergent use of CT angiography (luminal imaging) in the setting of acute COVID-19 infection, an etiology known to elicit vascular inflammation.

Fig. 2 Top left: MR DWI demonstrating infarctions, involving the left corona radiata and external capsule. Top right: T2 weighted imaging revealing asymmetric, right greater than left, middle cerebral artery flow voids. Bottom row: MRA depicting a paucity of flow related signal in the left MCA horizontal and insular segments as compared to corresponding, contralateral right MCA segments

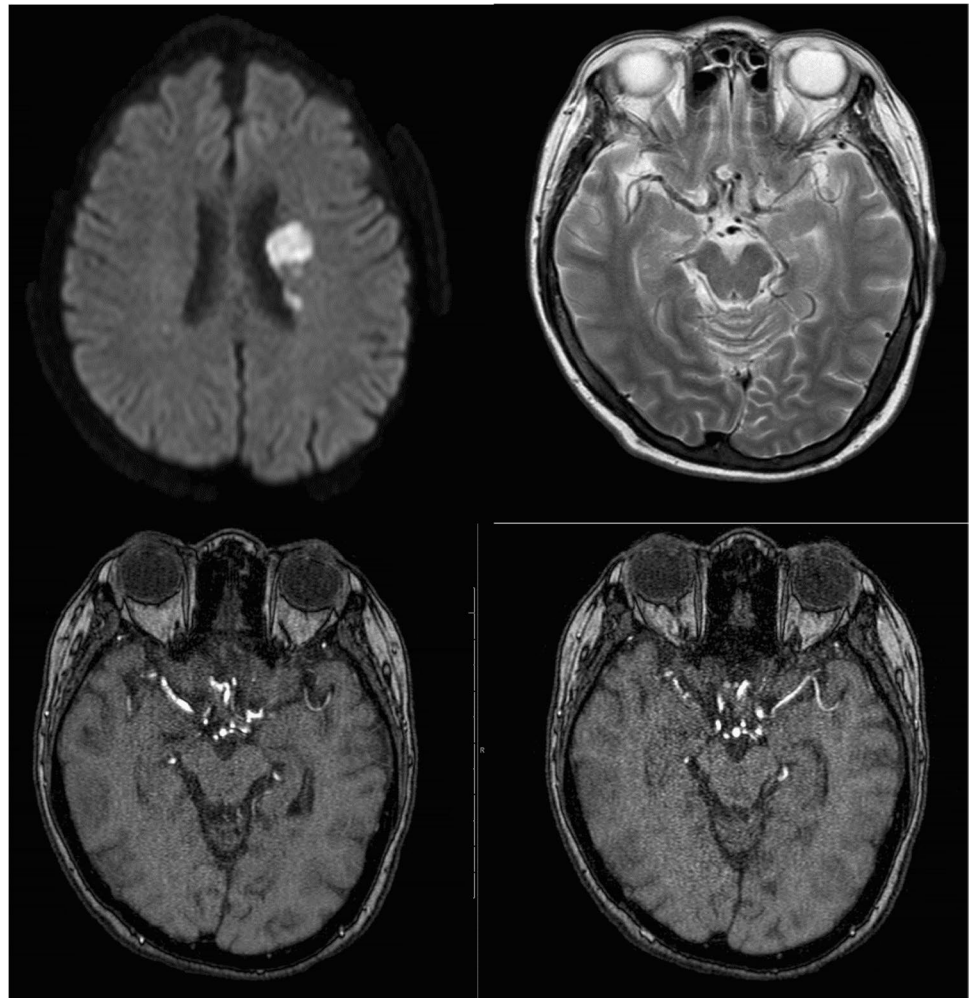
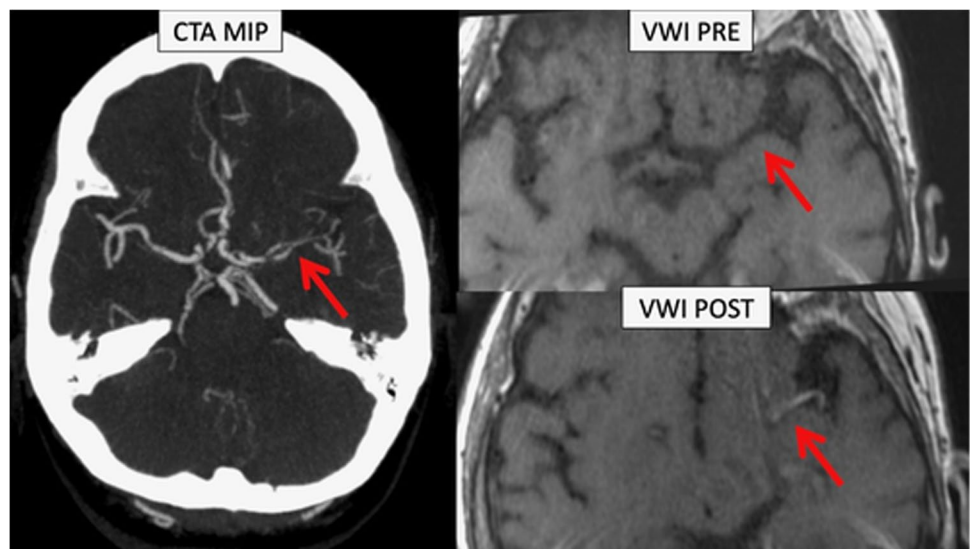


Fig. 3 Left: CTA maximum intensity projection (MIP) image, annotated, demonstrating stenosis of early left MCA branching insular segments. Right: Annotated pre- (top) and post- (bottom) contrast MR vessel wall imaging demonstrating long segment concentric enhancement of the vessel wall compatible with vasculitis



Conclusion

We report a case of a patient with COVID-19 presenting with mild pulmonary symptoms who was found to have an ischemic stroke with imaging findings suggestive of an intracranial inflammatory vasculopathy. Reassessment of the algorithmic evaluation of inflammatory vasculopathies such as COVID-19 is recommended, as these entities may benefit from adjunct vessel wall imaging studies.

Declarations

Conflict of interest The authors declare that they have no conflict of interest.

Disclaimer All authors certify that they have no affiliations with or involvement in any organization or entity with any financial interest or non-financial interest in the subject matter or materials discussed in this manuscript. The authors have no financial or proprietary interests in any material discussed in this article.

References

1. Mao L et al (2020) Neurologic manifestations of hospitalized patients with coronavirus disease 2019 in Wuhan, China. *JAMA Neurol* 77:683–690
2. Helms J et al (2020) Neurologic features in severe SARS-CoV-2 infection. *N Engl J Med* 382:2268–2270
3. Chan NC, Weitz JI (2020) COVID-19 coagulopathy, thrombosis, and bleeding. *Blood* 136:381–383
4. Emanuela K et al (2020) Large and small cerebral vessel involvement in severe COVID-19. *Stroke* 51:3719–3722
5. Hanafi R et al (2020) COVID-19 Neurologic complication with CNS vasculitis-like pattern. *AJNR Am J Neuroradiol* 41:1384–1387
6. Uginet M et al (2021) Cerebrovascular complications and vessel wall imaging in COVID-19 encephalopathy—a pilot study. *Clin Neuroradiol* 26:1–7
7. Song J et al (2019) Vessel wall MRI added to MR angiography in the evaluation of suspected vasculopathies. *J Neuroimaging* 29:454–457
8. Varga Z et al (2020) Endothelial cell infection and endotheliitis in COVID-19. *Lancet* 395:1417–1418
9. Gulko E et al (2020) Vessel wall enhancement and focal cerebral arteriopathy in a pediatric patient with acute infarct and COVID-19 infection. *AJNR Am J Neuroradiol*. <https://doi.org/10.3174/ajnr.A6778>
10. Alice King, Joaquin Serena, Bornstein Natan M, Markus Hugh S (2011) Does impaired cerebrovascular reactivity predict stroke risk in asymptomatic carotid stenosis? *Stroke* 42:1550–1555
11. Bhimraj A et al (2020) Infectious Diseases Society of America guidelines on the treatment and management of patients with COVID-19. *Clin Infect Dis*. <https://doi.org/10.1093/cid/ciaa478>

Publisher's note Springer Nature remains neutral with regard to jurisdictional claims in published maps and institutional affiliations.