

Minimally Invasive Trans-Mitral Septal Myectomy to Treat Hypertrophic Obstructive Cardiomyopathy

Hong Rae Kim, M.D., Jae Suk Yoo, M.D., Jae Won Lee, M.D.

A 43-year-old man with symptomatic hypertrophic obstructive cardiomyopathy (HOCM) was admitted to our hospital with aggravated exertional dyspnea and successfully treated with robotic transmitral septal myectomy. Minimally invasive transmitral septal myectomy may be a feasible surgical option for the treatment of HOCM in selected cases as an alternative to transaortic myectomy.

Key words: 1. Minimally invasive surgery
2. Hypertrophic obstructive cardiomyopathy
3. Septal myectomy

CASE REPORT

A 43-year-old man with a history of hypertrophic obstructive cardiomyopathy (HOCM) was admitted to our hospital due to recently aggravated exertional dyspnea and palpitations. Transthoracic echocardiography revealed asymmetrical inter-ventricular septal hypertrophy with systolic anterior motion (SAM) of the anterior mitral valve leaflet (Fig. 1A). The septal wall thickness was 25 mm, the left ventricular outflow tract flow velocity was 4.6 m/sec, and the pressure gradient was >90 mmHg. The end-diastolic and end-systolic volumes of the left ventricle were 71 mL and 25 mL, respectively. An elongated anterior leaflet of the mitral valve showed SAM, resulting in grade III eccentric mitral regurgitation toward the left atrial posterior wall. Computed tomography confirmed diffuse asymmetrical septal hypertrophy. On surface 12-lead electrocardiography, a sinus rhythm with left ventricular hypertrophy was confirmed, indicating a repolarization abnormality.

Right thoracotomy was performed with a 4.5-cm incision

in the fourth intercostal space, and four additional ports were inserted at the third (left arm, Chitwood clamp), fourth (left atrial retractor), and sixth (right arm) intercostal spaces. The Da Vinci Surgical System (Intuitive Inc., Sunnydale, CA, USA) was docked to those ports. Cardiopulmonary bypass was established through cannulation of the femoral artery and vein. After left atriotomy through the interatrial groove, the mitral valve leaflets were inspected. The anterior mitral valve leaflet (AMVL) was redundant with mild prolapse. A 3-cm radial incision was made in the AMVL from the right fibrous trigone to the left fibrous trigone, taking care to prevent aortic valve injury. Through the incised AMVL, the submitral apparatuses were inspected using a 0° thoracoscope. Asymmetric septal hypertrophy was present, but neither papillary muscle anomaly nor fusion was noted. Septal myectomy was then performed diffusely at the nadir of the right aortic sinus and cautiously continued leftward to prevent a conduction injury (Fig. 2). The total weight of the excised muscle was 11 g. The AMVL incision was repaired using a continuous running

Department of Thoracic and Cardiovascular Surgery, Asan Medical Center, University of Ulsan College of Medicine

Received: November 7, 2014, Revised: January 23, 2015, Accepted: February 6, 2015, Published online: December 5, 2015

Corresponding author: Jae Won Lee, Department of Thoracic and Cardiovascular Surgery, University of Ulsan College of Medicine, 88 Olympic-ro 43-gil, Songpa-gu, Seoul 05505, Korea
(Tel) 82-2-3010-3584 (Fax) 82-2-3010-6966 (E-mail) jwlee@amc.seoul.kr

© The Korean Society for Thoracic and Cardiovascular Surgery. 2015. All right reserved.

© This is an open access article distributed under the terms of the Creative Commons Attribution Non-Commercial License (<http://creativecommons.org/licenses/by-nc/4.0>) which permits unrestricted non-commercial use, distribution, and reproduction in any medium, provided the original work is properly cited.

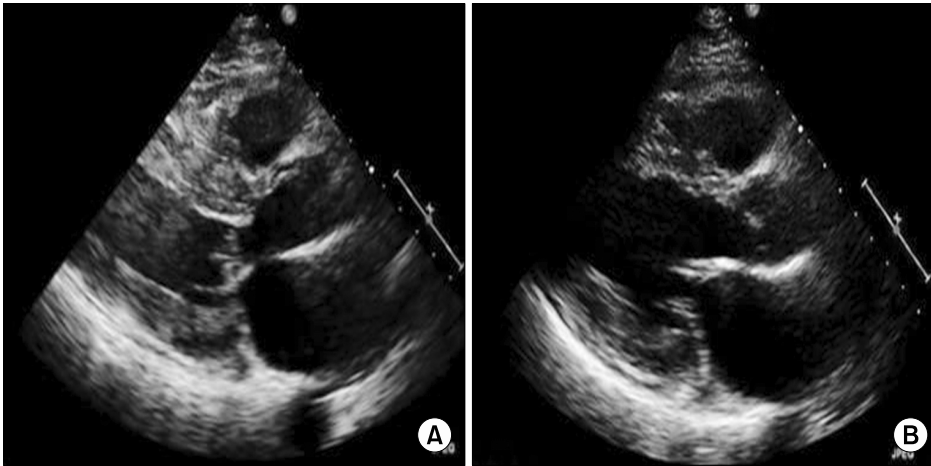


Fig. 1. (A) Parasternal long axis view of the patient described in this study, showing left ventricular outflow tract obstruction with systolic anterior motion. (B) Relieved left ventricular outflow tract obstruction with a resected interventricular septum after myectomy.

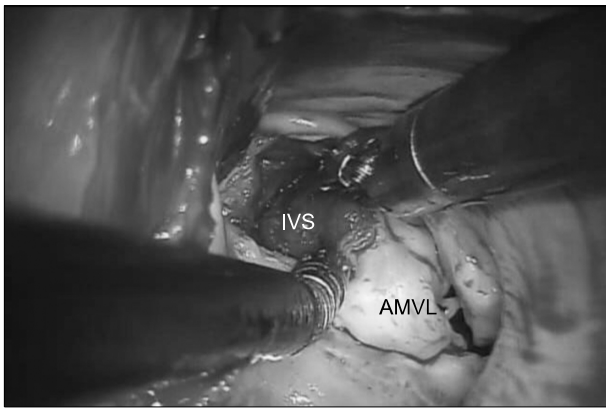


Fig. 2. Intraoperative view showing resection of the IVS using the Da Vinci system through an AMVL incision. IVS, interventricular septum; AMVL, anterior mitral valve leaflet.

suture. The suture line was initiated on the left side to avoid aortic valve injury. An ink test using methylene blue showed an adequate coaptation surface, and a water test revealed no residual mitral regurgitation.

In order to prevent possible micro-air embolism in the left chamber, the left atrium was filled with blood before closure of the transatrial incision. After weaning from cardiopulmonary bypass, a pair of epicardial pacing wires was inserted on the right ventricle. Intraoperative transesophageal echocardiography performed immediately after weaning from cardiopulmonary bypass revealed mild mitral regurgitation (grade I) with a well-relieved left ventricular outflow tract obstruction (pressure gradient, 15 mmHg) without SAM, as confirmed by the cardiologist on our team.

The patient remained in the intensive care unit for 18 hours, and no postoperative complications occurred. Postoperative transthoracic echocardiogram findings before discharge showed no left ventricular outflow tract obstruction (V_{max} , 1.9 m/sec) and only mild mitral regurgitation. A 12-lead electrocardiogram showed a normal sinus rhythm with a left bundle branch block. The septal thickness was 11 mm. On postoperative day 5, the patient was discharged in good general condition.

DISCUSSION

HOCM is a heterogeneous disease, in which the aortic outflow tract is obstructed by an abnormally thickened ventricular septum. Since Morrow introduced transaortic myectomy for the treatment of HOCM, which has a complicated pathophysiology, resection-plication-release repair has become the standard treatment [1]. Due to the challenge of septal visualization using the transmitral approach, septal myectomy for left ventricular outflow tract obstruction relief is usually performed via a transaortic valve approach. In addition, improved resolution of SAM via the transaortic valve approach has decreased the occurrence of mitral regurgitation due to loss of coaptation with the posterior leaflet. However, the transmitral approach decreases the risk of aortotomy and aortic valve damage and speeds up postoperative recovery. Moreover, in cases of extensive mitral valve pathology, the transmitral approach allows more complex mitral valve repair and mitral valve replacement [2,3]. Furthermore, as in our present case,

mitral regurgitation with redundant AMVL can be sufficiently treated with AMVL incision and repair.

As experience with minimally invasive mitral valve repair has been gained in several centers, minimally invasive trans-mitral septal myectomy through an AMVL incision has become possible via a robotic approach, as first described by Khalpey et al. [4]. In our center, we have successfully treated four cases to date, including the present case, by septal myectomy through a minimally invasive right mini-thoracotomy approach using the Automated Endoscope System for Optimal Positioning (AESOP; Computer Motion Inc., Santa Barbara, CA, USA) in two cases and the Da Vinci system in two cases. The AESOP technology has advantages for the trans-mitral approach but requires a long instrument with a limited view, which makes the performance of this delicate procedure more difficult. In addition to the well-known cosmetic advantages of minimally invasive approaches, the flexible joints and three-dimensional scope of the Da Vinci system allow for insertion inside the left ventricle below the plane of the mitral valve, which enables precise inspection of the sub-mitral apparatus and a better view for determining the amount of septum that should be removed than is obtained using the transaortic approach.

In summary, minimally invasive transmitral septal myectomy is a good surgical option for mitral repair in selected cases as

an alternative to the conventional transaortic approach, because it can provide not only cosmetic advantages but also better visibility of the subvalvular apparatus and easier extension with good results.

CONFLICT OF INTEREST

No potential conflict of interest relevant to this article was reported.

REFERENCES

1. Morrow AG, Reitz BA, Epstein SE, et al. *Operative treatment in hypertrophic subaortic stenosis: techniques, and the results of pre and postoperative assessments in 83 patients.* Circulation 1975;52:88-102.
2. Gutermann H, Pettinari M, van Kerrebroeck C, et al. *Myectomy and mitral repair through the left atrium in hypertrophic obstructive cardiomyopathy: the preferred approach for contemporary surgical candidates?* J Thorac Cardiovasc Surg 2014;147:1833-6.
3. Mohr FW, Seeburger J, Misfeld M. *Keynote Lecture-Transmitral hypertrophic obstructive cardiomyopathy (HOCM) repair.* Ann Cardiothorac Surg 2013;2:729-32.
4. Khalpey Z, Korovin L, Chitwood WR Jr, Poston R. *Robot-assisted septal myectomy for hypertrophic cardiomyopathy with left ventricular outflow tract obstruction.* J Thorac Cardiovasc Surg 2014;147:1708-9.